

EDI Journal

European Journal for Dental Implantologists



TOPIC

Guideline 2023: Short, angulated and reduced-diameter implants

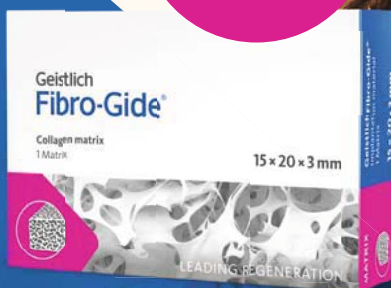

»EDI News: 18th Expert Symposium: The educational highlight of the year · We want YOU! – BDIZ EDI and its multifaceted work »European Law: Ban on advertising medicinal products compatible with Union law »Case Studies: The bone core technique: reconstructing peri-implant bone defects using minimally invasive autologous bone augmentation · Extra-short single-tooth implants rehabilitated using single-tooth trans-epithelial · Screw-retained restoration of upper right first molar and second premolar

What solution would your patient choose?

66.7% of patients prefer Geistlich Fibro-Gide® over connective tissue graft treatment at 6 months.¹

NEW SIZES



Explore our Palate Free solutions.



Impressive performance

Dear colleagues,

After a slimmed-down version two years ago, this year's International Dental Show will be held predominantly face to face this year—as usual in Cologne. From 14 to 18 March 2023, the dental world will flock to the city on the Rhine. The hype of past years, before the COVID-19-pandemic, with ever more visitors and ever more exhibitors, has given way to a new philosophy that the pandemic has taught us; many things actually can be done virtually. This year's IDS is celebrating an anniversary, its 40th. "The most important platform for the dental world for 100 years", is how the IDS organisers describe it in their own press release. Their expectations are emblazoned on the IDS/Koelnmesse website: 2,000 exhibitors from 65 countries, 160,000 trade visitors from 160 countries.

BDIZ EDI will—of course!—be right on the spot again: Hall 11.2, Booth O069—the same place as from 2013 to 2019. Our preparations are in full swing. And we always have something new to offer! The updated 2023 Guideline on short, angulated and reduced-diameter implants will be ready just in time for IDS. Just a few weeks earlier, the 18th Expert Symposium on the same topic was held with internationally renowned speakers—also in Cologne, as tradition dictates.


The European Consensus Conference (EuCC), under the leadership of BDIZ EDI, discussed and revised the content of the document with an international team of experts. The 2023 Guideline will again be available in German and in English.

For a number of years now, we have been at the forefront when it comes to highlighting the impact of the EU Medical Device Regulation (MDR) on our practices. In this issue, we have some new information on this subject. However, the news is not always satisfactory for the dental practices or for medium-sized medical device manufacturers. It is true that the certification requirement has been postponed, but this "solution" is merely a drop in the ocean. Our website provides important MDR-related forms and consistently updated information—as does this issue of the *EDI Journal*.

You can find out more at the BDIZ EDI booth and through our media channels. Come and visit us. You are most welcome!

I look forward to seeing you.

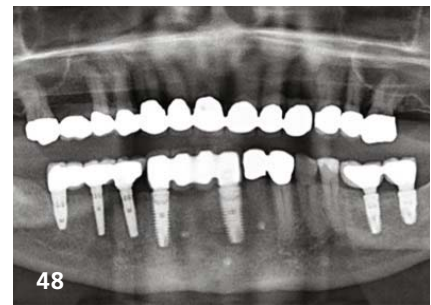
Christian Berger, President BDIZ EDI



BDIZ EDI and its multifaceted work at IDS 2023



MDR: Deadline extension a drop in the ocean



The bone core technique: reconstructing peri-implant bone defects using minimally invasive autologous bone augmentation

EDI News

- 08 Seminar offers**
BDIZ EDI will provide online lectures in 2023
- 10 The educational highlight of the year**
18th Expert Symposium in Cologne, Germany
- 12 A reliable treatment option**
EuCC presents recommendations for short, angulated and reduced-diameter implants
- 22 Are you certified yet?**
"Focus of Professional Activities: Oral Implantology"
- 24 Top priority: dental documentation**
BDIZ EDI checklists still in demand
- 26 Meeting Point Implantology 2023**
BDIZ EDI shows its colours at the 40th IDS in Cologne
- 28 Implant maintenance is a team effort**
Implant care instructions brochure for patients
- 30 Recommendations for practitioners and patients**
BDIZ EDI Quality Guideline for Implantology
- 32 We want YOU!**
BDIZ EDI and its multifaceted work
- 33 BDIZ EDI on social media**
Instagram, Facebook, Twitter, YouTube
- 34 Dental News**
A brief look on dental issues in European/international newspapers
- 36 Qualification for experienced implantologists**
Certification as an EDA Expert in Implantology
- 38 Europe Ticker**
- 40 Ban on advertising medicinal products compatible with Union law**
Judgement of the European Court of Justice in Case C-530/20 | EUROAPTIEKA
- 42 Implantology and modern dentistry**
16th European Symposium of BDIZ EDI and Giornate Veronesi
- 43 Did you ever know...**
Facts about the BDIZ EDI
- 44 Mitigate the risk of shortages**
European Commission adopted proposal to extend transition period of MDR

- 46 MDR: Deadline extension a drop in the ocean**
Extended transition period for the EU Medical Device Regulation does not help

Case Studies

- 48 Reconstructing peri-implant bone defects using minimally invasive autologous bone augmentation**
- 54 Extra-short single-tooth implants rehabilitated using single-tooth transepithelial with a crown-to-implant ratio 2**
- 58 Screw-retained restoration of upper right first molar and second premolar**

Business & Events

- 61 Implant Solutions World Summit 2023—cutting-edge implant science and innovation**
Dentsply Sirona
- 62 The expert meeting for oral tissue regeneration**
International Osteology Symposium Barcelona 2023
- 63 Digital dentistry trends: OSSTEM World Meeting in Istanbul**
OSSTEM IMPLANT
All about the patient: The ITI World Symposium 2024
ITI International Team for Implantology
- 64 Quo vadis Implant Dentistry—The future of dental implantology**
Oral Reconstruction Global Symposium 2023
- 66 New chapter as a scientific community**
OSSTEM IMPLANT
- 68 25 years of the All-on-4® treatment concept**
Nobel Biocare

News and Views

- 03 Editorial**
- 06 Partner Organizations of BDIZ EDI**
- 07 Scientific Board/Imprint**
- 69 Product Reports/Product Studies/Product News**
- 82 Calendar of Events/Publisher's Corner**



NovoMatrix™ Reconstructive Tissue Matrix – the next generation material

NovoMatrix™ Reconstructive Tissue Matrix is an acellular dermal matrix derived from porcine tissue intended for soft tissue applications. The proprietary LifeCell™ tissue processing is designed to maintain the biomechanical integrity of the tissue, which is critical to support tissue regeneration.

Indications

- Localized gingival augmentation to increase keratinized tissue (KT) around teeth and implants
- Alveolar ridge reconstruction for prosthetic treatment
- Guided tissue regeneration procedures in recession defects for root coverage

Product features

- Consistent thickness (1 mm)
- Pre-hydrated
- Controlled source

www.biohorizonscamlog.com

Before use, physicians should review all risk information, which can be found in the Instructions for Use attached to the packaging of each NovoMatrix™ Reconstructive Tissue Matrix graft. NovoMatrix™ is a trademark of LifeCell™ Corporation, an Allergan affiliate. ©BioHorizons. All rights reserved. Not all products are available in all countries.

Partner Organizations of BDIZ EDI



Association of Dental Implantology UK (ADI UK)

ADI UK, founded in 1987, is a registered charity committed to improving the standards of implant dentistry by providing continuing education and ensuring scientific research. It is a membership-focused organisation dedicated to providing the dental profession with continuing education, and the public with a greater understanding of the benefits of dental implant treatment. Membership of the ADI is open to the whole dental team and industry, and offers a wealth of benefits, education and support for anyone wishing to start out or develop further in the field of dental implantology.



Ogólnopolskie Stowarzyszenie Implantologii Stomatologicznej (OSIS EDI)

OSIS EDI, founded in 1992, is a university-based organisation of Polish scientific implantological associations that joined forces to form OSIS. The mission of OSIS EDI is to increase implant patients' comfort and quality of life by promoting the state-of-the-art and high standards of treatment among dental professionals. OSIS EDI offers a postgraduate education in dental implantology leading to receiving a Certificate of Skills (Certykat Umiejetnosci OSIS), which over 130 dental implantologists have already been awarded.



Sociedad Española de Implantes (SEI)

SEI is the oldest society for oral implantology in Europe. The pioneer work started in 1959 with great expectations. The concept of the founding fathers had been a bold one at the time, although a preliminary form of implantology had existed both in Spain and Italy for some time. Today, what was started by those visionaries has become a centrepiece of dentistry in Spain. SEI is the society of reference for all those who practice implantology in Spain and has been throughout the 50 years, during which the practice has been promoted and defended whereas many other societies had jumped on the bandwagon. In 2009 SEI celebrated its 50th anniversary and the board is still emphasizing the importance of cooperating with other recognised and renowned professional societies and associations throughout Europe.



Sociedade Portuguesa de Cirurgia Oral (SPCO)

SOCIEDADE PORTUGUESA DE CIRURGIA ORAL

The SPCO's first international activity was the foundation—together with their counterparts in France, Italy, Spain and Germany—of the European Federation of Oral Surgery (EFOOS) in 1999. The Sociedade Portuguesa de Cirurgia Oral's primary objective is the promotion of medical knowledge in the field of oral surgery and the training of its members.



Udruženje Stomatologa Implantologa Srbije-EDI (USSI EDI)

USSI EDI was founded in 2010 with the desire to enhance dentists' knowledge of dental implants, as well as to provide the highest quality of continuing education in dentistry. The most important aims of the organisation are to make postgraduate studies meeting the standards of the European Union available to dentists from Serbia and the region; to raise the level of education in the field of oral implantology; to develop forensic practice in implantology; and to cooperate with countries in the region striving to achieve similar goals.

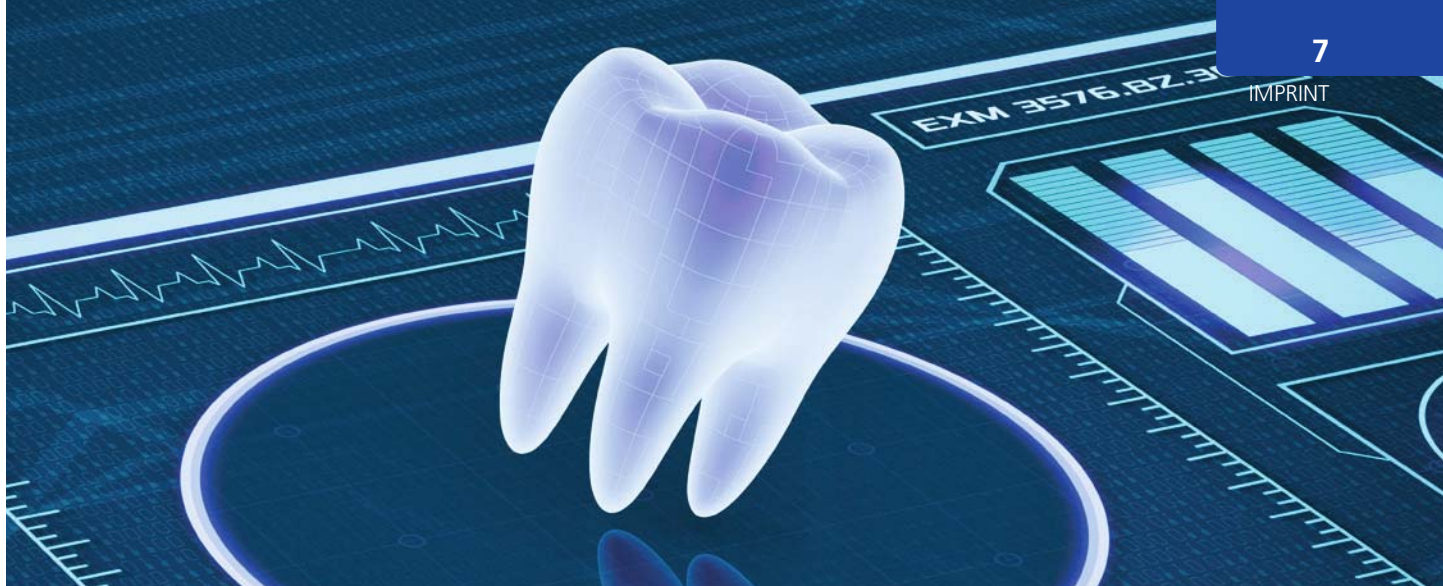


EDI of Macedonia

The Association is Albanian Implantology Association of Macedonia—AIAM was founded in 2013 as a branch of Albanian Dental Society of Macedonia. The association was created to advance education in the field of dental implantology for the benefit of the population. The objectives of the association are:

- To promote the progress of education, research and development of dental implantology in Macedonia
- To encourage postgraduate education, study and research in dental implantology through:
 - Appointment of meetings, lectures, seminars and courses either individually or with others
 - Encouraging the publication of dental implantology articles!
 - To cooperate and make agreements with relevant, national, local, foreign and different institutions.

In 2017, AIAM & MAOS (Macedonian Association of Oral Surgeons) became EDI of Macedonia and signed a Cooperation Agreement with BDIZ EDI to cooperate in dental implantology!



Scientific Board

 Dr Iyad Abou-Rabii, Coventry	 Dr Maher Almasri, Coventry	 Professor Alberico Benedicenti, Genoa	 Dr Eduardo Anitua, Vitoria-Gasteiz	 Dr Marco Degidi, Bologna	 Dr Eric van Dooren, Antwerp	 Professor Rolf Ewers, Vienna
 Professor Antonio Felino, Porto	 Professor Jens Fischer, Basel	 Dr Roland Glauser, Zurich	 Professor Ingrid Grunert, Innsbruck	 Dr Detlef Hildebrand, Berlin	 Dr Axel Kirsch, Filderstadt	 Professor Ulrich Lotzmann, Marburg
 Professor Edward Lynch, Coventry	 Dr Konrad Meyenberg, Zurich	 Professor Georg Nentwig, Frankfurt	 Professor Jörg Neugebauer, Landsberg a. Lech	 Professor Hakan Özyuvaci, Istanbul	 Professor Georgios Romanos, Stony Brook	 Luc Rutten, MDT, Tessenderlo
 Patrick Rutten, MDT, Tessenderlo	 Dr Henry Salama, Atlanta	 Dr Maurice Salama, Atlanta	 Dr Ashok Sethi, London	 Professor Joachim E Zöller, Cologne		

All case reports and scientific documentations are peer reviewed by the international editorial board of EDI Journal.

Chair is Professor Jörg Neugebauer.

Imprint

Association: The European Journal for Dental Implantologists (EDI) is published in cooperation with BDIZ EDI.

Publisher Board Members: Christian Berger, Professor Joachim E. Zöller, Professor Jörg Neugebauer, Professor Thomas Ratajczak

Editor-in-Chief (responsible according to the press law): Anita Wuttke, Phone: +49 89 72069-888, wuttke@bdizedi.org

Advertising Management: OEMUS MEDIA AG, Stefan Thieme, Phone: +49 341 48474-224, s.thieme@oemus-media.de

Publisher: OEMUS MEDIA AG, Holbeinstraße 29, 04229 Leipzig, Germany
Phone: +49 341 48474-224, Fax: +49 341 48474-290
s.thieme@oemus-media.de, www.oemus.com

Managing Director: Ingolf Döbbecke, Lutz V. Hiller

Subscription: OEMUS MEDIA AG, Melanie Herrmann, Phone: +49 341 48474-200, m.herrmann@oemus-media.de

Translation: Per N. Döhler, Triacom Dental

Layout: Dipl.-Des. (FH) Alexander Jahn, Lisa Greulich

Printing: Silber Druck oHG, Otto-Hahn-Straße 25, 34253 Lohfelden, Germany

Publication Dates: March, June, September, December

Subscription Rates: Annual subscription: Germany €40 including shipping and VAT. All other countries €58 including shipping. Subscription payments must be made in advance. Ordering: in written form only to the publisher. Cancellation deadlines: in written form only, eight weeks prior to end of subscription year. Subscription is governed by German law. Past issues are available. Complaints regarding non receipt of issues will be accepted up to three months after date of publication. Current advertising rate list of 1/1/2022. ISSN 1862-2879

Copyright and Publishing Rights: All rights reserved. The magazine and all articles and illustrations therein are protected by copyright. Any utilisation without the prior consent of editor and publisher is inadmissible and liable to prosecution. No part of this publication may be produced or transmitted in any form or by any means, electronic or mechanical including by photocopy, recording, or information storage and retrieval system without permission in writing from the publisher. With acceptance of manuscripts the publisher has the right to publish, translate, permit reproduction, electronically store in databases, produce reprints, photocopies and microcopies. No responsibility shall be taken for unsolicited books and manuscripts. Articles bearing symbols other than of the editorial department or which are distinguished by the name of the authors represent the opinion of the afore-mentioned, and do not have to comply with the views of BDIZ EDI or OEMUS MEDIA AG. Responsibility for such articles shall be borne by the author. All information, results etc. contained in this publication are produced by the authors with best intentions and are carefully checked by the authors and the publisher. All cases of liability arising from inaccurate or faulty information are excluded. Responsibility for advertisements and other specially labeled items shall not be borne by the editorial department.

Copyright: OEMUS MEDIA AG · Place of jurisdiction: Leipzig



BDIZ EDI: Update Implantology 2023

BDIZ EDI will provide
online lectures in 2023

Seminar offers

There is a great demand for information on advanced dental topics in continuing professional development. European and international members and other interested parties can choose from several BDIZ EDI online seminars. For members of associated partner organisation, the seminars are free of charge. Just tick the topic you would like to be presented online.

Send your selection either to the Editorial office at office-munich@bdizedi.org or by fax to +49 89 72069889

- Topic 1: Update on peri-implantitis; Guideline of the European Consensus Conference in 2020**
Presenter: Professor Jörg Neugebauer (Landsberg/Germany), Secretary General of BDIZ EDI, 7–8 p.m.
 About this seminar: Biological complications cannot be avoided completely; they occur at different times following the delivery of the implant restoration. The etiology of these complications is diverse as the way in which they manifest themselves. This issue has been addressed three times before by the European Consensus Conference under the auspices of BDIZ EDI; this panel of experts has re-evaluated the current literature and updated the recommendations of the Guideline. Prof. Neugebauer will present the most recent findings from the literature with numerous clinical examples to ensure the best possible care for patients with peri-implantitis, with a view to avoiding implant loss and eliminating risk factors.
- Topic 2: Update on bone augmentation surgery**
Presenter: Dr Dr Markus Tröltzsch (Ansbach/Germany), Member of the BDIZ EDI Board, 7–8 p.m.
 About this seminar: For implantological restorations to achieve long-term stability, both hard and soft tissues must be available in sufficient quantity and quality. There are many ways in which this can be achieved or maintained. In this online seminar, Dr Tröltzsch, who was in charge of the new DGI/DGZMK-Guideline on implantological indications for the use of bone replacement materials, will highlight the various “minor” and “major” techniques. One of the topics Dr Tröltzsch will discuss how tissue volume can be (re)built or maintained and which of the relevant techniques are suitable for practitioners with different types of practices and different levels of experience.
- Topic 3: Update on short, angulated and diameter-reduced implants—**
Guideline of the European Consensus Conference to be updated in 2023
Presenter: Prof. Jörg Neugebauer (Landsberg/Germany), Secretary General of BDIZ EDI, 7–8 p.m.
 About this seminar: “The use of short, angulated or diameter-reduced implants in case of reduced bone availability represents today—if the specific treatment parameters are taken into account—a reliable therapy option compared to the risks associated with the use of implants with standard dimensions in combination with augmentative procedures.” The conclusion the BDIZ EDI Practice Guide 2023 will be put to the test in this lecture.

Please contact me via e-mail at:

www.bdizedi.org/seminare

EXCELLENCE IN IMMEDIACY

Straumann® TLX Implant System Iconic Tissue Level meets Immediacy.



DESIGNED FOR IMMEDIATE PROTOCOLS

Fully tapered implant design for optimized primary stability.



PERI-IMPLANT HEALTH PRESERVATION

Reduced risk of nesting bacteria and optimized cleansability.



SIMPLICITY AND EFFICIENCY

One-stage process with restoration at soft-tissue level allows to use chair time more efficiently.

The design of the Straumann® TLX Implant takes into account key biological principles of hard and soft tissue healing. It is designed to significantly reduce the risk of inflammation and bone resorption as the implant-abutment interface is moved away from the bone.

Contact your local Straumann representative now or visit www.straumann.com/tlx

References on www.straumann.com/tlx

A0025/en/A/00 05/21



The Vice President of BDIZ, Prof. Joachim Zöller (on the right), as the President of the "Grosse von 1823", was the host of the big Sunday session at the Gürzenich during the carnival season in Cologne.



The dream team at BDIZ EDI consists of Dr Wolfgang Neumann, Helga Karanikas, and Christian Berger (from left to right).



The BDIZ EDI board members at the Gürzenich, enjoying a lively atmosphere after a day of intensive training.

18th Expert Symposium in Cologne, Germany

The educational highlight of the year

After 2011 and 2016, BDIZ EDI once again examined the status of short, angled and reduced-diameter implants at the 18th Expert Symposium. Controversial expert discussions met with a highly motivated professional audience.

In view of the ongoing developments in this field, the European Consensus Conference under the auspices of BDIZ EDI also revised the recommendations of its previous Guideline. The new BDIZ EDI Guideline provides recommendations on short, angulated and reduced-diameter implants, replacing the previous 2016 version. The result, the 2023 Guideline, is presented in this issue.

The scientific direction of the event was in the proven hands of Prof. Joachim E. Zöller, BDIZ EDI Vice President. In his role as President of the Cologne carnival celebrations committee "Grosse von 1823", he celebrated the 200th anniversary of the Cologne Carnival. Symposium participants were treated to an opulent and colourful carnival event at Gürzenich Hall, where the "Grosse von 1823" held its last Sunday meeting of the carnival season.

Look out for more details on topics and speakers during the 18th Expert Symposium in Cologne, Germany in the next issue of *EDI Journal*!



These four gentlemen are waiting for the start of the European Committee.



The 31st European Committee of BDIZ EDI was held in a small group this year, with attendees including Anita Wuttke, Prof. Vitomir Konstantinovic from Serbia, Christian Berger, Prof. Antonio Felino from Portugal, Dr Fisnik Kasapi from Macedonia, Prof. Hakan Özyuvaci from Turkey, and Dr Markus Tröltzsch (from left).



The panel of speakers consisting of moderator Prof. H.J. Nickenig, Prof. Friedhelm Heinemann, moderator Christian Berger, BZÄK President Prof. Christoph Benz (who was in attendance as a guest), Dr Markus Tröltzsch, and Dr Alexandros Manolakis (from left).



Dr Eduardo Anitua (in the middle), known as “the Pope of short implants” from Spain, together with moderators Prof. H.J. Nickenig (left) and Christian Berger (right).



Late in the afternoon, Dr Ingo Frank gave a lecture on fixed teeth in one day.



Highly motivated professional audience at the 18th Expert Symposium in Cologne.



EuCC presents recommendations for short, angulated and reduced-diameter implants

A reliable treatment option

In January and February, the 18th European Consensus Conference (EuCC) under the auspices of BDIZ EDI updated its 2016 Guideline on short, angulated and reduced-diameter implants. The 2023 Guideline provides recommendations for practitioners and reflects data from controlled clinical trials while also incorporating data from routine clinical practice.

Prof. Jörg Neugebauer, BDIZ EDI Secretary General and host of the EuCC, explains why this revised version has been prepared: "Discussions on this topic do not take place in a closed forum. We are not aiming for a purely academic environment. Rather, our recommendations should provide practical guidance for practising dentists, while also incorporating expertise from across Europe."

Short implants

This second update has left the definition of "short" unchanged. As before, they have a designed intrabony length of ≤ 8 mm with a diameter of ≥ 3.75 mm. They are used, among other things, to avoid bone grafting in the posterior jaw segments of partially edentulous patients, but also to support removable overdentures and as single or multiple tooth replacements in the anterior jaw. The EuCC

has found that there is no longer any difference in success rates compared with standard implants with augmentation procedures. A new indication is that for immediate loading. There are now studies that support the use of short implants with special treatment concepts in immediate-loading situations.

Angulated implants

There have also been new developments regarding angulated implants, which are becoming routine in splinted reconstructions of edentulous jaws. The EuCC agreed that they increase primary stability for immediate loading procedures

Bibliographical note

Guideline 2023

"Update on short, angulated and reduced-diameter implants"

Prepared by the 18th European Consensus Conference under the auspices of BDIZ EDI in January and February 2023

11 A4 pages + cover, with extensive references

Come to BDIZ EDI stand at IDS: Hall 11.2, aisle O, stand 69 and get your free copy. Additional copies can be ordered from the BDIZ EDI online store at www.bdizedi.org (€3.50 incl. VAT, plus S + H)



are significantly lower, but patients will still benefit in terms of oral health-related quality of life. Mini implants also show favourable results when used to increase the number of restorative abutments for removable partial dentures. According to the EuCC, short mini implants should still be avoided.

less risky therapeutic option in terms of specific treatment parameters, compared with the risks associated with the use of standard-dimension implants in combination with augmentation procedures.

AWU

Recommendation

The use of short, angulated or reduced-diameter implants in sites with reduced bone volume can be a reliable, faster and

with longer implants, avoiding bone grafting. These treatment concepts require 4 implants in the mandible and 4 to 6 implants in the maxilla. However, current observations have also revealed limitations. "Despite the positive clinical results, the scientific debate on the clinical relevance of the development of marginal bone levels around angulated implants is still ongoing", as Neugebauer summarised the consensus finding.

Reduced-diameter implants

The EuCC distinguishes between two general settings. Reduced-diameter implants—those with intraosseous diameters of < 3.5 mm—are indicated for use in jaws with reduced widths. EuCC refers to implants with diameters of < 2.7 mm as mini implants. There is no change from to the previous 2016 Guideline. New meta-analyses support the statements made at that time.

Reduced-diameter implants have high survival rates (> 90%) with careful patient selection, bone density assessment, clinical approach, and user experience. They can also be used in the posterior region with high success rates.

There are differences in the success rates of mini implants in the maxilla and mandible. While mini implants in the mandible that are restored with an overdenture have excellent short- to medium-term survival rates, survival rates in the maxilla



Guideline 2023

2nd Update on short, angulated and reduced-diameter implants

18th European Consensus Conference (EuCC) 2023

6 February 2023

Authors: Jörg Neugebauer, PhD, DMD
Joachim E. Zöller, PhD, MD, DMD
Department of Craniomaxillofacial and Plastic Surgery
and Interdisciplinary Department for Oral Surgery and Implantology
Centre for Dentistry and Oral and Maxillofacial Surgery,
University of Cologne, Germany

Host: Professor J. Neugebauer (Germany)
Protocol: Professor J. Neugebauer (Germany)

Participants: Professor B. Al-Nawas (Germany)
C. Berger (Germany)
Dr E. O'Connell (United Kingdom)
Professor A. Felino (Portugal)
Dr I. Frank (Germany)
Professor F. Heinemann (Germany)
Dr F. Kasapi (Macedonia)
Dr K. Krasny (Poland)
Professor V. Konstantinović (Serbia)
Dr S. Liepe (Germany)
Dr A. Manolakis (Greece)
Professor J. Neugebauer (Germany)
Dr W. Neumann (Germany)
Professor H. Özyuvacı (Turkey)
Dr B. Singh (Nepal)
W. Tomkiewicz (Poland)
Dr J.W. Vaartjes (The Netherlands)
Professor J.E. Zöller (Germany)

Content

1	Methods	Page 2
2	Problem	Page 3
3	Use of short implants	Page 3
4	Use of angulated implants	Page 4
5	Use of reduced-diameter implants	Page 5
6	Recommendations	Page 5
7	References	Page 6

Bundesverband der
implantologisch
tätigen Zahnärzte
in Europa

European
Association of
Dental
Implantologists

BDIZ EDI
Lipowskystr. 12
D-81373 Munich
GERMANY

Fon: +49-89-720 69 888
Fax: +49-89-720 69 889
office@bdizedi.org
www.bdizedi.org



1 Methods

1.1 Objective

The purpose of this guideline is to provide clinicians involved in implant dentistry with recommendations to enable them to correctly assess the potential indications (and any limitations) for short, angulated or reduced-diameter implants. This guideline reflects data from controlled clinical trials and takes into account clinical data from routine treatment in the private-practice setting.

1.2 Introduction

This consensus paper is concerned only with titanium implants, typically placed according to the indications recommended by the European Consensus Conference Implantology (EuCC, Germany, 6 February 2023).

All consensus recommendations in this paper should be considered as guidelines only. The specific situation of the patient is always an important consideration and may justify a deviation from the recommendations of this consensus paper.

1.3 Background

Avoiding bone augmentation with reduced-dimension implants and making optimal use of the available bone volume are often recommended as minimally invasive treatment options [50]. In addition to the number of implants, dimension and insertion type must be considered to ensure an acceptable treatment outcome.

1.4 Literature search

The Cochrane Library, EMBASE, DIMDI and Medline literature databases were used to conduct a systematic search for recently published data on the use of short, angled and reduced-diameter implants. Selective search criteria were used, including terms such as short implants, angulated implants, angled implants, tilted implants and implant failure, narrow and reduced diameter. The publications identified by the search were screened by reading their abstracts, and those irrelevant to the topic were identified and excluded. Those articles identified as potentially relevant were obtained in full text. Several meta-analysis reviews and randomized controlled trials (RCTs) and other prospective or retrospective systematic clinical trials were available on the topic.

1.5 Development of this guideline/consensus paper

A preliminary version, on which the EuCC based its deliberations, was prepared and reviewed by Professor J. Neugebauer of the Interdisciplinary Policlinic for Oral Surgery and Implantology and the Department of Oral and Maxillofacial Plastic Surgery at the University of Cologne, Germany. The preliminary report was then reviewed and discussed by the members of the committee in the following five steps:

- Review of the preliminary draft
- Collecting alternative suggestions
- Voting on recommendations and levels of recommendation
- Discussion of non-consensual issues
- Final vote

BDIZ EDI
Lipowskystr. 12
D-81373 Munich
GERMANY

Fon: +49-89-720 69 888
Fax: +49-89-720 69 889
office@bdizedi.org
www.bdizedi.org



2 Problem

The use of standard implants in patients with alveolar ridge atrophy or extensive pneumatization of the maxillary sinus cavity often requires the use of hard-tissue augmentation procedures [18, 19]. These procedures are well established, and widely used with success. However, depending on the operator's level of training and the patient-specific risk factors complications may occur, or the postoperative quality of life may be compromised [2, 10, 17-19, 34].

3 Use of short implants

3.1 Introduction

Short implants are increasingly being discussed as a treatment alternative in situations characterized by limited vertical bone height [5].

Compared to the use of standard implants due to biomechanical considerations (e.g., crown-to-implant ratio, C/R) with short implants may result in unfavourable loading conditions and complications, including excessive bone loss and implant failure [20]. Improvements in implant design and surface, together with the use of modified implant insertion techniques, are all aimed at minimizing these risks [15].

3.2 Definition of short implants

Implants are commonly referred to as short if their designed intrabony length measures ≤ 8 mm with diameters ≥ 3.75 mm. Standard implants are those with a length > 8 mm with diameters ≥ 3.75 mm [47, 52]. Ultra-short implants are those with lengths < 6 mm [16].

3.3 Indications for short implants

Short implants are primarily used to avoid bone augmentation procedures in the maxillary and mandibular posterior segments of partially edentulous patients. They are used when vertical bone volume is limited by anatomical structures (maxillary sinus, mandibular canal), but there is sufficient alveolar ridge width to allow successful use of implant diameters ≥ 3.75 mm. They are also used for support of removable overdentures as single or multiple tooth replacements in the anterior jaw [25, 52].

3.4 Current observations

Various meta-analyses indicate that there is no difference between the use of short implants in comparison to standard implants with grafting procedures for the marginal bone level development or success rates [8, 9, 24, 25, 37, 39, 56, 62, 66].

Whether there is an advantage to splinting the implants remains unclear [1, 36] [54].

In a limited number of studies, immediate loading has been performed [26, 33, 65]. For immediate loading short implants may be used, but care must be taken to follow specific treatment concepts.

However, the literature shows, that short implants with reduced diameter have a failure rate of up to 10% after 3–5 years [13].

BDIZ EDI
Lipowskystr. 12
D-81373 Munich
GERMANY

Fon: +49-89-720 69 888
Fax: +49-89-720 69 889
office@bdizedi.org
www.bdizedi.org



3.5 Preventing complications

Some authors have made recommendations on how to avoid complications that are mainly biomechanical in nature. These recommendations include:

- Machined-surfaced, short implants should not be used [42].
- Short implants should only be used when bone quality is favourable [13].
- Restoration with single crowns [3, 27, 43, 58].
- Single short implants with cantilevers should not be used [57].
- Guiding surfaces for lateral movement should be avoided [11].
- Regular occlusal checks are recommended [59].
- Placement at or below bone level with tapered abutment design [29, 38].
- The implant surgeon and restorative dentist must have appropriate training [58].

4 Use of angulated implants

4.1 Introduction

Angulated standard implant designs or non-angulated ones placed in off-axis (tilted) positions are becoming routine in splinted reconstructions of edentulous jaws as an alternative treatment option to avoid hard-tissue augmentation procedures, but also to increase primary stability for immediate loading procedures with longer implants [11]. These concepts require 4 implants in the mandible and 4 to 6 implants in the maxilla.

The aim of placing implants in a tilted position is to utilize as much bone as possible, while still avoiding vital adjacent structures (e.g., the mental foramen in the mandible or the maxillary sinus in the maxilla). They also increase the surface area for restorative support (through divergent implant axes) [6]. Restorations can be inserted on these implants using angulated abutments.

Modifications of this concept are also used in partially edentulous patients or with a reduced number of implants. The specific treatment protocol varies and individual recommendations should be followed.

4.2 Current observations

Based on 24 included articles, 2,637 patients which were rehabilitated with 2,735 full prostheses (1,464 maxillary, 1,271 mandibular), supported by 5,594 and 5,611 tilted and axial implants, respectively. The cumulative implant survival rate between the observation of 3 up-to 18 years was 93.91% and 99.31% for implants and prostheses, respectively [14].

Despite the positive clinical results, the scientific discussion on the clinical relevance of marginal bone level development around angled implants is still ongoing [12, 14, 41, 48].

4.3 Restorative experience

The use of a cantilevered, shortened dental arch with a lack of posterior support has not shown an increased prevalence of oromandibular malfunctions [51].

BDIZ EDI
Lipowskystr. 12
D-81373 Munich
GERMANY

Fon: +49-89-720 69 888
Fax: +49-89-720 69 889
office@bdizedi.org
www.bdizedi.org



4.4 Preventing complications

- The use of angulated implants splinted with fixed dental prostheses and subjected to immediate loading should achieve adequate primary stability [41, 49].
- Preoperative 3D computer-assisted diagnosis is recommended for anatomically and prosthetically correct angled implant placement [30].
- The implant surgeon and restorative dentist must have adequate training [60].

5 Use of reduced-diameter implants

5.1 Definition

Reduced-diameter implants can be defined as those with intraosseous diameters < 3.5 and > 2.7 mm for placement in sites with reduced alveolar ridge bone width. Implants with a diameter < 2.7 mm are referred to as "mini"-implants [21].

5.2 Current observations

Reduced-diameter implants generally have high survival rates ($> 90\%$), assuming careful patient selection, bone density assessment, clinical approach, and user experience [28, 32, 55]. Reduced-diameter implants can also be used in the posterior region with high success rates [32]. These findings are supported by recent meta-analyses [23, 53, 61].

Despite the limited number of studies available, fixed dental prostheses supported by reduced-diameter implants showed comparable survival and success rates to those supported by standard-diameter implants, with slightly lower marginal bone loss. No firm conclusions could be drawn for partial removable dental prostheses [7].

Mandibular mini-implants supporting an overdenture exhibit excellent short- to medium-term survival rates and improve patients' chewing and speaking ability, quality of life, and satisfaction [22, 31, 35, 40]. Survival of mini-implants supporting maxillary overdentures has been observed to be lower, but patients will benefit in terms of oral health-related quality of life [35, 53, 63].

Mini-implants also show favourable results as supporting implants for removable partial dentures [4, 45, 46].

5.3 Preventing complications

- Mini-implants have an increased risk of implant loss in the maxilla.
- Short mini-implants should be avoided [64].
- The implant surgeon and restorative dentist must have adequate training

BDIZ EDI
Lipowskystr. 12
D-81373 Munich
GERMANY

Fon: +49-89-720 69 888
Fax: +49-89-720 69 889
office@bdizedi.org
www.bdizedi.org



Guideline: Update on short, angulated and diameter-reduced implants
18th European Consensus Conference (EuCC), February 2023
Page 6 of 10

6 Recommendations for short, angulated and/or reduced-diameter implants

The use of short, angulated or reduced-diameter implants in sites with reduced bone volume can be a reliable, faster and less risky therapeutic option in terms of specific treatment parameters, compared with the risks associated with the use of standard-dimension implants in combination with augmentation procedures. The implant surgeon and the restorative dentist must have appropriate training to select the best possible therapy for each patient [44].

Cologne, 6 February 2023

Professor Dr Dr Joachim Zöller
Vice President

Professor Dr Jörg Neugebauer
Secretary General/Host

BDIZ EDI
Lipowskyst. 12
D-81373 Munich
GERMANY

Fon: +49-89-720 69 888
Fax: +49-89-720 69 889
office@bdizedi.org
www.bdizedi.org



References

1. Afrashtehfar KI, Katsoulis J, Koka S et al. Single versus splinted short implants at sinus augmented sites: A systematic review and meta-analysis. *J Stomatol Oral Maxillofac Surg* 2021; 122: 303-310.
2. Aghaloo TL, Moy PK. Which hard tissue augmentation techniques are the most successful in furnishing bony support for implant placement? *Int J Oral Maxillofac Implants* 2007; 22 Suppl: 49-70.
3. Al-Ansari A. Short implants supporting single crowns in atrophic jaws. *Evid Based Dent* 2014; 15: 85-86.
4. Al Jaghsi A, Heinemann F, Biffar R et al. Immediate versus delayed loading of strategic mini-implants under existing removable partial dentures: patient satisfaction in a multi-center randomized clinical trial. *Clin Oral Investig* 2021; 25: 255-264.
5. Aloy-Prosper A, Penarrocha-Oltra D, Penarrocha-Diago M et al. The outcome of intraoral onlay block bone grafts on alveolar ridge augmentations: a systematic review. *Med Oral Patol Oral Cir Bucal* 2015; 20: e251-258.
6. Aparicio C, Perales P, Rangert B. Tilted implants as an alternative to maxillary sinus grafting: a clinical, radiologic, and periotest study. *Clin Implant Dent Relat Res* 2001; 3: 39-49.
7. Badaro MM, Herdt B, Bezerra AP et al. Narrow-Diameter Implants for Partial Fixed and Removable Prosthesis: A Systematic Review and Meta-Analysis. *Int J Prosthodont* 2022; 35: 738-751.
8. Bitinas D, Bardijevskyt G. Short implants without bone augmentation vs. long implants with bone augmentation: systematic review and meta-analysis. *Aust Dent J* 2021; 66 Suppl 1: S71-S81.
9. Chaware SH, Thakare V, Chaudhary R et al. The rehabilitation of posterior atrophic maxilla by using the graftless option of short implant versus conventional long implant with sinus graft: A systematic review and meta-analysis of randomized controlled clinical trial. *J Indian Prosthodont Soc* 2021; 21: 28-44.
10. Chiapasco M, Casentini P, Zaniiboni M. Bone augmentation procedures in implant dentistry. *Int J Oral Maxillofac Implants* 2009; 24 Suppl: 237-259.
11. Chrcanovic BR, Albrektsson T, Wennerberg A. Tilted versus axially placed dental implants: a meta-analysis. *J Dent* 2015; 43: 149-170.
12. Cortes-Breton Brinkmann J, Garcia-Gil I, Pedregal P et al. Long-Term Clinical Behavior and Complications of Intentionally Tilted Dental Implants Compared with Straight Implants Supporting Fixed Restorations: A Systematic Review and Meta-Analysis. *Biology (Basel)* 2021; 10.
13. das Neves FD, Fones D, Bernardes SR et al. Short implants--an analysis of longitudinal studies. *Int J Oral Maxillofac Implants* 2006; 21: 86-93.
14. Del Fabbro M, Pozzi A, Romeo D et al. Outcomes of Fixed Full-Arch Rehabilitations Supported by Tilted and Axially Placed Implants: A Systematic Review and Meta-Analysis. *Int J Oral Maxillofac Implants* 2022; 37: 1003-1025.
15. Deporter D. Short dental implants: what works and what doesn't? A literature interpretation. *Int J Periodontics Restorative Dent* 2013; 33: 457-464.
16. Deporter D, Ogiso B, Sohn DS et al. Ultrashort sintered porous-surfaced dental implants used to replace posterior teeth. *J Periodontol* 2008; 79: 1280-1286.
17. Esposito M, Felice P, Worthington HV. Interventions for replacing missing teeth: augmentation procedures of the maxillary sinus. *Cochrane Database Syst Rev* 2014; 5: CD008397.
18. Esposito M, Grusovin MG, Kwan S et al. Interventions for replacing missing teeth: bone augmentation techniques for dental implant treatment. *Cochrane Database Syst Rev* 2008; CD003607.
19. Esposito M, Grusovin MG, Worthington HV et al. Interventions for replacing missing teeth: bone augmentation techniques for dental implant treatment. *Cochrane Database Syst Rev* 2006; CD003607.
20. Garaicoa-Pazmino C, Suarez-Lopez del Amo F, Monje A et al. Influence of crown/implant ratio on marginal bone loss: a systematic review. *J Periodontol* 2014; 85: 1214-1221.
21. Gleiznys A, Skirbutis G, Harb A et al. New approach towards mini dental implants and small-diameter implants: an option for long-term prostheses. *Stomatologija* 2012; 14: 39-45.
22. Goiato MC, Sonogo MV, Pellizzer EP et al. Clinical outcome of removable prostheses supported by mini dental implants. A systematic review. *Acta Odontol Scand* 2018; 76: 628-637.

BDIZ EDI
Lipowskystr. 12
D-81373 Munich
GERMANY

Fon: +49-89-720 69 888
Fax: +49-89-720 69 889
office@bdizedi.org
www.bdizedi.org



23. Gonzalez-Valls G, Roca-Millan E, Cespedes-Sanchez JM et al. Narrow Diameter Dental Implants as an Alternative Treatment for Atrophic Alveolar Ridges. Systematic Review and Meta-Analysis. *Materials (Basel)* 2021; 14.
24. Grunau O, Terheyden H. Lateral augmentation of the sinus floor followed by regular implants versus short implants in the vertically deficient posterior maxilla: a systematic review and timewise meta-analysis of randomized studies. *Int J Oral Maxillofac Surg* 2022.
25. Guida L, Bressan E, Cecoro G et al. Short versus Longer Implants in Sites without the Need for Bone Augmentation: A Systematic Review and Meta-Analysis of Randomized Controlled Trials. *Materials (Basel)* 2022; 15.
26. Hadilou M, Ebrahimi P, Karimzadeh B et al. Immediate loading of short implants: A systematic review. *J Adv Periodontol Implant Dent* 2021; 13: 15-21.
27. Hasan I, Bourauel C, Mundt T et al. Biomechanics and load resistance of short dental implants: a review of the literature. *ISRN Dent* 2013; 2013: 424592.
28. Hasan I, Bourauel C, Mundt T et al. Biomechanics and load resistance of small-diameter and mini dental implants: a review of literature. *Biomed Tech (Berl)* 2014; 59: 1-5.
29. Hentschel A, Herrmann J, Glauche I et al. Survival and patient satisfaction of short implants during the first 2 years of function: a retrospective cohort study with 694 implants in 416 patients. *Clin Oral Implants Res* 2016; 27: 591-596.
30. Jacobs R, Salmon B, Codari M et al. Cone beam computed tomography in implant dentistry: recommendations for clinical use. *BMC Oral Health* 2018; 18: 88.
31. Jawad S, Clarke PT. Survival of Mini Dental Implants Used to Retain Mandibular Complete Overdentures: Systematic Review. *Int J Oral Maxillofac Implants* 2019; 34: 343-356.
32. Klein MO, Schiegnitz E, Al-Nawas B. Systematic review on success of narrow-diameter dental implants. *Int J Oral Maxillofac Implants* 2014; 29 Suppl: 43-54.
33. Kulkarni V, Uttamani JR, Asar NV et al. Evidence-Based Clinical Outcomes of Immediate and Early Loading of Short Endosseous Dental Implants: A Meta-analysis. *Int J Oral Maxillofac Implants* 2021; 36: 59-67.
34. Lee SA, Lee CT, Fu MM et al. Systematic review and meta-analysis of randomized controlled trials for the management of limited vertical height in the posterior region: short implants (5 to 8 mm) vs longer implants (> 8 mm) in vertically augmented sites. *Int J Oral Maxillofac Implants* 2014; 29: 1085-1097.
35. Lemos CA, Verri FR, Batista VE et al. Complete overdentures retained by mini implants: A systematic review. *J Dent* 2017; 57: 4-13.
36. Li QL, Yao MF, Cao RY et al. Survival Rates of Splinted and Nonsplinted Prostheses Supported by Short Dental Implants (≤ 8.5 mm): A Systematic Review and Meta-Analysis. *J Prosthodont* 2022; 31: 9-21.
37. Lin ZZ, Jiao YQ, Ye ZY et al. The survival rate of transcresal sinus floor elevation combined with short implants: a systematic review and meta-analysis of observational studies. *Int J Implant Dent* 2021; 7: 41.
38. Lombardo G, Corrocher G, Pighi J et al. The impact of subcrestal placement on short locking-taper implants placed in posterior maxilla and mandible: a retrospective evaluation on hard and soft tissues stability after 2 years of loading. *Minerva Stomatol* 2014; 63: 391-402.
39. Lozano-Carrascal N, Anglada-Bosqued A, Salomo-Coll O et al. Short implants (<8mm) versus longer implants (≥ 8 mm) with lateral sinus floor augmentation in posterior atrophic maxilla: A meta-analysis of RCT;s in humans. *Med Oral Patol Oral Cir Bucal* 2020; 25: e168-e179.
40. Marcello-Machado RM, Faot F, Schuster AJ et al. Mini-implants and narrow diameter implants as mandibular overdenture retainers: A systematic review and meta-analysis of clinical and radiographic outcomes. *J Oral Rehabil* 2018; 45: 161-183.
41. Mehta SP, Sutariya PV, Pathan MR et al. Clinical success between tilted and axial implants in edentulous maxilla: A systematic review and meta-analysis. *J Indian Prosthodont Soc* 2021; 21: 217-228.
42. Menchero-Cantalejo E, Barona-Dorado C, Cantero-Alvarez M et al. Meta-analysis on the survival of short implants. *Med Oral Patol Oral Cir Bucal* 2011; 16: e546-551.
43. Mezzomo LA, Miller R, Triches D et al. Meta-analysis of single crowns supported by short (<10 mm) implants in the posterior region. *J Clin Periodontol* 2014; 41: 191-213.
44. Monteiro DR, Silva EV, Pellizzer EP et al. Posterior partially edentulous jaws, planning a rehabilitation with dental implants. *World J Clin Cases* 2015; 3: 65-76.

BDIZ EDI
Lipowskystr. 12
D-81373 Munich
GERMANY

Fon: +49-89-720 69 888
Fax: +49-89-720 69 889
office@bdizedi.org
www.bdizedi.org



Guideline: Update on short, angulated and diameter-reduced implants
18th European Consensus Conference (EuCC), February 2023
Page 9 of 10

45. Mundt T, Al Jaghsi A, Schwahn B et al. Immediate versus delayed loading of strategic mini dental implants for the stabilization of partial removable dental prostheses: a patient cluster randomized, parallel-group 3-year trial. *BMC Oral Health* 2016; 17: 30.
46. Mundt T, Schwahn C, Heinemann F et al. Stabilizing Removable Partial Dentures by Immediate or Delayed Loading of Mini-implants: Chewing Efficiency in a Randomized Controlled Clinical Trial. *Int J Oral Maxillofac Implants* 2020; 35: 178-186.
47. Olate S, Lyrio MC, de Moraes M et al. Influence of diameter and length of implant on early dental implant failure. *J Oral Maxillofac Surg* 2010; 68: 414-419.
48. Omori Y, Lang NP, Botticelli D et al. Biological and mechanical complications of angulated abutments connected to fixed dental prostheses: A systematic review with meta-analysis. *J Oral Rehabil* 2020; 47: 101-111.
49. Penarrocha-Diago M, Penarrocha-Diago M, Zaragoza-Alonso R et al. Consensus statements and clinical recommendations on treatment indications, surgical procedures, prosthetic protocols and complications following All-On-4 standard treatment. 9th Mozo-Grau Ticare Conference in Quintanilla, Spain. *J Clin Exp Dent* 2017; 9: e712-e715.
50. Pommer B, Mailath-Pokorny G, Haas R et al. Patients' preferences towards minimally invasive treatment alternatives for implant rehabilitation of edentulous jaws. *Eur J Oral Implantol* 2014; 7 Suppl 2: S91-109.
51. Reissmann DR, Heydecke G, Schierz O et al. The randomized shortened dental arch study: temporomandibular disorder pain. *Clin Oral Investig* 2014; 18: 2159-2169.
52. Renouard F, Nisand D. Impact of implant length and diameter on survival rates. *Clin Oral Implants Res* 2006; 17 Suppl 2: 35-51.
53. Schiegnitz E, Al-Nawas B. Narrow-diameter implants: A systematic review and meta-analysis. *Clin Oral Implants Res* 2018; 29 Suppl 16: 21-40.
54. Shah AH, Patel P, Trivedi A et al. A comparison of marginal bone loss, survival rate, and prosthetic complications in implant-supported splinted and nonsplinted restorations: A systematic review and meta-analysis. *J Indian Prosthodont Soc* 2022; 22: 111-121.
55. Sohrabi K, Mushantat A, Esfandiari S et al. How successful are small-diameter implants? A literature review. *Clin Oral Implants Res* 2012; 23: 515-525.
56. Terheyden H, Meijer GJ, Raghoobar GM. Vertical bone augmentation and regular implants versus short implants in the vertically deficient posterior mandible: a systematic review and meta-analysis of randomized studies. *Int J Oral Maxillofac Surg* 2021; 50: 1249-1258.
57. Thoma DS, Wolleb K, Schellenberg R et al. Two short implants versus one short implant with a cantilever: 5-Year results of a randomized clinical trial. *J Clin Periodontol* 2021; 48: 1480-1490.
58. Thoma DS, Zeltner M, Husler J et al. EAO Supplement Working Group 4 - EAO CC 2015 Short implants versus sinus lifting with longer implants to restore the posterior maxilla: a systematic review. *Clin Oral Implants Res* 2015; 26 Suppl 11: 154-169.
59. Todescan S, Lavigne S, Kelekis-Cholakis A. Guidance for the maintenance care of dental implants: clinical review. *J Can Dent Assoc* 2012; 78: c107.
60. Unsal GS, Turkyilmaz I, Lakhia S. Advantages and limitations of implant surgery with CAD/CAM surgical guides: A literature review. *J Clin Exp Dent* 2020; 12: e409-e417.
61. Valente NA, Marchio V, Troiano G et al. Narrow-diameter versus standard-diameter implants placed in horizontally regenerated bone in the rehabilitation of partially and completely edentulous patients: A systematic review. *Int J Oral Implantol (Berl)* 2022; 15: 11-33.
62. Vetromilla BM, Mazzetti T, Pereira-Cenci T. Short versus standard implants associated with sinus floor elevation: An umbrella review of meta-analyses of multiple outcomes. *J Prosthet Dent* 2021; 126: 503-511.
63. Vi S, Pham D, Du YYM et al. Mini-Implant-Retained Overdentures for the Rehabilitation of Completely Edentulous Maxillae: A Systematic Review and Meta-Analysis. *Int J Environ Res Public Health* 2021; 18.
64. Wang HL, Okayasu K, Fu JH et al. The success rate of narrow body implants used for supporting immediate provisional restorations: a pilot feasibility study. *Implant Dent* 2012; 21: 467-473.
65. Wu H, Shi Q, Huang Y et al. Failure Risk of Short Dental Implants Under Immediate Loading: A Meta-Analysis. *J Prosthodont* 2021; 30: 569-580.
66. Yu X, Xu R, Zhang Z et al. A meta-analysis indicating extra-short implants (≤ 6 mm) as an alternative to longer implants (≥ 8 mm) with bone augmentation. *Sci Rep* 2021; 11: 8152.

BDIZ EDI
Lipowskystr. 12
D-81373 Munich
GERMANY

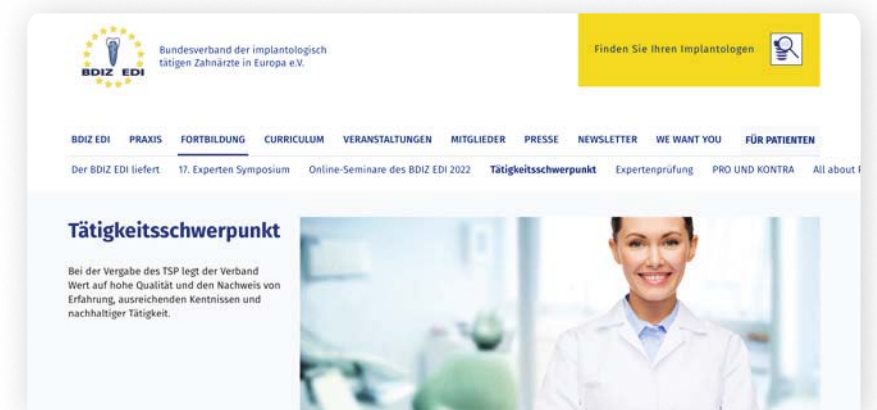Fon: +49-89-720 69 888
Fax: +49-89-720 69 889
office@bdizedi.org
www.bdizedi.org

“Focus of Professional Activities: Oral Implantology”

Are you certified yet?

In Germany, a formal “Focus of Professional Activities” (FPA) is an official designation and an indication of a narrower area of specialisation of a professional—in our case, a dentist. The BDIZ EDI was instrumental in obtaining a ruling from the Federal Constitutional Court in 2001, to establish the “Focus of Professional Activities: Oral Implantology” (Tätigkeitsschwerpunkt Implantologie) as a legally permissible designation on practice nameplates or other information material aimed at the general public. This article outlines the requirements for an FPA: Oral Implantology.

In its decision of 23 July 2001 (1 BvR 873/00 and 1 BvR 874/00), the German Federal Constitutional Court approved the admissibility of a formal FPA: Oral Implantology on constitutional grounds, despite conflicting regulations in dental professional codes. One prerequisite for the admissibility of information describing (specifying) personal professional activities in detail is that the specified activities are carried out in a field of specialisation on a sustained basis.



Requirements for FPA certification

Licensed dentists, oral surgeons and oral and maxillofacial surgeons who meet the following requirements can apply for certification of a Focus of Professional Activities: Oral Implantology by the BDIZ EDI:

1. Certificate of attendance of the Curriculum Implantology
2. Evidence of at least three years' experience in oral implantology
3. Evidence of at least 200 implants (placed and/or restored)
4. and/or 70 patient cases (affidavit, with five to ten sample OPGs)
5. Membership of BDIZ EDI

FPA renewal or recertification

To renew an FPA: Oral Implantology certification, proof of continuing education in accordance with these guidelines must be provided after five years:

- 100 continuing-education hours or equivalent continuing-education credits
- 200 placed implants or 70 cases

Each renewal is granted for a five-year period. Without renewal, the FPA: Oral Implantology certification will lapse.

Register of oral implantologists

BDIZ EDI maintains a register of oral implantologists, which is used to refer patients seeking implant treatment to certified dentists, oral surgeons, or oral and maxillofacial surgeons. (In German-speaking countries and certain other European countries, including the UK, oral surgeons are specialised dentists, while oral and maxillofacial surgeons have degrees in both dentistry and medicine.)

To be included in this central register, the following requirements must be met:

1. Certified dentists or oral and maxillofacial surgeons should have several years of experience (at least three years) with at least two implant systems.
2. They should have placed and/or restored at least 200 implants or completed 70 cases.
3. They should be able to demonstrate that they place at least 50 implants per year.

Additional information

Applications for certification should be made to our Munich office. FPA guidelines and registration forms are available on the BDIZ EDI website at www.bdizedi.org/taetigkeitsschwerpunkt.

There is an administrative fee of €250 for certification, and €80 for inclusion in the central register of implantologists.

EB



tiologic
TWINFIT

platform

conical

IT'S MY CHOICE.

The decision on which abutment is best for your patient – conical or platform – is yours.

More information at →



WE ARE #DENTAURUM

Visit us! 14. – 18. 3. 2023
Hall 10.1 Stand D010/E019



D DENTAURUM
IMPLANTS

www.dentaurum-implants.com

BDIZ EDI checklists still in demand

Top priority: dental documentation

Even before the COVID-19 pandemic, BDIZ EDI had made dental documentation a top priority. In 2020/2021 we offered a webinar on this topic. Checklists for dental documentation are available for download in the members' area of the BDIZ EDI's German-language website. They provide clear examples of how dental documentation can work.



Stay tuned for English version end of 2023.

Patient and treatment records are the most important documents in dental liability cases. Seven years after the German Patients' Rights Act came into force, BDIZ EDI Legal Counsel Prof. Thomas Ratajczak still observes that many dentists in private practice do not have proper documentation procedures in place. For this reason, BDIZ EDI has developed a checklist covering all aspects of dental documentation: general information, background data, expert opinions and checklists for use in the practice.

What is part of the treatment record and what is part of the billing record? What should be kept in the patient file and what should not? Prof. Ratajczak, a lawyer specialising in medical and social law, has often seen these issues treated cavalierly and inadequately in practice—

even though documentation has long been a required aspect of any dental and medical treatment and is explicitly mentioned in the German Civil Code. And, according to Prof. Ratajczak, using the features provided by the billing software is not sufficient as medical documentation.

"The billing software and its records are of secondary importance in the eyes of the law", he explains. "Billing builds on and follows the treatment, not the other way around!" Specifically, records of billable services must be derived from the treatment documentation, rather than attempting to recover treatment data from accounting records.

What needs to be documented in the patient record? How detailed does the documentation have to be? How will subsequent changes to the data be assessed

in medical liability disputes? BDIZ EDI addresses these and other relevant questions in its checklists, which are available online.

Finding the checklists

Visit www.bdizedi.org

> Members

> News for Members

to retrieve the checklists – or simply scan the QR code. You must be logged in as a member.





IMPLANT SOLUTIONS WORLD SUMMIT

ATHENS 2023

Athens, Greece June 8-10, 2023

Where history, future
and science meet

Are you passionate about implant dentistry?

**Are you committed to science, innovation
and education?**

**Do you want to provide your patients with
optimized treatment solutions?**

Then join Dentsply Sirona, the world-leading expert
in implant dentistry, for an exclusive, state-of-the-art
congress in Athens, Greece, on June 8-10, 2023.

At Implant Solutions World Summit, you'll discover
cutting-edge science, the latest innovations in digital
dentistry, bone regeneration, and optimized implant
treatment solutions for your patients—and enjoy the
company of world-renowned speakers, colleagues
and friends from around the world.



dentsplysirona.com/worldsummit

[#ImplantSolutionsWorldSummit](https://twitter.com/ImplantSolutionsWorldSummit)

Follow Dentsply Sirona for
the latest in implant dentistry



dentsplysirona.com/implants



Dentsply
Sirona

Implant
Solutions

BDIZ EDI shows its colours at the 40th IDS in Cologne

Meeting Point Implantology 2023

Anyone wanting to meet the “movers and shakers” behind our work or get their hands on our new publications should visit the BDIZ EDI booth at IDS 2023, Hall 11.2, Booth O069, from 14 to 18 March 2023. As tradition dictates, the BDIZ EDI booth will once again be located opposite the German Dental Association.

The organisers are celebrating 100 years of IDS, and BDIZ EDI will of course be in on it again! “For 2023, as in earlier years, our Meeting Point Implantology is designed to bring together different types of competence and skills and to showcase 2023 the support BDIZ EDI can offer oral implantologists in Germany, Europe and beyond”, said BDIZ EDI President Christian Berger.

BDIZ EDI’s Table 2023 available to take home

The major talking points of the association will be presented at its booth: legal and billing support with BDIZ EDI legal counsel Prof. Thomas Ratajczak and the BDIZ EDI billing hotline with Kerstin Salhoff (since 2020). This also includes the “We-want-you” programme for young professionals, which is aimed at newcomers to oral implantology. BDIZ EDI will show the



different paths that lead to this field. An important module is the Curriculum Implantology, designed by Prof. Joachim E. Zöller, which is held at the University of Cologne. And there is BDIZ EDI’s Table 2023 to take home, which compares the various German fee schedules (GOZ, GOÄ, BEMA) and also includes the time factor for treatment length.



The BDIZ EDI booth before the start of IDS 2021.



The booth staff on all days: Christian Berger, Anita Wuttke, Dr Wolfgang Neumann, Helga Karanikas and Dr Stefan Liepe (from left).



Always a pleasure: Photo shoot with visitors from Spain.

**New Guideline:
“Update on short, angulated
and reduced-diameter implants”**

In early 2023, the European Consensus Conference (EuCC) under the auspices of BDIZ EDI will hold its discussions, remotely, and launch the 18th Guideline for implant dentistry. At IDS, the consensus paper, which addresses short, angulated, reduced-diameter and mini implants, will be available hot off the press in German and English.

**The success story continues:
BDIZ EDI webinars**

Early on in the COVID-19 pandemic, in 2020, BDIZ EDI offered online seminars with top-notch speakers to answer questions that dental practices feel are pressing ones. Some 17,000 participants have participated in these continuing-education courses with topics across the spectrum of interest to dental practices. The 2023 incarnation of our programme “BDIZ EDI informs” is already its fourth instalment—ever highly topical, ever highly informative. Topics include everything within (implantological) continuing education, from the focal surgical and restorative subjects to more marginal aspects, such as the influence of vitamin D on bone augmentation,



Many discussions took place in the international lounge of the BDIZ EDI. Here with representatives of the Croatian Dental Association, Dr Davorin Simunovic (third from left) and President Dr Hrvoje Pezo (fourth from left)...

crystal-meth addiction as a possible contraindication for implants, functional theory—and much more. Legal aspects will be addressed by Prof. Thomas Ratajczak, legal adviser of BDIZ EDI, and accounting issues will be discussed by Kerstin Salhoff. Other topics include tax-related innovations, practice strategies, etc.

Patient brochures available

“Implants—Long-lasting implant for long-lasting beauty”. This patient brochure, available in German and in English, is the absolute hit among our publications and can also be ordered from the BDIZ EDI

online store. Written in simple language and richly illustrated, it provides guidance for implant patients on successful oral hygiene.

**You have questions?
We like to provide answers**

Representatives of the board of BDIZ EDI will be on site in varying line-ups: Presidents Christian Berger and Prof. Joachim E. Zöller and the members of the board will be happy to answer your questions. Visit BDIZ EDI in Hall 11.2, Booth O069!

AWU



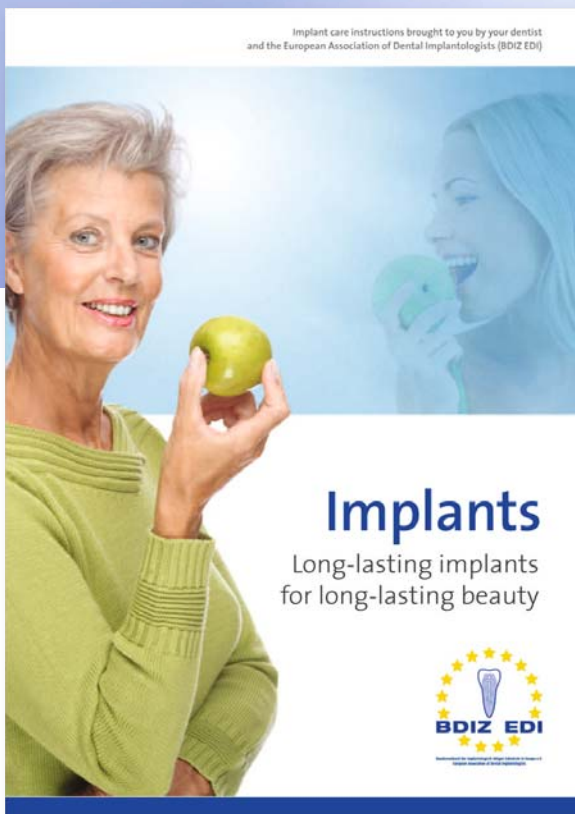...and in the German corner with BZÄK President Prof. Christoph Benz (second from left) and FDI Past President Dr Gerhard Seeberger (third from left).

Implant care instructions brochure for patients

Implant maintenance is a team effort

The European Association of Dental Implantologists (BDIZ EDI) has published an English edition of its implant maintenance brochure. In easy-to-understand language, the brochure entitled “Implants—longer-lasting and longer beautiful” offers well-illustrated instructions and general information about oral health.

Teamwork of patient and the dental office is the most important aspect of the brochure. The maintenance brochure is intended for distribution to patients by dental practices and was written to assist them in teaching their patients take care of their dental implants in the appropriate manner. The 24-page patient information brochure in A5 format consists of a general section about oral hygiene and a main section on implant maintenance—all about the right cleaning tools and their use with single-tooth implants as well as fixed and removable implant-



		Contents
I Introduction	I Proper implant care	I Good to know
<p>Introduction</p> <p>What is a dental implant? 4</p> <p>Why is oral hygiene important? 5</p> <p>Why is normal oral hygiene not good enough? 6</p> <p>Why do implants need particularly intensive care? 7</p> <p>Proper implant care</p> <p>What tools are available for cleaning? 8</p> <p>How do I properly use those tools? 9</p> <p>What should I consider when cleaning my implants? 10</p> <p>What is most important in the first days after implantation? 11</p> <p>Caring for single-tooth implants 12</p> <p>Caring for fixed dentures on implants 13</p> <p>Caring for removable dentures 14</p>	<p>Good to know</p> <p>Which toothbrush is the right one? 16</p> <p>Why professional tooth cleaning? 17</p> <p>Why do implants need a healthy environment? 18</p> <p>What is peri-implantitis? 19</p> <p>What are the risk factors? 20</p> <p>How often do I have to visit the dentist for a check-up? 21</p> <p>Checklist: Is everything as it should be with my implants? 22</p> <p>Will my implant play along in every situation? 23</p> <p>Service 24</p>	

© edwardolive - stock.adobe.com

supported restorations. "Good to know" provides background information on choosing the right toothbrush and using the proper brushing technique, describes the process of professional tooth cleaning and educates readers about risk factors. A checklist intends to alert implant patients to possible changes in the mouth and around the implant. This is the first English edition of the brochure, which has been completely redesigned with large images and short texts in easy language that patients can understand. The preface states: "It is up to you to ensure careful oral hygiene, and this is a prerequisite for a long implant life. Teamwork is of the essence!"

AWU

Bibliography

Implant care brochure of BDIZ EDI for patients
Long-lasting implants for long-lasting beauty

A5 format, 24 pages, 32 images
Prize: €1.50 + VAT + shipping (minimum order: 10)

Contact BDIZ EDI in Munich/Germany
office@bdizedi.org · www.bdizedi.org > English

Via Phone: +49 89 72069-888
Fax: +49 89 72069-889



INTRODUCTION

Why is normal oral hygiene not good enough?

The threat of bone loss

Dental plaque is home to numerous bacteria. As long as the plaque deposits are removed at regular intervals before they cause damage to the teeth or gums, the biological balance in the oral cavity will be maintained. But as soon as the plaque bacteria multiply, there will be an increasing risk of tooth decay and periodontal disease. Severe inflammatory conditions such as periodontitis (inflammation of the gums around a tooth) or peri-implantitis (inflammation of the gums around an implant) pose a significant risk for bone loss and may cause the loss of the tooth or implant.

What tools can and cannot do

- ▶ Toothbrushes (even the most futuristic electric ones) cannot clean the teeth everywhere because they do not get into the interdental spaces.
- ▶ Dental floss, interdental brushes or toothpicks are essential (there is even "thick" dental floss especially for use around implants). They are the only way to remove the bacterial plaque between the teeth.
- ▶ Oral irrigators are of limited use around implants and certainly not a substitute for proper tooth cleaning.

6



INTRODUCTION

Why do implants need particularly intensive care?

There is a natural protective barrier between each natural tooth and the surrounding gums. The transition zone between an implant and its surrounding gums can be passed more easily, so the risk is greater that bacteria can penetrate it and cause inflammation of the mucous membrane around the implant (peri-implant mucositis).

gressing, attacking the supporting jawbone and breaking it up or destroying it. The implant may work itself loose or even to fall out.

The many different types of bacteria in the mouth (in the oral cavity) will colonize implant roots in the same way as natural tooth roots.

But if you follow a few simple rules, things will not have to come this far. Proper maintenance is the be-all and end-all of implant care. You should invest a bit more time and effort than with "normal" tooth care. In this guide we show you how to maintain your implants carefully and gently.

Since implant surfaces are usually rough and may be designed in screw form (depending on the system), invading bacteria can settle down easily and will be difficult to remove even by an experienced professional. Unless it can be stopped, the inflammation will keep on pro-

7

BDIZ EDI Quality Guideline for Implantology

Recommendations for practitioners and patients

BDIZ EDI President Christian Berger explains in this interview why the association created the Quality Guideline for Implantology. Berger was instrumental in revising the Quality Guideline, which was first published in 2002 and is regularly updated—the latest update is from 2019. It is intended as a set of recommendations for practitioners and patients.



BDIZ EDI President Christian Berger talks about the revised Quality Guideline for Implantology.

What are the benefits of the BDIZ EDI Quality Guideline for Implantology?

Our Quality Guideline has the status of a recommendation and serves as a tool for self-evaluation and self-assessment. Only dental professionals know their own work and their patients, with all their expectations and problems. Only treatment providers themselves can reliably assess how the prevailing conditions—which influence every medical treatment, sometimes decisively—have positively or negatively influenced the respective treatment result. BDIZ EDI would like to emphasize the fact that the criteria are based on evidence from dental science. They can therefore claim validity even in the current political and scientific environment, where scientific evidence is unfortunately often disregarded when it comes to defining what constitutes fair remuneration. In 2000, the Quality Guideline was a first attempt to highlight the issue of quality in oral implantology in Germany. The Quality Guideline has been continuously modified and updated and will continue to be updated as necessary.

What about its implementation in practice?

First things first: The Quality Guideline is not intended to prescribe or introduce standardised treatment procedures or practice structures. Dentistry is a liberal profession, and it will continue to be up to dentists to decide how to achieve the required quality, because it is their responsibility to achieve it. The Quality Guideline sets out list of six quality criteria for implant procedures: medical history, examination, treatment planning, patient education, concomitant prevention—as well as implant surgery and implant prosthetics themselves. These quality criteria are assessed on the basis of five evaluation criteria: What is the indication for the proposed treatment? What are the treatment goals? What are the risk factors that affect the treatment goals? Are there standards related to the treatment measures? What are the indicators of treatment

outcome? This evaluation assigns the treatment result one of the following categories:

- A+ Excellent result with no reservations whatsoever
- A Good result, appropriate to aspire to in normal cases
- B Deficient, potentially harmful
- C Unacceptable, alternatives required

The Quality Guideline provides a step-by-step procedure for applying these quality and evaluation criteria, culminating in a list of criteria and of the categories A+ to C.

What is the aim of the BDIZ EDI Quality Guideline for Implantology?

Promoting quality in implant treatment has been the main objective of BDIZ EDI for 30 years now. It was no coincidence that in 2001 we received recognition from the German Federal Constitutional Court for a formal specialisation, or professional focus, on oral implantology for dentists. Our Quality and Registration (Q&R) Committee tests products and materials. We continue to develop our own biotope of implantological experts. We emphasize the importance of well-trained professionals who regularly participate in continuing education (CE) activities. And we publish annual Guidelines on current implantological issues complete with recommendations for clinicians. Of course, we know that assessing the quality of dental outcomes is not an easy task, not least because quality issues are controversial even among many experts in the field. Our aim is to provide implant dentists—and, where possible, their patients—with a suitably calibrated yardstick by which they can assess the results achieved for themselves and for their patients.

Thank you very much for your comments.

The interview was conducted by Anita Wuttke, Editor-in-Chief.

BDIZ EDI Quality Guideline for Implantology



BDIZ EDI Quality Guideline for Implantology
March 2019
Page 17 von 19

6.5.6 Surgical Procedure

- Conservation of soft tissue and bone
- Correct surgical access
- Prevention of heat damage to bones
- Correct implant position (location, length, angle)
- Implant with primary stability
- Bone augmentation using autologous, allogeneous or alloplastic material
- Sinus floor elevation and augmentation or internal sinus lift
- Neurolysis, repositioning of the nerve
- Guided bone regeneration (GBR)
- Soft-tissue grafting

6.5.7 Complications

- Postoperative bleeding
- Injury to neighbouring anatomical structures
- Pain
- Neuropathies or paraesthesia
- Infection (acute or chronic)
- Fistulas (nasal or maxillary sinus)
- Jaw fracture
- Reactive gingiva hyperplasia
- scarring
- Implant cannot be restored
- Instable implant
- Implant loss
- Tissue graft loss
- Implant fracture

6.5.8 Restorative treatment

- A passive fit of the implant-supported restoration must be ensured.
- The implant must not be overloaded during function.
- The implant-supported restoration should meet aesthetic requirements.
- The materials used must be innocuous to the implant.
- Implant-supported restorations must facilitate oral hygiene. In addition, the patient should be instructed in hygiene procedures once the implant-supported restoration has been delivered.

6.5.9 Postoperative Care/Recalls

- Individual professional postoperative care and maintenance must be ensured.
- The recall should be determined by the merits of the individual case.
- Minimum: annual clinical recalls plus radiological check-ups after 1, 3, 5 and 10 years.
- In case of pathological clinical radiological findings, shorter recall intervals will generally be required.

6.6 Indicators for evaluating results

- Clinical examination to evaluate wound healing
- Soft-tissue status, implant stability and radiological status after the end of the healing phase
- Clinical and radiological evaluation of the implant in the functional phase
- Subjective complaints/pain

BDIZ EDI
Mühlensstr. 18
D-51143 Köln
GERMANY

Fon: +49-2203-80 09 339
Fax: +49-2203-91 68 822
office@bdizedi.org
www.bdizedi.org



Bibliographical note

BDIZ Quality Guideline for Implantology. Updated March 2019. 17 A4 pages and cover. With a description of six quality criteria and five evaluation criteria and an overview of categories A+ to C. English version available for download from <https://bdizedi.org/en/quality-guidelines>.

BDIZ EDI and its multifaceted work

We want YOU!

At IDS 2017, BDIZ EDI launched its “We want you” information campaign. The aim is to interest young dentists from Germany and Europe in oral implantology and in the work of BDIZ EDI. These efforts will be intensified at IDS 2023.

WE WANT YOU

We are promoting the exchange of ideas within Europe: for dental clinicians interested in implant treatment!

Come and join us!

Become a member of a Europe-wide organization for dentists. More information: www.bdzid.org | we.want.you@bdizid.org

WE WANT YOU

„Wir führen Ihre Praxis durch den Dschungel von GOZ, BEMA, GOÄ und HOZ und zeigen Ihnen, wie Sie bei der Abrechnung im grünen Bereich bleiben.“

Wir setzen uns für alle Zahnarztpraxen ein!

Stärken Sie unseren Verband, damit wir weiterhin die richtige Abrechnungsfähigkeit für alle Zahnärzten/innen suchen können. Werden Sie Mitglied! Mehr unter: www.bdzid.org | we.want.you@bdizid.org

With the “We want you” campaign, the association wants to draw attention to the many different support services it offers for all dental practices, even beyond implantology, including continuing education for newcomers to the profession and seasoned practitioners alike.

BDIZ EDI is an active Europe-wide association that in 2002 went beyond the borders of Germany to forge collaborations, support partner associations and make its voice heard in EU politics. Of course, health policy interventions are also initiated at the federal level. BDIZ EDI is the only association to have presented its own draft law on combating corruption in the health sector. It is currently working intensively on the Medical Device Regulation (MDR) and its many problems.

With its information offensive, BDIZ EDI is highlighting its work in the field of continuing education:

- “Meet the Experts” allows newcomers to get in touch with experienced implantologists and top lecturers.
- An absolute must for anyone interested in implantology is the Implantology Curriculum, which is run in cooperation with the University of Cologne. This eight-module course teaches the key building blocks of implant dentistry to small groups of participants. The curriculum takes place at the University of Cologne. It runs for one year and is designed to be affordable for newcomers to the profession. It is planned to start the Curriculum South in Munich later this year. Some partner associations have adopted, and adapted, the modules for their countries: Greece, Serbia, Poland—and soon even India.

- Each year, the BDIZ EDI Expert Symposium provides an update on a current issue in implant dentistry, and the associated European Consensus Conference (EuCC) provides guidance for practitioners.
- The European Symposium of BDIZ EDI provides an opportunity to look beyond the local dental fence and to appreciate the work of European colleagues and exchange ideas. This year’s Europe Symposium will take place in June in a villa near Verona in cooperation with OEMUS MEDIA.

A wide field

The full scope of BDIZ EDI’s work is illustrated by the “BDIZ EDI informs” webinar series, which the association has been organising since the start of the COVID-19 pandemic in 2020. The continuing-education webinars feature top-notch presenters and cover dental topics (not just implantology!) as well as legal issues. The webinars are particularly suitable for strategic practice orientation for current and future practice owners. BDIZ EDI webinars are aimed at dentists and all members of the dental team. Participation is free of charge for members. On average, BDIZ EDI webinars are attended by between 150 and 400 participants. Members can view the recorded webinars in the seminar archive after the live broadcast.

AWU

Instagram, Facebook, Twitter, YouTube

BDIZ EDI on social media

Facebook, Instagram, Twitter and YouTube are the most popular social networking channels. BDIZ EDI uses these platforms to keep its own members and the members of partner associations, as well as all users interested in oral implantology, informed.

“In addition to Facebook, YouTube and Twitter, Instagram has become another important component of our social media activities”, says Dr Stefan Liepe, Managing Director of BDIZ EDI. “We want our channels to provide impartial information, both nationally and internationally, that is free of third-party interests. BDIZ EDI regularly provides information on implantology and topics relevant to dental practices in the areas of law, billing and prac-

tice hygiene. Of course, we also provide links to interesting professional articles and exciting behind-the-scenes insights about our association, which is active in Germany and in Europe.”

The online seminars that BDIZ EDI launched at the height of the COVID-19 crisis can be viewed on the YouTube channel. The latest information can be found on Instagram, Twitter and Facebook. BDIZ EDI often plays a pioneering

role when it comes to scrutinising laws and regulations that affect dentists—even taking cases to the German Constitutional Court if necessary. It intervenes in health policy on behalf of all dentists at the German and European level.

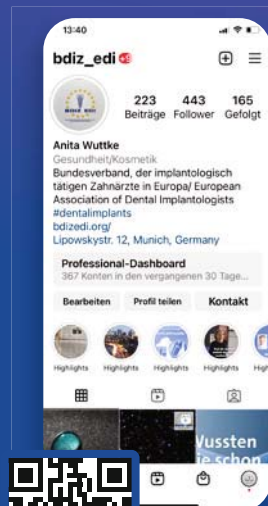At IDS 2023, BDIZ EDI will provide up-to-date news via its social media channels.

AWU

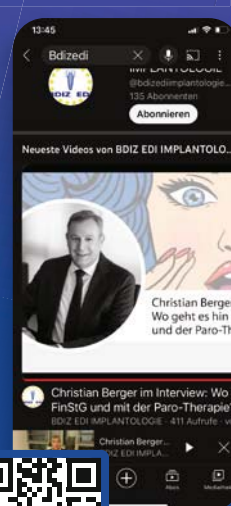
BDIZ EDI on social media:



Facebook
@bdizediorg



Instagram
@bdiz_edi



YouTube
@bdizediimplantologie7192



Twitter
@BDIZEDI

A brief look on dental issues in European/international newspapers

Dental News

At this point we would like to give you a brief glance of the world of European public media that have focused on dental topics recently.

The Irish News on 2 March 2023:

How common prescription pills could make your dental implants fall out. Dental implants can interact with all sorts of prescription medication. It is vital that your dentist knows about your medical history and medicine you are taking, writes Sophie Freeman.

Could your prescription pills affect the outcome of dental implant surgery? It's a problem highlighted by a recent study from dentists in Spain.

They found that people who were taking antidepressants—specifically, selective serotonin reuptake inhibitors (SSRIs)—at the time of their surgery, and for at least one year beforehand, had a more than 4.5-fold increased risk of their implants failing.

The 170 patients in the study were taking some of the most commonly prescribed SSRIs in the UK, such as citalopram, escitalopram, fluoxetine, fluvoxamine, paroxetine and sertraline.

Dental implants are replacement tooth roots, where a metal screw is placed directly into the jaw bone, providing a foundation for a false tooth to be fitted on top.

They are not usually provided on the NHS and can cost thousands to have done privately.

A 'failed' implant is defined as the implant falling out or moving, or the occurrence of bone loss, pain, or pus forming.

The researchers, from the Complutense University of Madrid, suggested that SSRIs may affect bone metabolism—i.e. its production and breakdown.

Normally, the body lays new bone directly on the implant surface, making it secure—a process called osseointegration. But this may not happen with SSRIs, resulting in the implant not integrating with the bone.

The drugs can also cause teeth-grinding, which can put pressure on implants, said the researchers in the *British Journal of Oral and Maxillofacial Surgery*. The medication can alter levels of the brain chemical dopamine, which is involved in muscle control.

Antipsychotics—prescribed for bipolar disorder, severe depression and schizophrenia—may also cause issues for dental implants, as they can cause teeth-grinding, too.

In a 2019 report in the journal *Australian Prescriber*, Geraldine Moses, a consultant pharmacist to the Australian Dental Association, wrote that "bruxism [i.e. teeth-grinding] is an under-recognised adverse drug reaction particularly associated with use of antipsychotics and SSRIs".

How worried should people be if they're taking these prescription medications and have had or intend to have dental implants?

Prof. Justin Durham, chief scientific adviser at the British Dental Association, described the findings as "interesting", but said that more research was needed before definitive conclusions were drawn, and clinical guidelines would not be changing based on the outcomes of the study.

Transparency Market Research Inc.

PEEK Dental Implants Market Value to Surpass US\$84.9 Million by 2031.

Rise in demand for PEEK dental implants in dental clinics is propelling the market

15 February, 2023 10:30 ET

Wilmington, Delaware, United States (GLOBE NEWSWIRE)

Source: *Transparency Market Research*

According to a study published by Transparency Market Research, the global PEEK dental implants market is expected to grow at a CAGR of 6.2% during the forecast period between 2022 and 2031.

The prevalence of dental disorders has increased among consumers of different age groups in the past few years. Hence, demand for products such as polyetheretherketone (PEEK) dental implants in dental procedures has increased. PEEK dental implant has features such as high strength, superior biocompatibility, and lightweight, which has made these implants a suitable choice over other products.

Advancements in three-dimensional printing technology have helped obtain improved, customised PEEK

dental implants. An increase in demand for these products is likely to drive industry growth during the forecast period.

Leading players are gaining an edge over competitors and generating revenue by launching new PEEK dental implants. Additionally, prominent players are collaborating with other players to expand their presence and improve revenue share.

Request to Sample PDF of this Strategic Report

(Use Corporate Mail ID for Top Priority):

https://www.transparencymarketresearch.com/sample/sample.php?flag=S&rep_id=46392

Key Findings of Market Study

- **Rise in Usage of Dental Bridges to Replace Missing Teeth:** Based on product, the global market has been classified into dental bridges, dental abutments, dental dentures, and dental crowns. The dental bridges segment emerged as the dominant segment in 2021, as these are more reliable and cost-effective than other products. Dental bridges can be customised to the shape, size, and colour of the teeth. Furthermore, dental bridges can be easily fabricated and installed with fewer visits to dentist. These factors are likely to augment the segment.
- **Increase in PEEK Dental Implants Demand in Dental Clinics:** In terms of end-use, the global market has been divided into hospitals, dental clinics, and others. The dental clinics segment is projected to account for the dominant market share during the forecast period, as these facilities offer services such as placement of PEEK dental implants. Dental clinics can be accessed easily by patients and are equipped with modern technology to conduct the desired dental procedures.

Key Drivers

- Rise in need for missing teeth replacement among the geriatric population is driving the PEEK dental implants market
- An increase in demand for cosmetic procedures globally is anticipated to boost market demand during the forecast period

Regional Insights

- Europe is projected to emerge as the leading region during the forecast period. Increase in awareness in Germany and the U.K. about the advantages of using dental implants to improve dental health is expected to accelerate market development in the region
- Asia Pacific is anticipated to witness significant growth during the forecast period due to rise in dental tourism, availability of cost-efficient dental procedures, and the production of new materials for dental implants in India and China

Certification as an EDA Expert in Implantology

Qualification for experienced implantologists

For many years, BDIZ EDI has been catering to experienced and well-versed oral implantologists by offering the certification exam for EDA Expert in Implantology. Jointly with the European Dental Association (EDA), BDIZ EDI regularly invites interested dentists to take the certification exam, which we would like to present in this article.

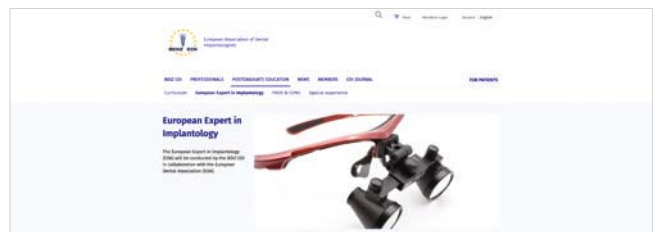
That quality is of paramount importance to BDIZ EDI is no secret. BDIZ EDI has demonstrated this in many different areas—legal and accounting, materials testing, postgraduate education, the annual Guidelines of the European Consensus Conference (EuCC) on current implantological issues and finally the qualification of court experts. BDIZ EDI also supports dental education with its Curriculum Implantology that introduces aspiring dentists and young implantologists to this dental specialty in eight well-organised modules.

Admission requirements for the certification exam

Certification as Expert in Implantology requires very good to excellent skills and knowledge. Candidates must meet the following admission requirements:

- 250 EDA-recognised continuing education/training hours in various sub-disciplines of implantology
- Submission of ten documented, independently performed implantological treatment cases
- At least five years of professional activity, primarily in the field of implantology.

Specific experience and primary activity in the field of implantology must be documented by at least 400 implants inserted and



150 implants restored within the past five years. Candidates who already obtained qualifications in oral implantology (e.g. from other professional societies) may submit the appropriate credentials with their application for certification as EDA Expert in Implantology.

The exam

Candidates meeting all the requirements will be admitted to the examination. The examination board of BDIZ EDI and EDA consists of recognised specialists. The exam has a theoretical and a practical part, both of which must be completed successfully. The procedure is as follows: The theoretical part of the exam will start with a discussion of the documented cases. In addition, candidates are expected to answer questions related to oral implantology and closely associated fields. The theoretical examination usually takes no longer than 60 minutes; it may be administered to candidates in groups. The practical part of the examination covers one or more recognised, state-of-the-art treatment method or methods and/or treatment plans covering some aspect of oral implantology. Candidates will be informed of the respective topic two weeks before the exam date. Candidates are responsible for providing the required materials and instruments on the day of the exam. The examination as a whole is subject to a fee to cover the cost incurred by the examination board.

New EDA Experts in Implantology are nominated by the president or vice president of the EDA certification committee.

More information...

To register for the next certification exam, please go to www.bdizedi.org and select English > Professionals > Expert or write to the BDIZ EDI office in Cologne at office@bdizedi.org.





Applicant's address:

Full name:

Full address:

.....

.....

E-mail:

Date:

Forward by mail or fax to:

European Association of Dental Implantologists (BDIZ EDI)
Lipowskystr. 12
81373 Munich
Germany

office@bdizedi.org

Fax: +49 89 72069889

**Certification exam: EDA Expert in Implantology
Application for accreditation**

I hereby apply for the EDA Expert in Implantology certification exam (EDA = European Dental Association).

I am qualified for this exam as defined below:

Member of BDIZ EDI yes no

Member of the following Societies/Associations:

I am: a dental clinician an oral surgeon a maxillofacial surgeon

I meet the training requirement of 250 hours of postgraduate education. yes no

Education and experience:

Surgery:

Inserted implants: less than 400 more than 400

Sinus lift: yes no

Close to nerve: yes no

Advanced atrophy of the jaw: yes no

Soft-tissue augmentation: yes no

Bone augmentation: yes no

Prosthodontics:

Implant-supported restorations: less than 150 150 or more

During the exam, I will be able to present documentation for 10 treatment cases. yes no

I understand that the examination board will review my qualifications and vote to accept or reject my application. Furthermore, I declare that all images I present are my own and that the implants have been inserted and prosthetically restored by me.


.....
Applicant's signature

.....
Date

Having successfully passed the exam and paid the requisite fee, I will be certified as EDA Expert in Implantology.

Dutchman stole patient data on a grand scale

All Austrians affected



For years stolen confidential data was sold on the dark net, including the Austrian civil register. Dutch investigators have now arrested a man, who has allegedly stolen and sold personal data of millions of people worldwide. The 25-year-old Dutchman was arrested back in November following a tip-off from the Austrian Federal Criminal Police Agency. However, the case was not made public by the prosecutors' office in Amsterdam until January.

According to the information there is an urgent suspicion that the arrested has sold confidential data, including patient data from medical records for a long period of time. This is supposed to be data of persons from the Netherlands, Austria, Thailand, Columbia, China and the UK. In Austria all inhabitants are affected as the entire civil register was for sale. The operator of the register, the Federal Ministry of the Interior denied having been hacked. Thus, the Austrian Broadcasting Cooperation ORF subsidiary GIS (Gebühren Info Service—fee information service), which is responsible for collecting the broadcasting license fees and therefore has access to the entire civil register, has been suspected. The GIS stressed the ISO certification of all its IT systems and denied any omissions.

It has now become clear that the civil register originated from the GIS but has not been obtained through the GIS. As the ORF stated with reference to the Austrian Federal Criminal Police Agency, the GIS had given the entire civil register to an IT service provider who placed the data on a completely unprotected server.

Source: Heise online

One in five Swiss does not attend dentist

Lack of money causing insufficient dental care

According to the International Health Policy Survey 2020, 20.7 per cent of the Swiss population is not attending dental appointments out of financial reasons. The study included 2,248 persons from Switzerland and was submitted online or by phone. A representative sample of the Swiss Federal Statistical Office was used. For Katharina Prelicz-Huber, national council of the Swiss Green Liberal Party, it is an unacceptable condition. The Zurich national council is pursuing an attempt to establish that the costs for necessary dental treatment including regular check-ups and dental hygiene shall be covered by the mandatory health insurance through federal funds. Whereas national council Regine Sauter of the FDP liberal party argues that having the health insurance companies covering these costs would be the wrong approach. "This would result in an enormous cost increase as well as a further insurance premium rise." Currently social services are already covering such costs if somebody can provenly not pay for dental treatment. "The principle of giving everybody an equal share does not make sense. The general public should not be paying for somebody who is not in actual need. The risk of a further rise of payments increases if health insurance companies are covering everything."



Prof. Hendrik Meyer-Lückel, director of the clinic for dental preservation, preventive and pediatric dentistry at the University of Bern, emphasizes that sufficient oral hygiene is an important factor for dental and oral health. However, he also says: "Direct impacts on general diseases do not tend to be in the focus." Thus Prof. Meyer-Lückel does not see the necessity for basic insurance to cover dental treatment costs.

Source: ZWP online

UK News

Teacher provides student with toothbrush

Four out of five teachers in Great Britain are providing their students with tooth paste and toothbrushes, as due to the inflation they have no funds to buy such themselves. The British Dental Association (BDA) is revealing dramatic circumstances. In cooperation with the charity organisation Beauty Banks the BDA has questioned secondary school teachers throughout Great Britain. According to the BDA the study shows the students' "shocking situation in oral health". Thus 83 per cent of the questioned secondary school teachers admitted that their school is providing stu-



dents with tooth paste and toothbrushes. 81 per cent of the teachers stated that there are children at their school that have no access to toothpaste. 40 per cent detailed that it results in students socially excluding co-students due to poor dental hygiene. Half of the participants wrote that the kids isolate themselves. One third directly experienced mobbing in this context. Half of the students admitted to suffering from tooth decay.

"The poor economic situation and the problems in access to medications will inevitably lead to more patients rescheduling their treatments which will result in more expensive and more time-consuming therapies in the future," concludes the BDA. "We urgently have to start acting in order to reestablish treatment access and to eliminate obstacles. We will further pursue a reformed NHS dentist contract that sets a focus on prevention."

Source: *several*

Novel method helps distinguish

Imaging provides more insight

Scientists from Brazil have succeeded in distinguishing an ameloblastoma from an odontogenic kercocyst already in the imaging stage. The novel method differentiates oral bone lesions based on the image texture of MRT scans. Ameloblastomes and odontogenic kercocysts are benign tumors of the maxillary region with different biological characteristics. Ameloblastomes grow infiltrative and can also degenerate into malignancy over time. Kercocysts are aggressively growing but primarily benign unicystic or multicystic intraosseous neoplasms of odontogenic origin. Both however are in practice characterised by very similar morphological features and are hard to differentiate with common imaging techniques. Surgically they demand different procedures. Searching for a solution to predict the type of lesion early on and to facilitate surgical planning a team of scientists of the University Cruzeiro do Sul, University of São Paulo and the University of Campinas in Brazil in cooperation with colleagues from the University of Gothenburg in Sweden and Ankara University in Turkey has used an imaging technique called "texture analysis" on these lesions. The study sample included 18 patients, which have been diagnosed with one of the described lesions. In all cases the diagnosis was confirmed by biopsy. Eight subjects had ameloblastomes, ten kercocysts. MRT scans were used for the analysis. Eleven texture parameters were measured in five different distances, which resulted in 55 variables.

The variables "entropy" and "total average" proved to be of statistical significance. The first refers to the degree of disorder in between the pixels of the concerning image, whereas the latter indicates the sum average of two pixel values in the picture. Kercocysts show a higher regularity and a lower disturbance of gray scales than ameloblastomes. In three-dimensional imaging techniques like MRT and CAT scans the voxel [unit indicating volume in 3D space] and pixel are in a different order regarding distance and grayscales, which vary depending on the scanned tissue. "This data can be turned into numeric values—algorithms—in order to conduct a mathematical and statistical analysis," explains Prof. André Luiz Ferreira Costa, one of the authors. A fast diagnostic decision ensures higher planning security prior to surgery: "The most important achievement of this study is the possibility to faster obtain a definitive result through imaging and thus enabling an appropriate and safe treatment," adds Costa.

Source: *zm online*

Literature:

Gomes JPP, Ogawa CM, Silveira RV, Castellano G, De Rosa CS, Yasuda CL, Rocha AC, Hasseus B, Orhan K, Braz-Silva PH, Costa ALF. Magnetic resonance imaging texture analysis to differentiate ameloblastoma from odontogenic keratocyst. *Sci Rep.* 2022 Nov 21;12(1):20047. doi: 10.1038/s41598-022-20802-7. PMID: 36414657; PMCID: PMC9681845. <https://www.nature.com/articles/s41598-022-20802-7>



© Cifotart – stock.adobe.com

Judgement of the European Court of Justice in Case C-530/20 | EUROAPTIEKA

Ban on advertising medicinal products compatible with Union law

The Latvian law banning the advertising of medicinal products on the basis of price, special sales or bundled sales of medicinal products and other products is compatible with EU law. Such advertising content promotes the irrational use of medicinal products and must be prohibited by Member States.

Directive 2001/83/EC harmonises the law on the advertising of medicinal products, by making it subject to conditions, restrictions and prohibitions in order to safeguard public health. SIA “EUROAPTIEKA” is a Latvian limited liability company operating a pharmaceutical business in Latvia. In 2016, the Latvian Health Inspectorate banned it from disseminating an advertisement for a special sale of medicinal products, on the basis of a national provision banning advertising of medicinal products on the basis of price, special sales or bundled sales of medicinal products and other products.

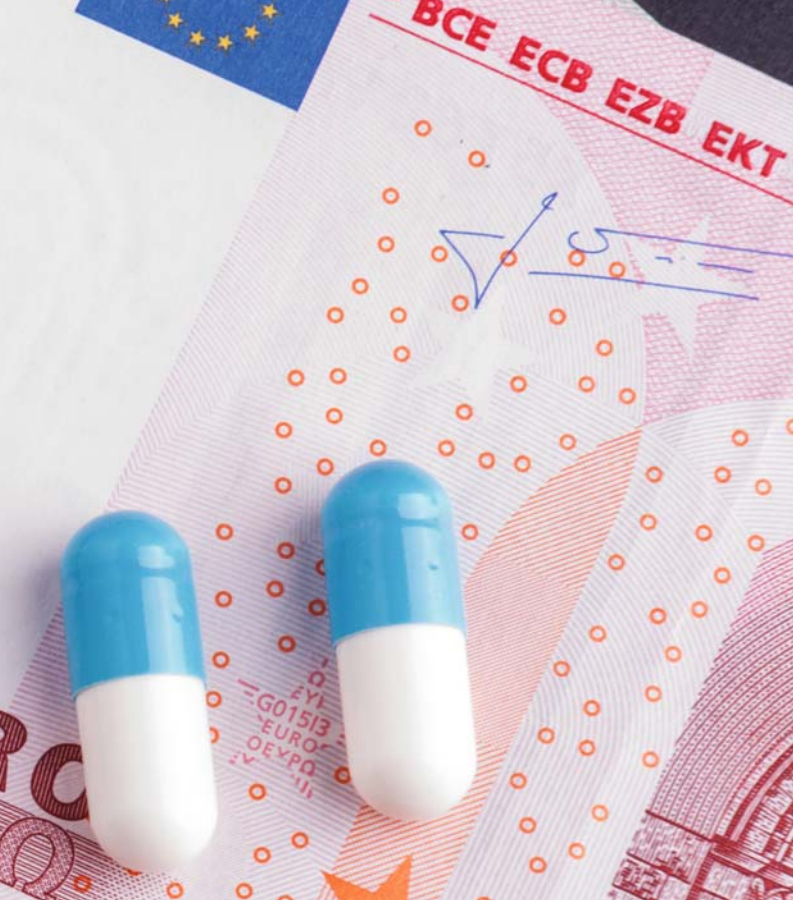The case

In 2020, “EUROAPTIEKA” brought an action for annulment before the Latvian Constitutional Court challenging the legality of that national provision in the light of Directive 2001/83. That

court asks the Court of Justice about the interpretation to be given to the concept of “advertising of medicinal products”, within the meaning of that directive, and, in particular, whether that concept also covers the advertising of unspecified medicinal products, that is to say advertising of medicinal products in general or a set of non-identified medicinal products. It also asks the Court of Justice whether the prohibition, laid down by the national provision in question, on advertising on the basis of price, special offers or bundled sales of medicinal products and other products is compatible with that directive.

ECJ: Sale or consumption of unspecified medicinal products

By its judgement, the Court of Justice, sitting as the Grand Chamber, finds, first of all, that the concept of “advertising of



medicinal products” covers any form of door-to-door information, canvassing activity or inducement designed to promote the prescription, supply, sale or consumption of unspecified medicinal products. That concept is very broadly defined, in Directive 2001/83, as including “any form” of door-to-door information, canvassing activity or inducement, including, in particular, “the advertising of medicinal products to the general public”. Furthermore, if the advertising of unspecified medicinal products were excluded from the scope of application of Directive 2001/83, the prohibitions, conditions and restrictions that it lays down in respect of advertising owing to the risks that result from excessive or ill-considered use of medicinal products would be largely deprived of their effectiveness and the essential aim of safeguarding public health pursued by that directive would be greatly compromised. In this case, the Court considers that the dissemination of information that encourages the purchase of medicines by justifying the need for such a purchase on the basis of the price, by announcing a special sale, or by offering a sale that is bundled together with the sale of other medicinal products or other products, such as that prohibited by the national provision challenged before the referring court, has a promotional purpose. According to the Court of Justice, that dissemination of information consequently falls within the concept of “advertising of medicinal products”, even where that information does not refer to a specific medicinal product, but to unspecified medicinal products. As regards, next, the compatibility of that national provision with Directive 2001/83, the Court of Justice observes that the advertising of medicaments that are neither subject to medical prescription nor reimbursed, which are more specifically concerned by that national provision, is in principle permitted by that directive. Member States are nevertheless obliged to prohibit the inclusion, in advertising to the

public of medicinal products which are neither subject to medical prescription nor reimbursed, of material which is of such a nature as to promote the irrational use of such medicinal products.

Advertisement treats medicinal products in the same way as other consumer goods

The Court emphasises, in that regard, that the advertising of medicinal products that are neither subject to medical prescription nor reimbursed may exercise a particularly strong influence on the evaluation and choice made by final consumers, both as regards the quality of the medicinal product and the amount to purchase. In addition, advertising on the basis of price and advertising of special sales or for bundled sales of medicinal products and other products is likely to lead final consumers to purchase and consume those medicinal products on the basis of an economic criterion without carrying out an objective evaluation based on the therapeutic properties of those products and on specific medical needs. Such advertising content furthermore treats medicinal products in the same way as other consumer goods, which are in general the subject of discount and price reductions.

According to the Court, advertising on the basis of price and advertising of special sales or bundled sales of medicinal products and other products encourages the irrational and excessive use of medicinal products that are neither subject to medical prescription nor reimbursed. Consequently, the national provision at issue before the referring court, which bans the dissemination of those types of advertising content is compatible with Directive 2001/83.

Note

A reference for a preliminary ruling allows the courts and tribunals of the Member States, in disputes which have been brought before them, to refer questions to the Court of Justice about the interpretation of European Union law or the validity of a European Union act. The Court of Justice does not decide the dispute itself. It is for the national court or tribunal to dispose of the case in accordance with the Court’s decision, which is similarly binding on other national courts or tribunals before which a similar issue is raised.

Source: ECJ press release

16th European Symposium of BDIZ EDI and Giornate Veronesi

Implantology and modern dentistry

Oral implantology and modern dentistry will be on the agenda in Valpolicella (Italy) on 16 and 17 June 2023. In cooperation with the 16th European Symposium of BDIZ EDI, the Giornate Veronesi—under the Italian sun, so to speak—will offer top-class scientific lectures, seminars and table clinics as well as a comprehensive supporting programme.



Entrance to the VILLA QUARANTA TOMMASI WINE HOTEL & SPA in Valpolicella/Italy.



Like speed dating: the format of workshops.



Beautiful surroundings to relax in the evening.

When it is cold, dark and grey in winter, it is time to think about the sun of Italy and a training event with that special Italian flair—the Giornate Veronesi (Verona Days).

Convening at the VILLA QUARANTA TOMMASI WINE HOTEL & SPA in Valpolicella (Italy), dentists and their teams will enjoy a unique opportunity to combine business with pleasure. The scientific programme will cover a broad array of subjects. In addition to oral implantology, the focal topic, general dentistry issues will be addressed throughout, and there will be an interesting programme for the dental team. The language of the Symposium will be German.

The Giornate Veronesi will offer plenty of room for discussions with presenters and an exchange of views with other professionals. In addition to the technical programme, the Friday get-together and the Saturday dinner party with wine and music will provide ample opportunity for this. Since the event will take place at the famous winery of the Tommasi family, it feels natural to offer congress participants the chance to attend a wine seminar where they will receive “expert” training in the oenological field.

The BDIZ EDI approach

“Small opportunities are often the beginning of great enterprises.” This quote from Demosthenes has been character-

istic of the history of BDIZ EDI’s European Symposia. Humble beginnings and spurious opportunities have been consolidated into a comprehensive approach that allows communities of dentists to transcend national borders. With its cooperation partner OEMUS MEDIA AG, BDIZ EDI now presents its 16th European Symposium, showing once again how oral implantologists from different countries can mutually benefit from their assembled knowledge.

RED

More information...

OEMUS MEDIA AG

Holbeinstraße 29
04229 Leipzig, Germany

+49 341 48474-308
+49 341 48474-290 (Fax)
event@oemus-media.de
www.oemus.com
www.giornate-veronesi.info

Did you ever know...



...that for many years BDIZ EDI

has been an exhibitor at the International Dental Show (IDS)? The association always has its booth in Hall 11.2 at the fair in Cologne opposite the German Dental Association. Also at the IDS 2023 from 14 to 18 March, BDZI EDI will once again participate – and of course as tradition dictates have its booth located opposite the German Dental Association: Hall 11.2, Booth O069.

Definitely stop by and get the newest information on billing, law, symposiums and further education!



...that the BDIZ EDI

is developing a guideline for implant dentistry every year? In 2023 it will be focused on an update on short, angulated reduced-diameter implants. The guideline can be ordered from the BDIZ EDI's online shop. If you stop by at the BDIZ EDI's booth at IDS you can get the guideline for free. The guideline will be available in both English and German.



...that the BDIZ EDI

has moved its headquarters to Munich? As of January 2023, BDIZ EDI's heart with all its functions can be found in South Munich, near Theresienwiese. Therefore, the phone numbers have changed. You can now reach the association by phone at: + 49 89 72069-888, via fax: +49 89 72069-889 or the billing hotline (only on Tuesdays from 8 a.m. to 12 p.m.) at: +49 89 72069-883.

More information on all tasks:



European Commission adopted proposal to extend transition period of MDR

Mitigate the risk of shortages

The European Commission developed the new proposal following a 9 December 2022 meeting of the EPSCO Council, where EU Ministers of Health called on the Commission to swiftly submit a proposal to extend the transition period in the Medical Device Regulation. The proposal will now be negotiated by the European Parliament and the Council.

On 6 January the European Commission adopted a proposal to give more time to certify medical devices under EU MDR to mitigate the risk of shortages. The proposal needs to be adopted by the European Parliament and the Council.

The proposal introduces a longer transition period based on the medical devices' risk class. It will also allow medical devices placed on the market in accordance with the current legal framework and that are still available to remain on the market (i.e., no "sell-off" date).

The proposal does not change any of the current safety and performance requirements provided for in the EU MDR. It only amends the transitional provisions to give more time for manufacturers to transition from the previously applicable rules to the new requirements of the Regulation.

The length of the proposed extension of the transition periods depends on the type of device: higher risk devices such as pacemakers and hip implants would benefit from a shorter transition period (until December 2027) than medium and lower risk ones, such as syringes or reusable surgical instruments (until December 2028).

Key elements of the proposal:

- For medical devices covered by a certificate or a declaration of conformity issued before 26 May 2021 the transition period to the new rules is extended from 26 May 2024 to 31 December 2027 for higher risk devices and until 31 December 2028 for medium and lower risk devices. The extension will be subject to certain conditions, so that only devices that are safe and for which manufacturers have already taken steps to transition to the rules provided for by the Medical Devices Regulation will benefit from the additional time.
- The proposal introduces a transition period until 26 May 2026 for class III implantable custom-made devices, which would give their manufacturers more time to obtain certification by a notified body. Also in this case, the transition period is subject to the application of the manufacturer for a conformity assessment of devices of this type before 26 May 2024.
- To reflect the transition periods put forward by these amendments, the proposal extends the validity of certificates issued up until 26 May 2021, the day when the Medical Devices Regulation became applicable.
- The Commission also proposes to remove the 'sell-off' date currently established in the MDR and in the IVDR. The 'sell-off' date is the end date after which devices that have already been placed on the market, and remain available for purchase, should be withdrawn.



© alexlmx – stock.adobe.com

The European Commission developed the new proposal following a 9 December 2022 meeting of the EPSCO Council, where EU Ministers of Health called on the Commission to swiftly submit a proposal to extend the transition period in the Medical Device Regulation. The proposal will now be negotiated by the European Parliament and the Council.

“Our rules on medical devices will always prioritise patient safety and support for innovation. A combination of factors has left healthcare systems across the EU facing a risk of shortages of life-saving medical devices for patients,” said Stella Kyriakides, Commissioner for Health and Food Safety. “Today, we propose a revised regulatory timeline to provide certainty to industry in order to continue producing essential medical devices, reducing any short-term risk of shortages and safeguarding access for patients most in need. I call on the European Parliament and the Council to quickly adopt the proposal. Member States and notified bodies should also work with industry to ensure transition to the new rules provided for by the Medical Devices Regulation, without further delay.”

AD

CERAMIC IMPLANTS MEETS AESTHETICS

5-6 MAY 2023
MUNICH

7TH ANNUAL MEETING OF

ISMI | INT. SOCIETY
OF METAL FREE
IMPLANTOLOGY



PREMIUM PARTNER:

SDS SWISS DENTAL
SOLUTIONS 





Extended transition period for the EU Medical Device Regulation does not help

MDR: Deadline extension a drop in the ocean

The problems of implementing the requirements of the EU's Medical Device Regulation (MDR) for device manufacturers have been pressing ever since the regulation came into force. Now, after much hesitation, EU Health Commissioner Stella Kyriakides has finally reacted. However, according to BDIZ EDI, her "solutions" are just a drop in the ocean.

While the further extension of the transitional provisions of Art. 120 MDR, which are intended to alleviate the massive problems associated with the recertification of existing products, is certainly welcome, BDIZ EDI continues to criticise the EU Commission's ironclad adherence to the bureaucratic monster that is the MDR. Nothing of substance will change.

Still not enough Notified Bodies

There are still too few Notified Bodies. The certification process is as complicated as it is expensive. Small and medium-sized enterprises are particularly affected. In an anonymous survey of the dental industry conducted by BDIZ EDI in 2019, more than 45 per cent of participating manufacturers said they would withdraw products from the market because of the MDR. BDIZ EDI fears that the situation is even worse today.

BDIZ EDI President Christian Berger said: "This will of course also have an impact on many dental treatments. We fear—and we are not the only ones—that small and medium-sized device manufacturers and manufacturers of niche products will not be able to survive much longer."

BDIZ EDI forecast

The new deadlines depend on the risk class of the medical device and are designed to ensure that users such as dentists and physicians continue to have access to medical devices for their patients. Higher-risk devices, such as implants, will have a shorter transition period, until December 2027, than medium- and lower-risk devices, such as syringes, which will have until December 2028 to obtain MDR certification. There will also be no mandatory phase-out date, meaning that products marketed under the current regulatory framework that are still available can remain on the market.

Even before the COVID-19 pandemic, BDIZ EDI had called for the implementation to be postponed by several years, citing a lack of Notified Bodies and a non-functioning central EUDAMED database. None of the objectives of the MDR can be achieved by the original effective date, BDIZ EDI predicted at the time.

Source: *BDIZ EDI press release*

Osstem's New Generation

KS System



*Strong!
Simple!
Easy!*



The bone core technique:

Reconstructing peri-implant bone defects using minimally invasive autologous bone augmentation

Dr Alexander Zastera, M.Sc. & Prof. Dr Fouad Khoury, Germany

Gentle preparation of the implant site and the harvesting of bone from the site using minimally invasive trephine burs are basic prerequisites for the predictable augmentation of alveolar ridge defects using the autologous bone core technique. Pilot drilling is performed with a two-piece trephine bur to harvest the maximum amount of bone for augmentation. Advantages include reduced morbidity due to the elimination of an additional donor site, reduced treatment time, and no need for membranes or foreign-material substitutes. As an autologous augmentation technique, the bone core technique is (as known as carot technique) characterised by a high osteoconductive, osteoinductive and osteogenic potential. Autologous bone grafts remain the gold standard in dental implantology due to their biological advantages.

Removal of non-salvageable implants or teeth initiates resorption processes that can significantly compromise the osseous implant site. For aesthetic and prosthetic-functional reasons, augmentation is often required to reconstruct lost hard and soft tissue. The complex rehabilitation of these defects by hard- and soft-tissue augmentation has become an established procedure.¹

There are several surgical techniques to replace lost hard tissue. Techniques, potential bone-harvesting sites and available substitute materials have been evaluated in a number of studies.¹⁻³ A number of factors need to be considered to ensure the success of these, sometimes extensive, surgical procedures. Prominent among them is a biological understanding of the regeneration processes in the bacterially

colonised oral cavity. Predictable augmentation is a prerequisite for subsequent implant placement in a prosthetically tenable position.^{1,4}

To date, autologous bone is still considered the gold standard in oral implantology, especially for lateral and vertical augmentation sites.⁵⁻⁸ Autologous bone is characterised by excellent osteoconductive, osteoinductive and osteogenic

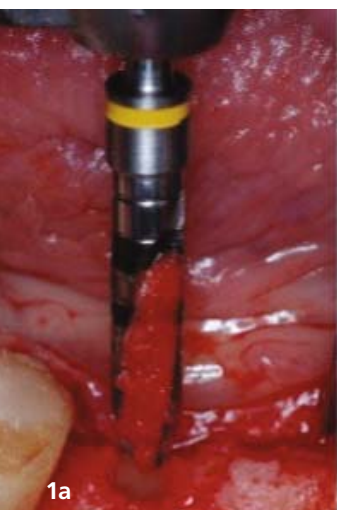

Fig. 1a: Harvesting bone chips during implant bed preparation at low drill speed and without irrigation. **Fig. 1b:** The micro-screw kit.

properties.³ Graft materials of different origins have only osteoconductive properties. Bone block grafts can be obtained in various shapes and sizes, both extra- and intraorally.⁹ Although autologous bone chips can be harvested from various intra-oral sites, they are not dimensionally stable and are therefore usually mixed with bone substitute materials and covered with resorbable or non-resorbable membranes for crestal bone augmentation.¹⁰⁻¹² In addition to the risk of early membrane exposure and associated infection, which can lead to the loss of the augmentation material, this treatment modality is associated with long healing times of up to nine months and expensive materials.¹²⁻¹⁴

Bone block grafts used for the shell technique are most commonly harvested from the external oblique line of the mandibular ramus and can usually be used successfully for all forms of bone augmentation.^{1,9,15} These bone block grafts can be harvested reliably and reproducibly, but the procedure imposes a certain burden on the patient due to the need for a second surgical site.

The bone core technique is based on the use of bone harvested locally at the implant site and has been used successfully in many indications.² This article describes and discusses this minimally invasive method of bone augmentation based on a case series covering various indications.

Materials and methods

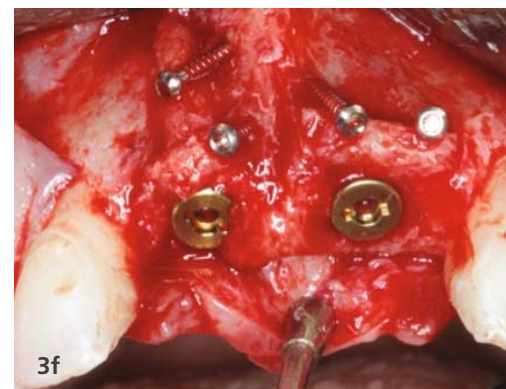
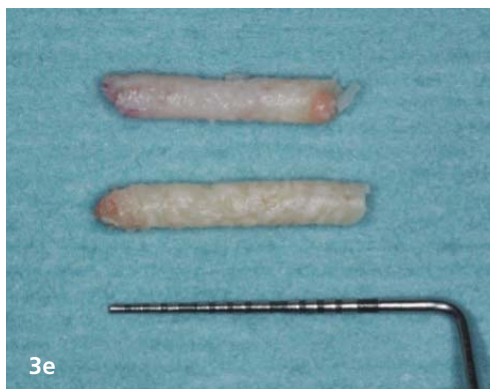
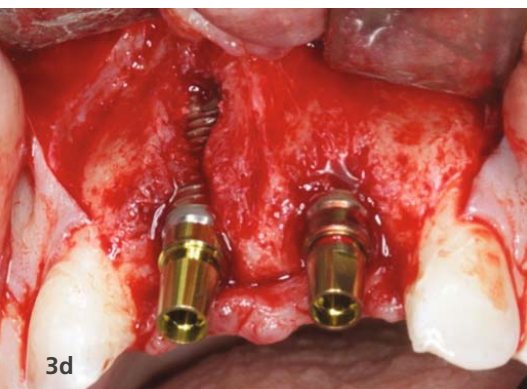
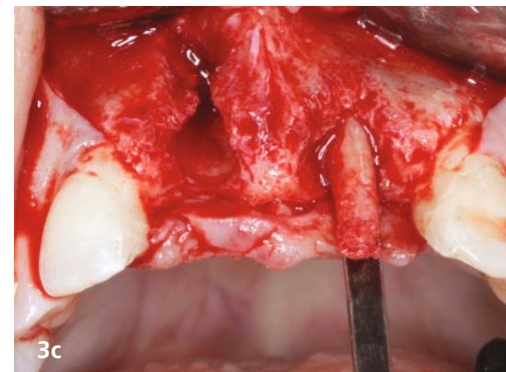
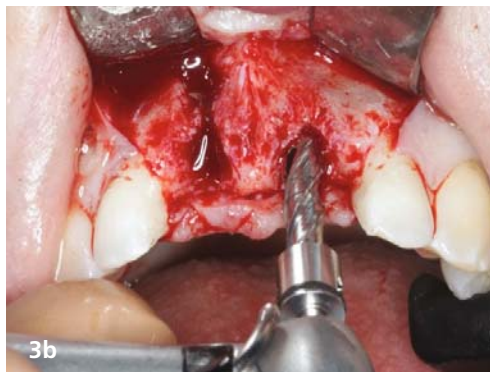
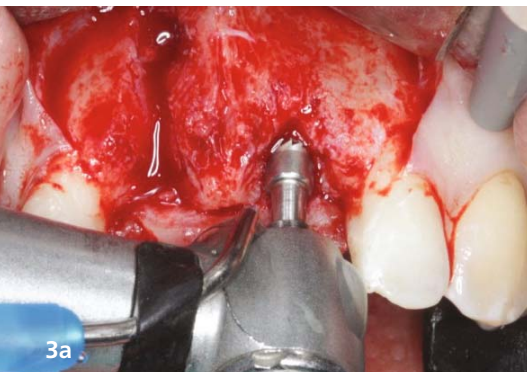
The bone core technique is based on removing a stable core of bone from the future implant site using a trephine bur. Additional bone chips are harvested during the various drilling steps until the final diameter of the implant bed is reached. Implant drilling is performed at low speed (approximately 80–120 rpm) in well-moistened alveolar bone and without cooling (Fig. 1a). If the implant site is poorly perfused due to the vasoconstrictive effect of the local anaesthetic, the socket is irrigated with saline to prevent bone damage due to overheating. The range of indications for the bone core technique is limited to defect situations where the residual width of the alveolar ridge allows simultaneous implant place-

ment within its contours accompanied by a bone deficit in the buccal or palatal/lingual bone wall. After implant placement, the bone core in the crestal region of the bone defect is compressed and stabilised against the implant surface with microscrews (Fig. 1b). The remaining free implant threads are covered with bone chips, and the voids are filled.⁹

It is not uncommon for the bone core to break out of the implant bed during drilling and remain in the trephine. Drilling and subsequent removal from a one-piece system can be complicated, especially if the cutting performance of the trephine is inadequate due to prolonged use. This can cause the trephine to derail due to lack of guidance, particularly in cortical bone. To simplify this technique, a two-part trephine kit (Meisinger) has been developed with four different trephine diameters and corresponding pre-trephines (Figs. 2a–e). The pre-trephines mark the harvesting area and guide the trephine for safe and precise drilling (Figs. 3a & b). The trephine burs are externally and internally cooled to prevent overheating of the bone core and future

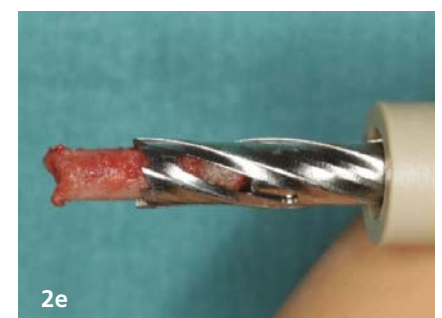

Fig. 2a: The trephine kit. **Fig. 2b:** Four pre-trephines with different diameters. **Fig. 2c:** Four different diameter trephines. **Fig. 2d:** Two-piece trephine bur. **Fig. 2e:** The bone core can be easily retrieved after removal of the coronal part of the trephine.



implant bed by a constant supply of coolant.^{9,16} Intermittent operation is also recommended to allow better irrigation. The two-piece trephine bur allows easy removal of the bone core from the cylinder of the trephine bur. If the bone core remains in the area of the bone harvesting site, it is removed using a special bone core elevator (Meisinger; Fig. 3c).

Surgical procedure

Perioperative antibiotic therapy with penicillin 1,000,000 IU is administered, either intravenously immediately before the local anaesthesia or orally one hour before surgery, to be continued postoperatively for one week at a maintenance dose of $3 \times 1,000,000$ IU/day, depending on the extent of the augmentation site. In patients with a confirmed allergy to penicillin, clindamycin is given at a daily dose of 1.2 g. Following lingual/palatal and buccal infiltration with the local anaesthetic (4% articaine, 1:100,000 epinephrine), the bone surface including the defect is exposed by raising a full-thickness mucoperiosteal flap.

The morphology of the defect is then analysed. Implant placement with simultaneous bone grafting is only indicated if all implant threads can be placed within the bone envelope. The bone contour is determined by the bone height and the positions of the adjacent teeth and the placement of the implant site. All implant threads should be positioned at least 1 mm inside the bony envelope⁹—this is important for vascularisation of the bone graft and osseointegration of the implant. Therefore reason, wide sockets (Fig. 3a) are a good indication for the bone core technique, regardless of the extent of the bone defect.

After selecting the appropriate trephine bur for the selected implant diameter, the centre of the bone at the selected implant position is punch-marked with an appropriate pre-trephine. In the molar region, this mark should be placed in the septum area; in the anterior or premolar region, it should be slightly offset palatally to obtain a maximum of bone material. The trephine is then inserted over the punch mark to the desired depth to harvest the bone core (Fig. 3b).

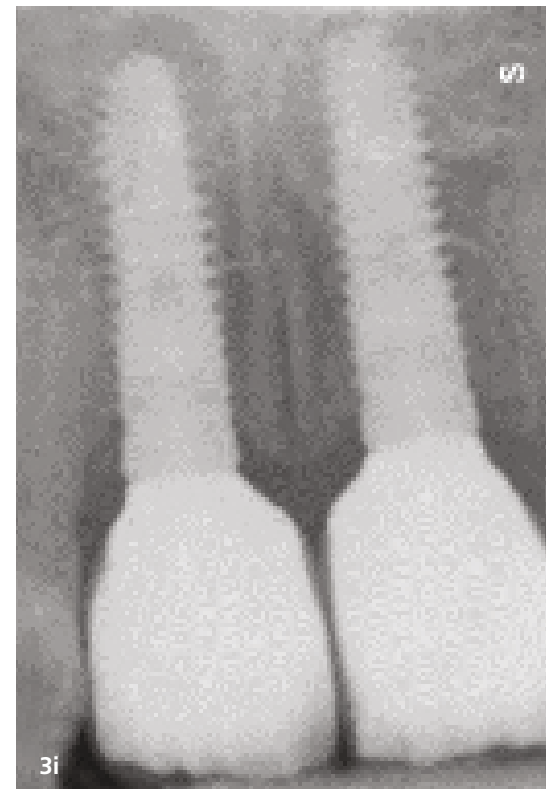
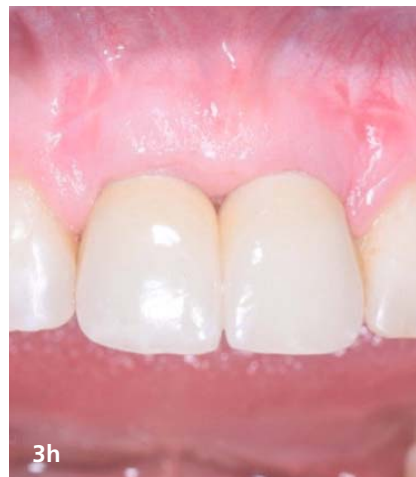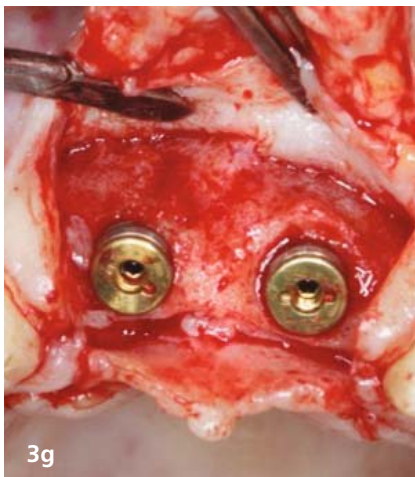


Fig. 3a: Absence of the vestibular bone wall at site 11 with a small bone defect at site 21. A pre-trephine is used to punch-mark site 21. **Fig. 3b:** The trephine bur with stable guidance thanks to the central punch mark. **Fig. 3c:** If the bone core is still attached to the bone, it can be easily removed using the bone core elevator. **Fig. 3d:** Defect situation after placement of implants 21 and 11 with exposed implant threads within the alveolar ridge envelope. **Fig. 3e:** The bone cores. **Fig. 3f:** The harvested bone cores were compressed against the implant surface with two microosteosynthesis screws each to restore the vestibular bone walls. The remaining defects were filled with the autologous bone chips. **Fig. 3g:** Clinical situation at three months. The bone defects have completely regenerated. **Fig. 3h:** Clinical situation at one year after definitive restoration. **Fig. 3i:** Control radiograph at one year.

Once the bone has been removed, the implant bed is carefully expanded to the desired depth and diameter. The implants are then placed within the bone envelope (Fig. 3d). As the diameter of the initial trephine should be smaller than the implant diameter, additional autologous bone chips can be harvested at low speed without irrigation. The bone core is usually compressed and stabilised against the implant using two microscrews (1.0 or 1.2 mm diameter; Meisinger; Fig. 3e). The screws must apply compression only through the screw head to secure the bone core in place without penetrating it. In some cases, multiple bone cores from different prepared implant beds may be used to augment a larger defect (Fig. 3f).

If sufficient bone chips cannot be obtained for augmentation during implant bed preparation, it is recommended to obtain additional local bone chips using a bone scraper. After tension-free wound closure, the site is re-entered after only three months. A full-thickness flap is elevated is used to clinically visualize the completely regenerated bone (Fig. 3g). The prosthetic restoration can be initiated simultaneously (Figs. 3h & i).

Guided by the morphology of the defect and the remaining bone walls, bone is harvested with the trephine close to the still intact bone wall, but taking into account the prosthetic plan, occlusion, and any pronounced undercut areas. In the maxilla, a bone core removal is usually harvested palatally because, on the one hand, the bone defects are usually located in the area of the vestibular bone wall and, on the other hand, this allows the implant threads to remain within the jaw contours.

Depending on the defect situation, the bone core harvested with this minimally invasive method can successfully regenerate significant bone defects with long-term stability⁹ and provide a high level of function and aesthetics with appropriate soft-tissue management. The bone core technique is also suitable for incomplete regeneration after extensive augmentation using the shell technique. Depending on the regenerative capacity of the recipient region, incompletely regenerated areas can be re-augmented three months after augmentation by harvesting a bone core during implant placement.

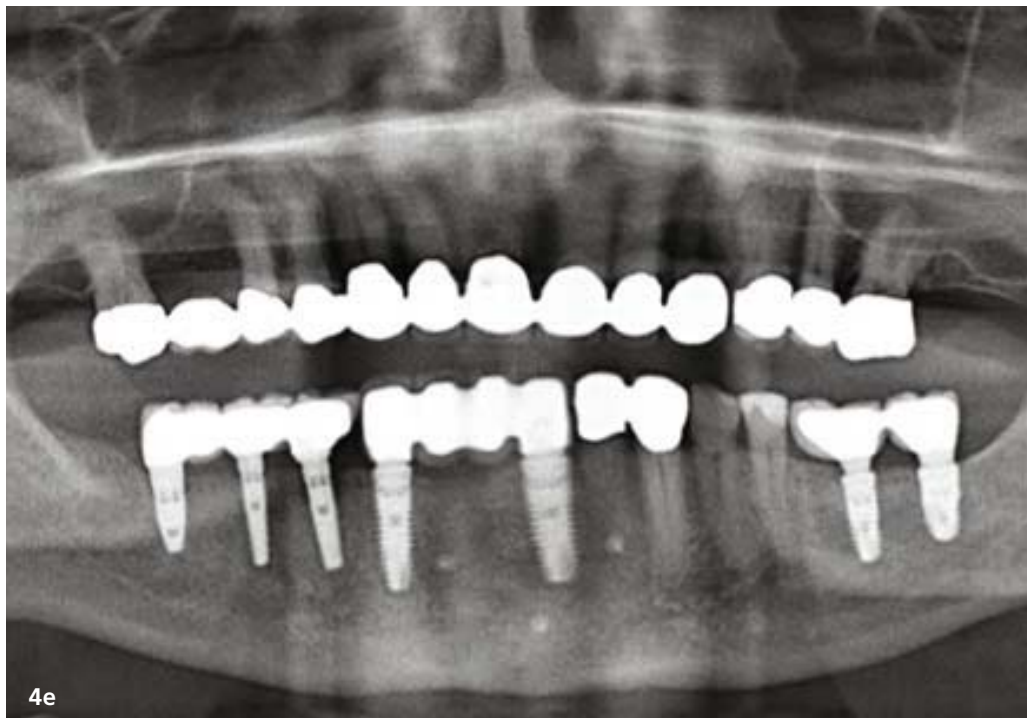
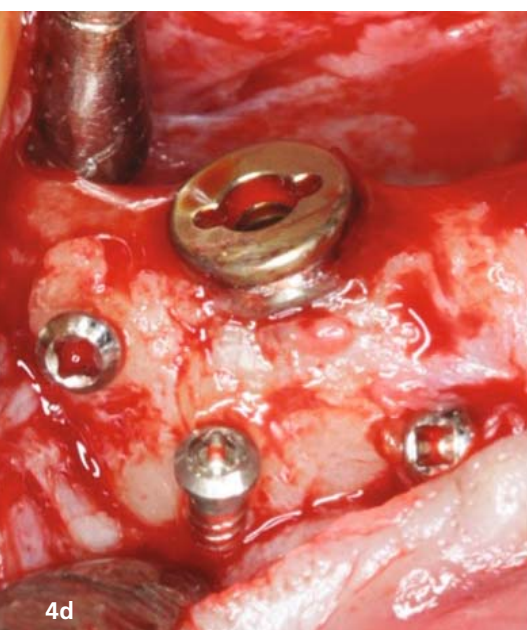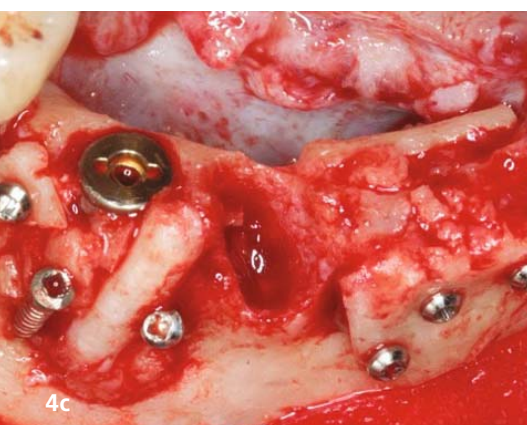
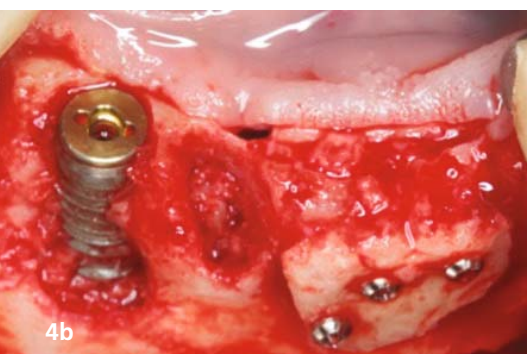
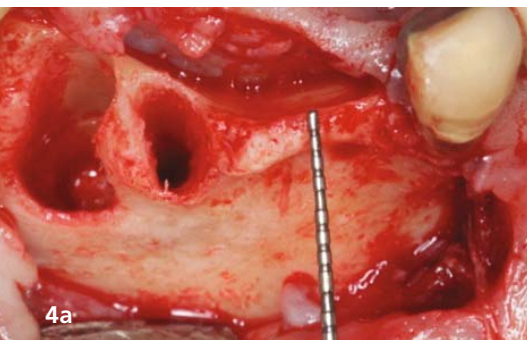


Fig. 4a: Non-ossified extraction site 43 and 2 mm of narrow alveolar ridge at site 31. **Fig. 4b:** Implant placement with exposed threads within the bone envelope at site 43 and simultaneous three-dimensional augmentation using the shell technique at site 31-32 by harvesting bone blocks from the chin region. **Fig. 4c:** Augmentation at site 43 using bone cores. **Fig. 4d:** The former bone defect is completely regenerated. **Fig. 4e:** Panorama radiograph after delivery of the final restoration.

Discussion

Various techniques and materials can be used to augment and reconstruct alveolar ridge defects. Clinical relevance depends on an overall surgical approach, supported by the use of techniques appropriate to the defect constellation.

Autologous bone is still the gold standard because of its biological advantages in different defect sizes, especially for extensive horizontal or vertical bone augmentation. Vital osteocytes and osteoblasts express bone morphogenetic proteins (BMPs) and stimulate the formation of mesenchymal stem cells, which in turn differentiate into osteoblasts and serve as initiators of regeneration.^{9,18}

The shell technique with mandibular bone grafts (split bone block technique) is a proven autologous augmentation technique for the reconstruction of vertical and lateral defects. However, the shell technique requires a second surgical site. For smaller bone defects, a less invasive

solution using autologous bone is preferred.^{15,19-21} In the bone core technique, depending on the defect morphology, the bone required for lateral and vertical augmentation can be harvested by primary trephine drilling from the area of the implant bed alone. The bone mass removed during the preparation of the implant bed is therefore not lost, but effectively utilised and then secured in the form of a drill core in its position at the recipient site with microosteosynthesis screws.⁹

A key advantage is that the use of autologous bone eliminates the need for membranes or bone substitutes from other sources, significantly reducing the risk of postoperative infection due to membrane exposure. Non-resorbable membranes are more susceptible to early exposure because of their reduced adhesion to surrounding tissue and are therefore often a source of contamination.^{9,13}

The regenerative capacity of the autologous graft depends largely on the method

of harvesting and the donor site.^{22,23} Minimally invasive harvesting of a bone core in the bone marrow region is characterised by a thin, comparatively small cortical portion and a larger portion of cancellous bone.²⁴ This type of bone favours rapid revascularisation and is characterised by a high cellular content, increased differentiation capacity with formation of mineralised tissue and high expression of osteoinductive proteins (BMP-2 and VEGF).^{25,26}

A prospective five-year study using the carrot technique in 186 patients with 223 augmented sites showed not only a high success rate but also long-term stability of the primary result.² Only 1.4% of treated patients (all smokers) showed minor post-operative complications, such as premature exposure of the implant cover screw, microosteosynthesis screws or parts of the bone core (< 2 mm). Considering the data published in the literature, the complication rate of the bone core technique is significantly lower compared to other augmentation techniques.^{27–30}

In addition, the prospective study showed low bone resorption at augmentation sites within the bone envelope at the time of implant re-entry. Low resorption was observed in portions of the bone core that were located outside the bone envelope (Figs. 4a–e). The average width of the augmented area was 2.4 ± 0.8 mm at the end of surgery and 2.1 ± 0.6 mm at the time of re-entry at three months. Similar results were observed with the shell technique or bone splitting.^{9,15,31} Radiological control examinations, including conebeam computed tomography (CBCT), showed stable peri-implant bone conditions during observation periods of between five and eight years, which is in line with the clinical results described above. No implant was lost over the entire observation period.²

Although the presented method is a good and feasible technique for the treatment of limited bone defects, complications may still arise due to bone overheating with the trephine bur in bone with a high percentage of cortical tissue, resulting in symptoms “burned-bone syndrome”.¹⁶

In the present study, such radiological findings were seen in two patients and successfully treated using a bony lid approach and removal of apical granulation tissue.²

Conclusion

The bone core technique is suitable for minimally invasive augmentation of specific bone defects using locally harvested bone. Gentle handling of the two-part trephine and the harvested bone core is

essential for successful treatment with this technique. The bone core technique is cost- and time-efficient for both the patient and the surgeon and is characterised by its excellent biological and immunological competence. As an augmentation technique that is easy to integrate into daily practice, it offers low complication rates in addition to reduced treatment time and, in combination with adequate soft-tissue management, shows long-term stable results even in aesthetically demanding areas.



Literature



Prof. Dr Khoury



Dr Zastera, M.Sc.



Contact address

Prof. Dr Fouad Khoury

Privatklinik Schloss Schellenstein
Am Schellenstein 1
59939 Olsberg, Germany
prof.khoury@t-online.de

Dr Alexander Zastera, M.Sc.

Senior Oral Surgeon
Am Schellenstein 1
55939 Olsberg, Germany
AlexanderZastera@outlook.com

A retrospective study

Extra-short single-tooth implants rehabilitated using single-tooth transepithelial with a crown-to-implant ratio 2

Dr Eduardo Anitua DDS, Spain

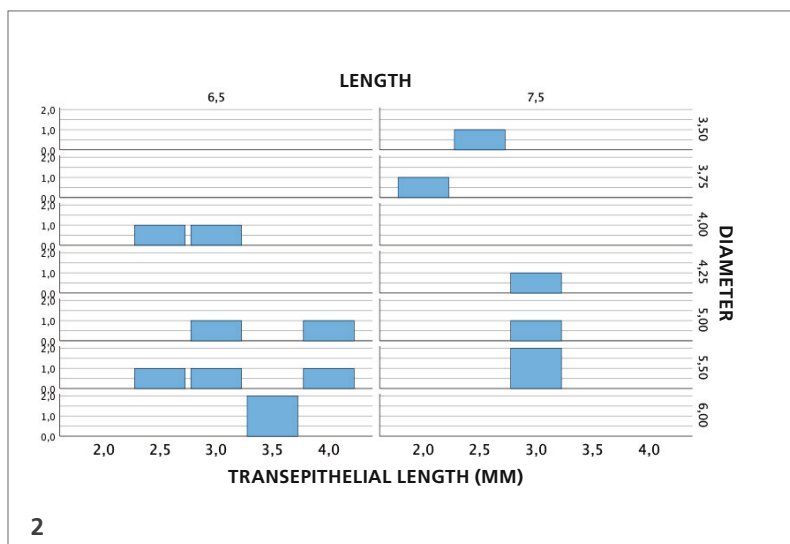
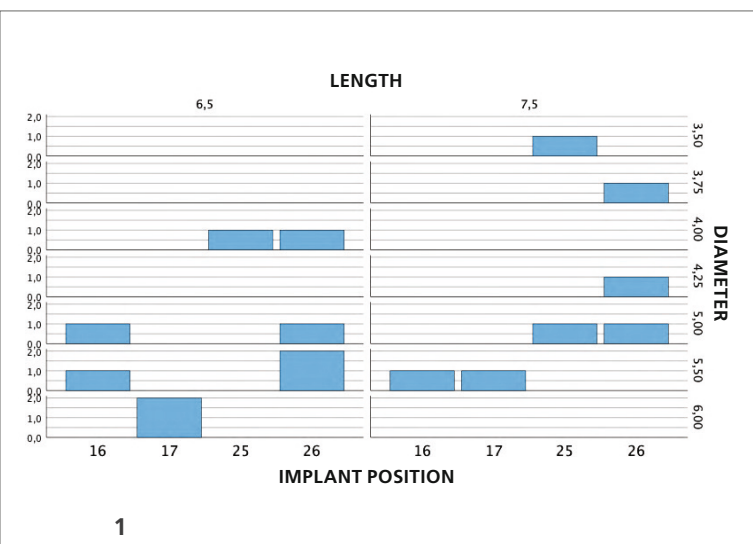
Nowadays, we can rehabilitate the majority of cases that come to our practice requesting a type of treatment using dental implants. This is mainly due to major advances in implant design, which have enabled implants of smaller length or diameter to be adapted to any clinical situation, and to improve regenerative surgical techniques for those situations where they are necessary.^{1,2}

Short and extra-short implants are a highly predictable solution for vertical atrophies of both the maxilla and mandible, with current survival rates of 86.7 to 100%.^{3,4} In this type of atrophy, one of the main drawbacks that must be solved when carrying out subsequent rehabilitation is the disproportion generated between the prosthesis and the implants on which they sit, as the prosthetic space in these

situations is high and the proportion or ratio generated between the crown and the implant is often greater than 2. Theoretically, if we study the potential distribution of forces, a crown-to-implant ratio greater than 2 would represent a lever arm on an implant of reduced size to be considered, even more so when the force is going to be transmitted on a recently inserted implant. In splinted implants, it

has been repeatedly demonstrated that this ratio, however unfavourable it may be, does not generate greater bone loss on the implants or a higher failure rate.⁵⁻⁷

Short and extra-short single implants, for the resolution of localised vertical atrophies, are also subsidiaries for carrying a prosthesis with a crown/implant disproportion of sometimes more than 2. In these cases, there are studies that analyse



the crestal bone loss of these implants with high cumulative survivals of 87, 95.7 and 96.6% respectively.^{8–11} In most of the studies that consider this type of unitary rehabilitation, the possible repercussions of the presence of an intermediate element in the prosthesis, such as the unitary transepithelial, are not considered. In most cases, these are direct-to-implant prostheses, where the seal between the prosthesis and the implant may be compromised by the use of calcineable elements and the loss of hermeticity at this level.^{12–20} This loss of seal may lead to a higher incidence of peri-implantitis and therefore the survival data of these study groups may be influenced by this factor, especially in cases of lever arm crown-to-implant ratios greater than 2, where a gap can easily open in the implant-prosthesis connection, especially in lateral load.¹³

In the present case series, we show a group of patients rehabilitated with short and extra-short implants (6.5 and 7.5 mm), treated as a unit using a screw-retained prosthesis and unitary transepithelial, all of them with a crown-to-implant ratio greater than 2. In them, implant survival and crestal bone loss will be evaluated as well as the influence of the use of unitary transepithelial.

Methods

We retrospectively reviewed the medical records of patients who underwent in-

sertion of 6.5 and 7.5 mm long implants with screw-retained unitary rehabilitation using transepithelial from May 2014 to December 2015, so that the implants could be followed up after loading for at least five years. Data were collected in a data collection notebook for subsequent statistical analysis, the main study variables being: bone height gain and implant survival.

All patients were studied before implant insertion by means of diagnostic models, intra-oral exploration and dental CT (cone-beam) subsequently analysed by means of specific software (BTI-Scan II). Prior to implant insertion, antibiotic premedication consisted of amoxicillin 2g orally 1 hour before surgery and paracetamol 1g orally (as an analgesic). Subsequently, patients were treated with amoxicillin 500–750 mg orally every 8 hours (according to weight) for 5 days.

The implants were placed by the same surgeon, using the biological drilling technique, at low revolutions, without irrigation.^{21–22}

Control visits were scheduled for suture removal and for the control of possible adverse events from implant insertion to the time of the second surgical phase (five to six months).

Once the treatment was completed (implant loading), a visit was scheduled after six months, followed by an annual follow-up visit to check the stability of the implant.

Statistical analysis

The main variable studied was implant survival. Secondary variables studied were crestal bone stability, prosthetic complications and prosthesis survival.

The patient was the unit of measurement for the analysis of age, sex and medical history.

A Shapiro-Wilk test was performed on the data obtained to verify the normal distribution of the sample.

Qualitative variables were described by frequency analysis. Quantitative variables were described by means of mean and standard deviation. Implant survival was calculated using the Kaplan-Meier method. All analyses were performed with SPSS v15.0 (SPSS) and the significance level was set at 5% ($p < 0.05$).

Results

Sixteen patients were recruited who met the previously established selection criteria. Of the patients, 42.9% were female, with a mean age of 54.19 ± 13.6 years (range 32 to 77 years). The most frequently rehabilitated tooth was tooth 26 in 43.8% of cases, followed by tooth 16, 17 and 25 with the same percentage for each, 18.8%. The predominant diameter of the patients studied was 5.50 mm (31.3%) followed by 5 mm (25%). The length was divided between 56.3% for 6.5 mm implants and the rest (43.8%) for

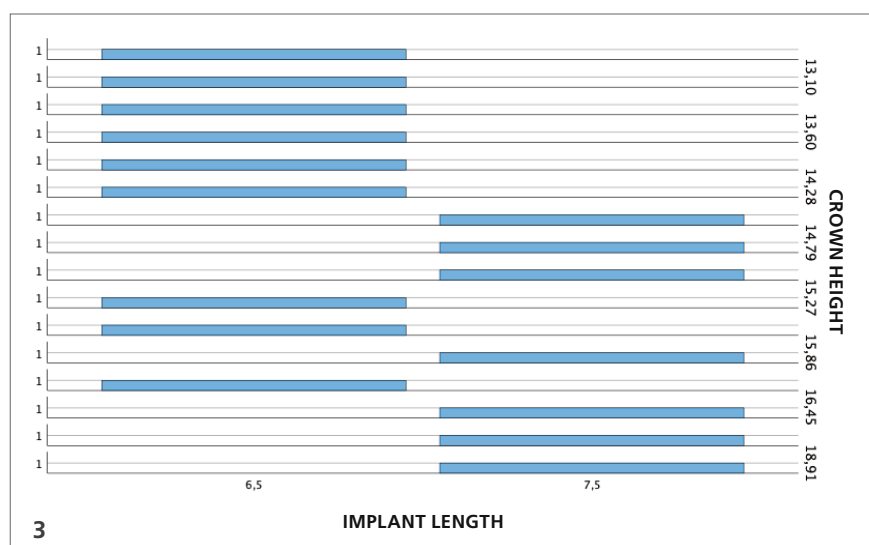


Fig. 1: Implants included in the study with their diameter and length according to their location.

Fig. 2: Unit transepithelial height as a function of implant diameter and lengths. **Fig. 3:** Crown height as a function of the length of the implants included in the study.

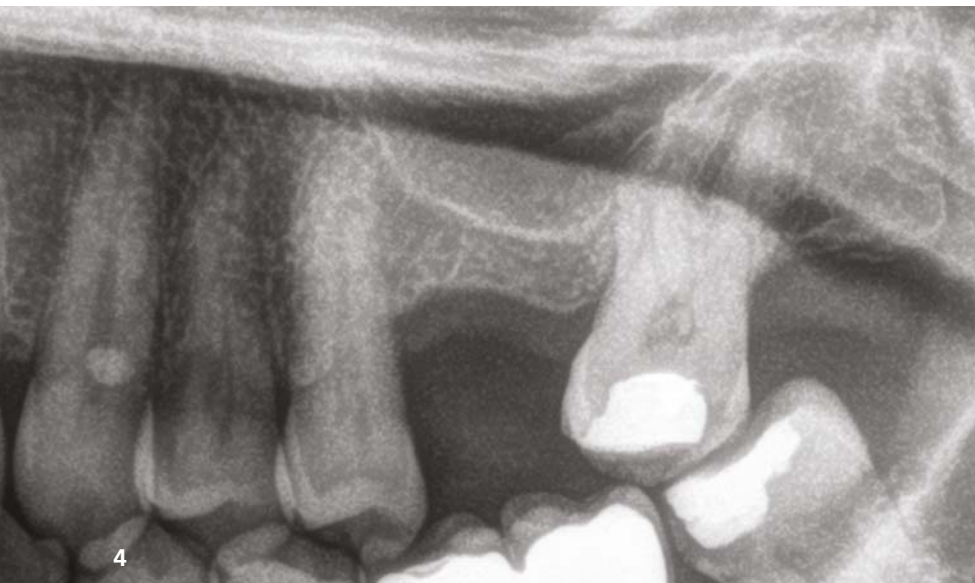

Fig. 4: Initial X-ray of the patient showing the edentulous section of the second quadrant to be rehabilitated with a short single implant.

7.5 mm implants. The implants included in the study with their diameters and lengths, according to their insertion position, are shown in Figure 1.

The mean insertion torque of the implants included in the study was $45.9 \text{ Ncm} \pm 7.1$ (range 35–65 Ncm). The main bone type where the implants were inserted was type III (550 Hu) in 25% of the cases. All implants were loaded in two surgical

phases, at five months in the upper arch and at three months in the mandible. The prostheses used were metal-ceramic screw-retained unitary transepithelial prostheses. The most frequently used unit height was 3 mm (43.8%), followed by 2.5 mm (18.8%). The remaining transepithelial heights are shown in Figure 2. The crown height of the implants studied ranged from 13.1 to 18.9 mm. The differ-

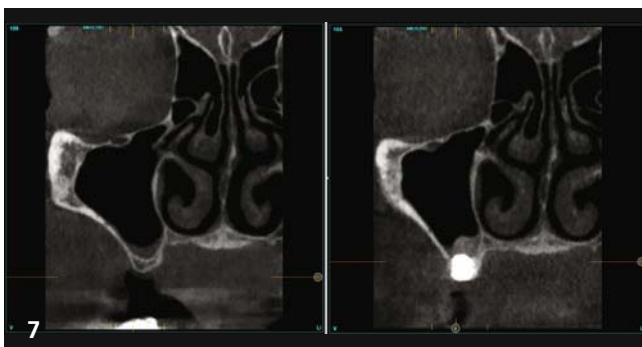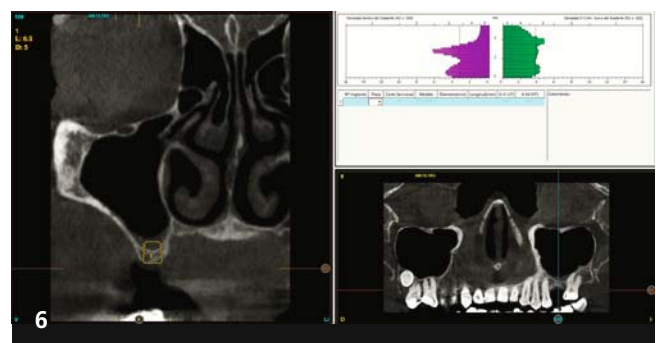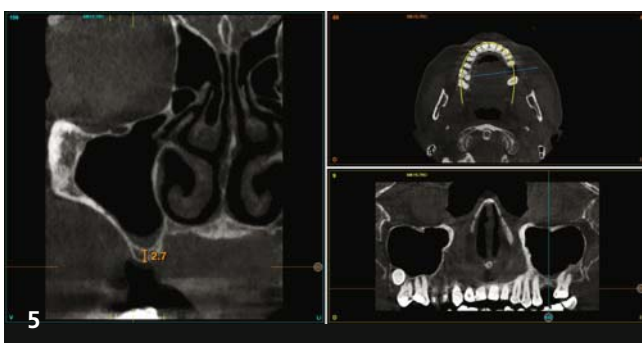ent crown lengths as a function of implant length are shown in Figure 3.

None of the implants included in the study failed during the mean follow-up time of 46.6 months (± 22.5). The mean mesial bone loss for all implants studied was 0.31 mm (± 0.51) and the mean distal bone loss was 0.33 mm (± 0.85). When mesial and distal bone loss was studied as a function of crown height, there was no statistically significant relationship ($p=0.875/ p=1.500$ respectively) and no statistically significant relationship between unit height and bone loss in either of the two bone loss estimates (mesial $p=0.980/$ distal $p=0.888$). A correlation was made between crown and transepithelial height and mesial and distal bone loss, and no significance was found between any of the parameters studied at any of the points.

Figures 4–9 show one of the cases included in the study.

Discussion

Short and extra-short implants of 6.5 and 7.5 mm, such as those reported in the present study, are safe and predictable alternatives in dentistry today, as they have been postulated as a therapeutic



Figs. 5 & 6: Planning images of the diagnostic cone-beam showing the residual bone volume and the planned implant, in this case 6.5 mm. **Fig. 7:** Control CT image before and after implant insertion surgery at six months, with correct integration of the implant in place.

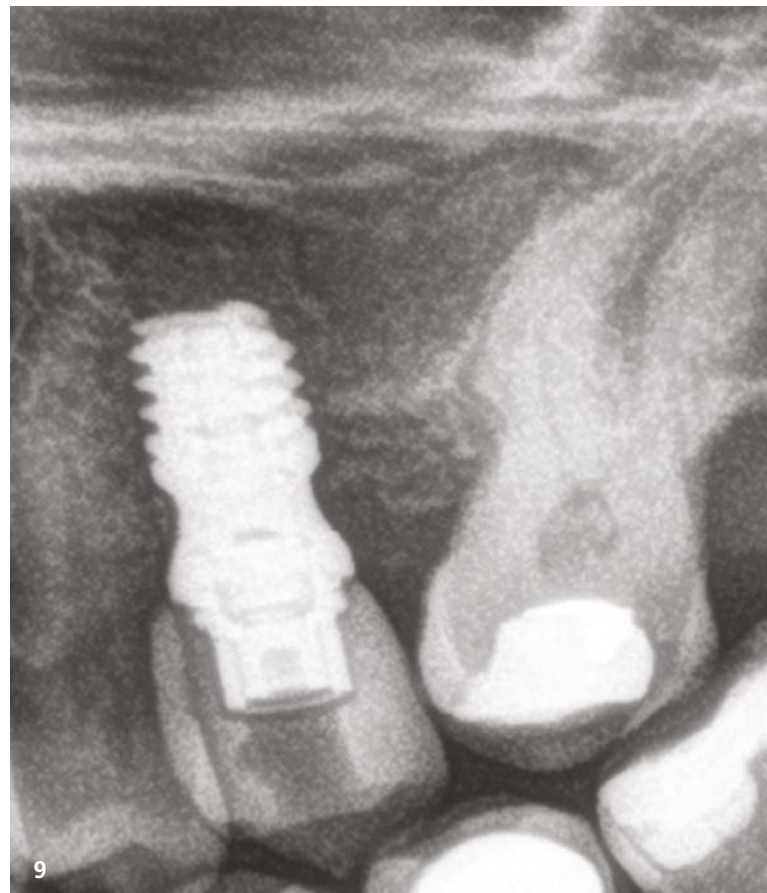
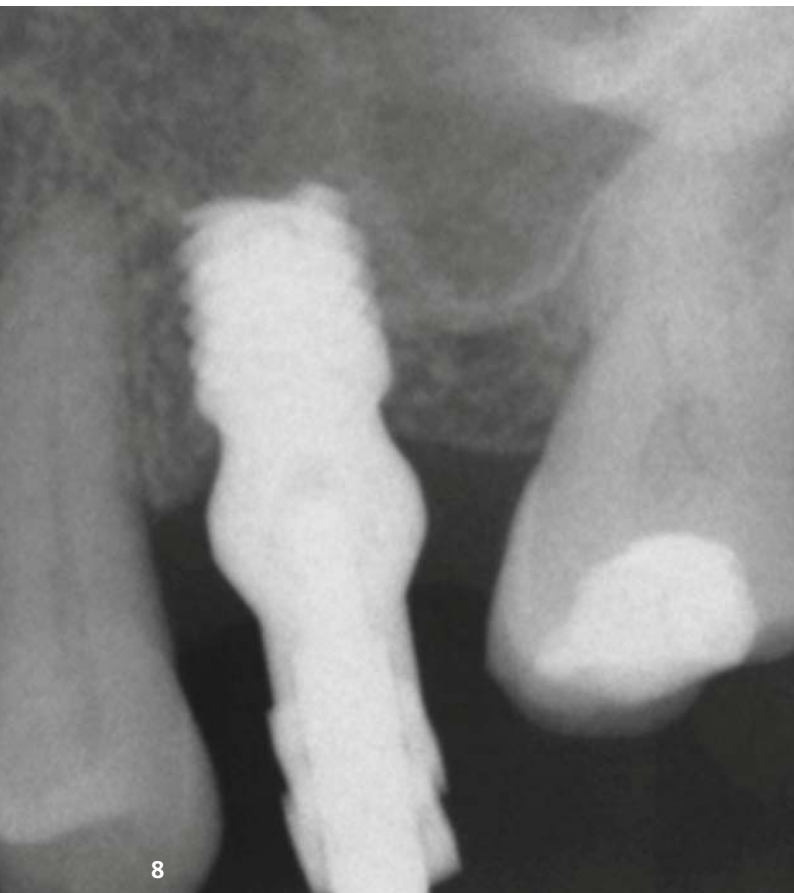

Fig. 8: Impression of the implant with the unitary transepithelial, in this case expanded, to achieve a better adaptation of the soft tissues with this emergence profile in the making of the prosthesis. **Fig. 9:** X-ray two years after placement of the definitive prosthesis. The stability of the treatment can be seen.

option with fewer biological complications, lower economic cost and fewer surgical sessions for patients.^{8,20–23} The reported long-term survival rate of these implants is 98.9%, which is similar to that of longer implants placed without bone augmentation or those inserted in augmented bone using different procedures.^{4,24}

In the patients studied, no higher bone loss rate has been reported for short or extra-short implants with a lower crown-to-implant ratio, where losses of 0.4–0.5 mm with one year of follow-up or $1.25 \text{ mm} \pm 0.99 \text{ mm}$ with three years of follow-up have been reported.^{8–10,11}

The height of the transepithelial, as an intermediate element between the prosthesis and the implant, has had no transcendence in the quantification of crestal bone loss, in any of its lengths, so that, like the height of the crown, it has not been a risk factor that increases crestal

bone loss after loading, at least in the group of patients studied and in the time during which the follow-up has been carried out. The presence of transepithelial, on the other hand, according to the work published by our study group, may have a beneficial relationship for the whole, as it generates a better distribution of the load in the bone bed as well as achieving better sealing of the prosthesis.^{13–16,18}

Conclusions

Implants 6.5 and 7.5 mm in length, rehabilitated with an unfavourable crown-to-implant ratio do not present an increased risk of failure or crestal bone loss, according to the data provided by the present case series. However, a larger number of studies analysing this topic in depth, with larger samples and a longer follow-up time are needed to confirm these conclusions.



Contact address

Dr Eduardo Anitua

Eduardo Anitua Foundation

José Maria Cagigal 19, Vitoria, Spain

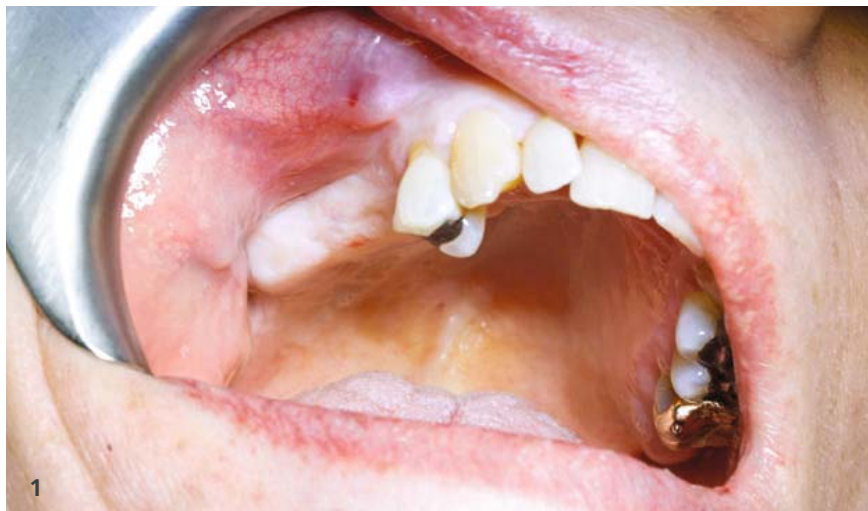+34 945 160653

eduardo@fundacioneduardoanitua.org

Screw-retained restoration of upper right first molar and second premolar

Dr Anthony Bendkowski, UK

In the following case report the intended screw-retained restorations was successfully achieved by using the DS OmniTaper Implant System to restore both the upper right first molar as well as the second premolar. This case report is published as an inspiration for clinicians or technicians, not necessarily as a recommendation from Dentsply Sirona.



Introduction

The 64-year-old female patient already had a heavily restored dentition. She had recently lost the upper right first molar and second premolar, leaving an unbounded edentulous area. An implant solution was provided using two individual screw-retained crowns supported by two OmniTaper EV implants (Dentsply Sirona) and using a digital workflow using Prime-scan and Atlantis.

The failing upper right second premolar and first molar had already been ex-

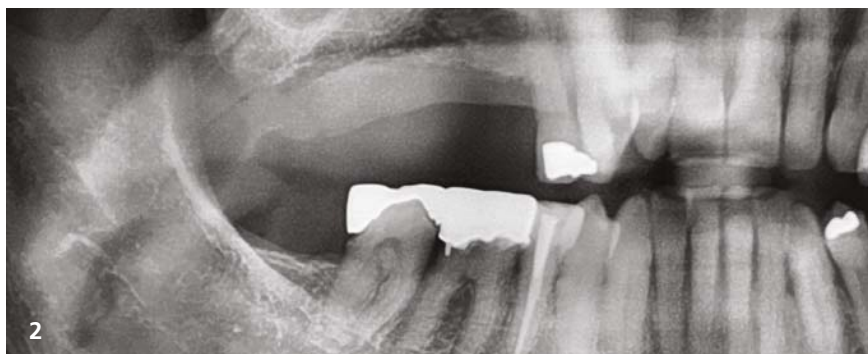

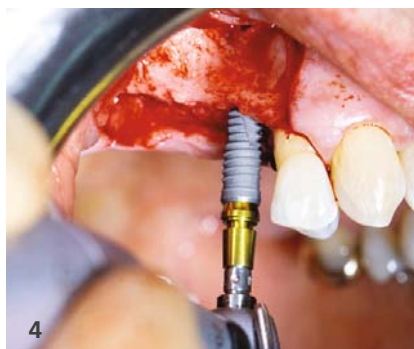
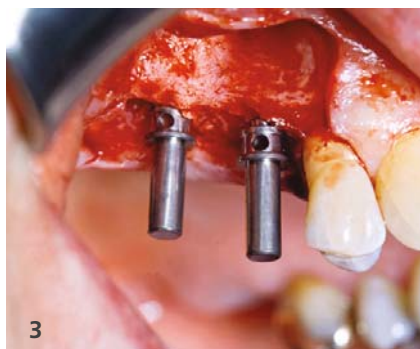Fig. 1: The failing upper right second premolar and first molar extracted prior to implant treatment.

Fig. 2: Radiographic assessment: ample bone depth in posterior maxilla. **Fig. 3:** Full thickness envelope flap and Direction Indicators in situ. **Fig. 4:** Installation of an OmniTaper EV Ø 3.8 x 11 mm implant in tooth #4 (FDI 15) position using the TempBase Driver. **Fig. 5:** Both OmniTaper EV implants placed with the help of the pre-assembled TempBase abutments.

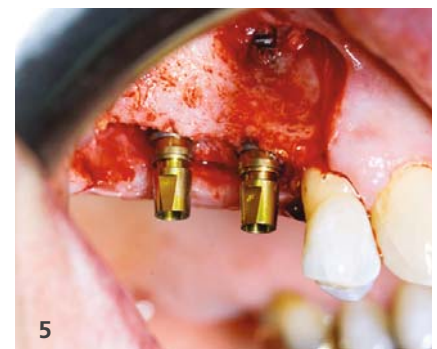

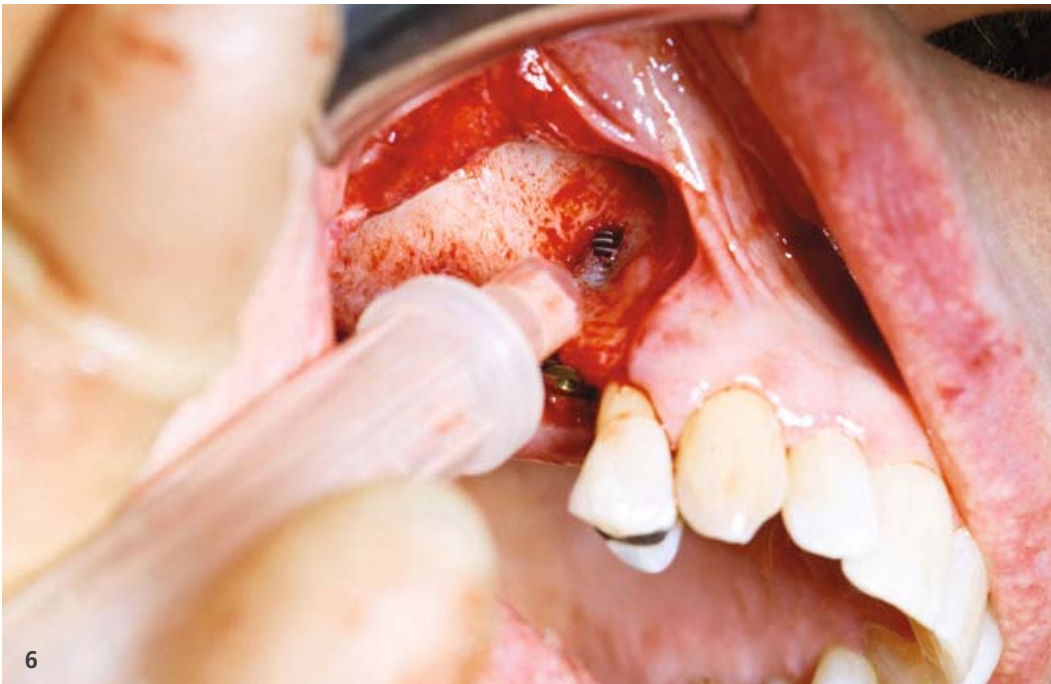


Fig. 6: Use of Dentsply Sirona disposable BoneTrap to augment the small bone fenestration.

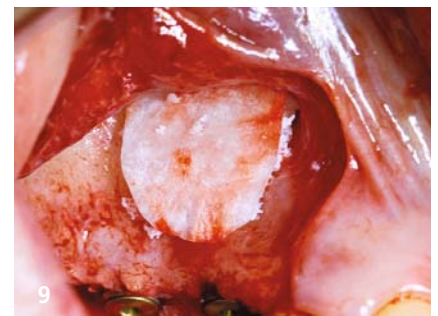
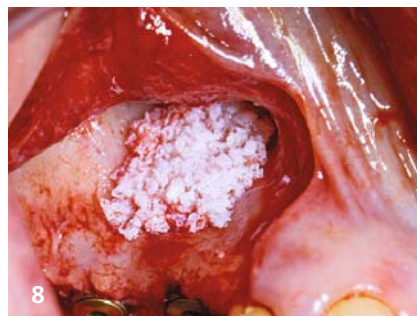
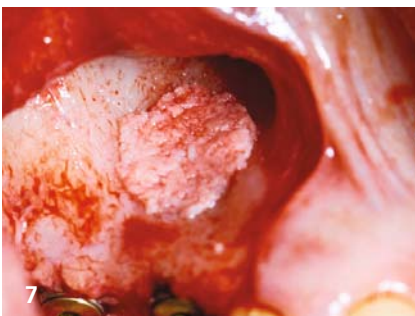


Fig. 7: Large quantity of autogenous bone collected from the BoneTrap. **Fig. 8:** Symbios Xenograft Granules layered over autogenous bone. **Fig. 9:** Symbios collagen membrane SR 15 x 20 trimmed to shape.

tracted by the patient's general dental practitioner prior to the planned implant treatment (Fig. 1). The radiographic assessment indicated that there was ample bone depth available in the posterior maxilla to allow for a satisfactory implant placement (Fig. 2).

Prosthetic procedure

After an initial preparation with an OmniTaper drill of 2.0 diameter a full thickness envelope flap was achieved, and direction indicators placed (Fig. 3). In the following an OmniTaper EV (\varnothing 3.8 x 11 mm)

implant was installed and nicely aligned in both tooth #4 (FDI 15) and #3 (FDI 16) positions using the TempBase Driver (Figs. 4 & 5) with the help of the pre-assembled TempBase abutments. The implant-abutment connection size was medium (M) as indicated by the yellow colour in Figure 5.

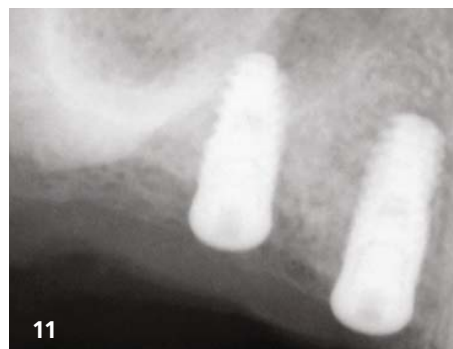
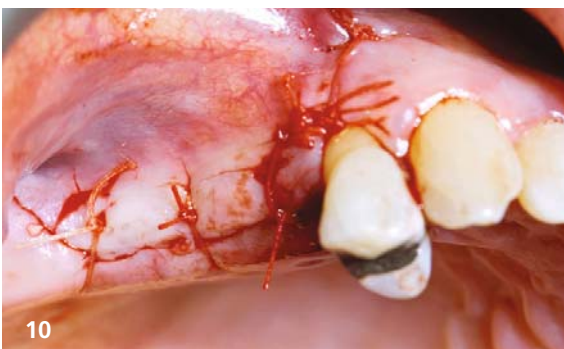
Fig. 10: Passive primary closure with PGA sutures.

Fig. 11: Radiograph of implants postoperatively.

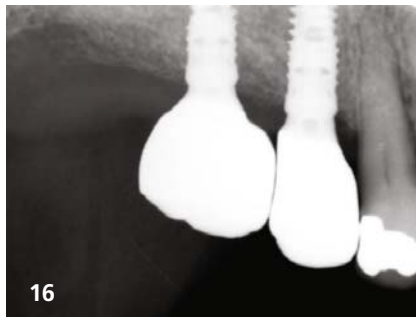
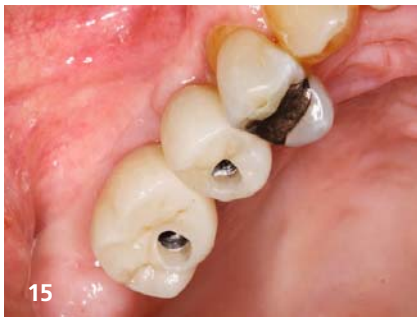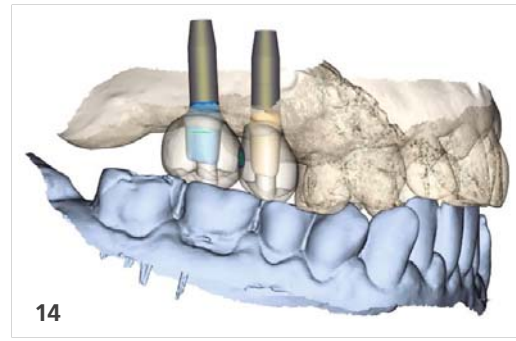

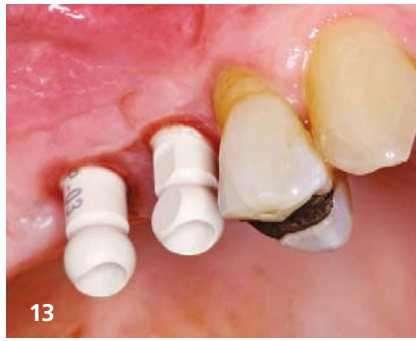
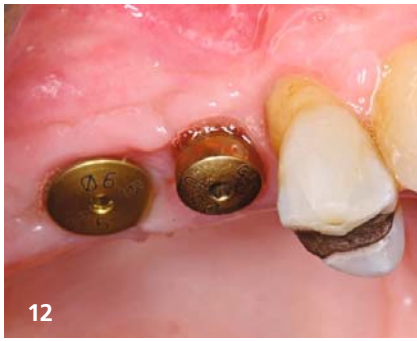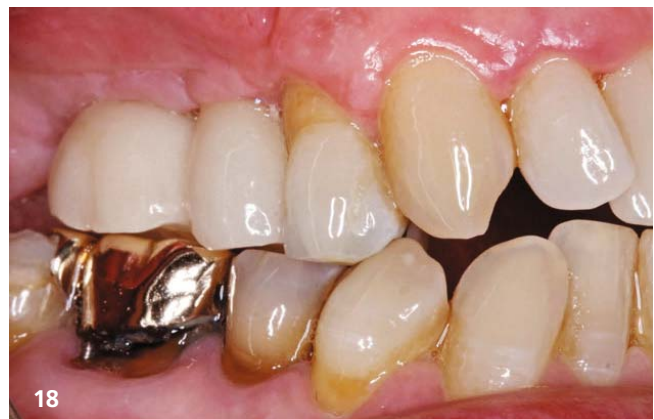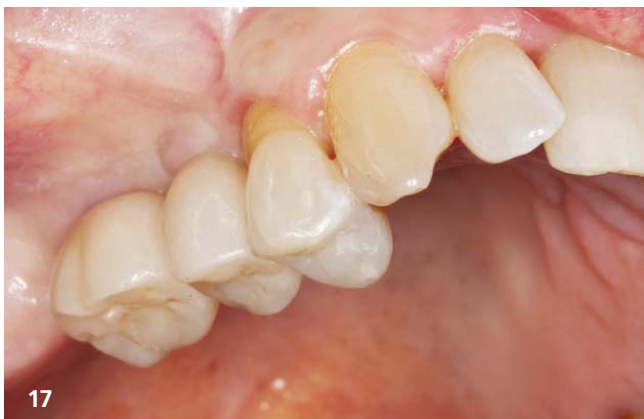Fig. 12: Healing Abutment EV (M) placed after three months. **Fig. 13:** Atlantis IO FLO *in situ* ready for Primescan digital impression. **Fig. 14:** Design of Atlantis abutments and zirconia crowns. **Fig. 15:** Well-fitting screw-retained Atlantis CustomBase abutments and zirconia crowns. **Fig. 16:** Radiograph to verify correct seating of restorations. **Fig. 17:** Screw-access channels sealed and amalgam tooth position #5 (FDI 14) replaced with composite. **Fig. 18:** Final restorations completed.



The small bone fenestration was then augmented by using the Dentsply Sirona disposable BoneTrap (Fig. 6) and a large quantity of autogenous bone collected (Fig. 7).

In the next step Symbios Xenograft granules were layered over the autogenous bone and a Symbios collagen membrane (SR 15 x 20) was trimmed to shape to complete the guided bone regeneration procedure (Figs. 8 & 9). A passive primary closure was achieved with polyglycolic acid (PGA) sutures (Figs. 10 & 11).

Three months after the initial surgery healing abutments (M) were placed (Fig. 12). Next the Atlantis IO FLO were placed to complete the Primescan digital impression in order to achieve the planned

design of the Atlantis abutments and zirconia crowns (Figs. 13 & 14). A Radiograph to verify the correct seating of the restorations was taken following the process and showed well-fitting screw-retained Atlantis CustomBase abutments and zirconia crowns (Figs. 15 & 16). As no adjustments were necessary the screw-access channels could be sealed and the amalgam tooth position #5 (FDI 14) was replaced with composite (Figs. 17 & 18).



Contact address

Dr Anthony Bendkowski
Oral Surgeon
Private Practice
Maidstone, Kent, UK



Dentsply Sirona

Implant Solutions World Summit 2023—cutting-edge implant science and innovation

Dental professionals join world-leading experts in implant dentistry for this exclusive, state-of-the-art congress in Athens, Greece, on 8–10 June. Together, they will discover cutting-edge science, the latest innovations in digital dentistry, bone regeneration, and optimised implant treatment solutions, including EV implant family, for their patients—and enjoy the company of colleagues and friends from around the world.

The Implant Solutions World Summit brings together professionals who are passionate about elevating the dental industry and improving the quality of implant treatments and care for patients. The congress will take place at the InterContinental Athenaeum Athens hotel, close to Greece's famous Acropolis.

Scientific programme

The Implant Solutions World Summit will feature presentations from more than 40 world-renowned experts in implant dentistry, who will share best practices, expertise, and insights. Dental professionals will learn about managing implant complications, the connections between systemic and oral health, maximising aesthetics, controlling risk factors, maintaining peri-implant health, and more.

The programme is developed together with the Scientific Chairs—Dr Tara Aghaloo, USA, and Dr Michael Norton, UK—and the Programme Chairs—Steve Campbell, UK; Dr Malene Hallund, Denmark; Dr Mark Ludlow, USA; Dr Stijn Vervaeke, Belgium; and Dr Martin Wanendeya, UK.

“Peer-to-peer education is vitally important for our implant solutions community, and we are thrilled to bring implant professionals together from around the world to explore the latest innovations and science transforming implant dentistry” says Tony Susino, Vice President, Global Implant Solutions at Dentsply Sirona. “The event promises to be an inspirational opportunity for learning and networking as we glimpse into the future of implant dentistry and optimised patient care.”



Dentsply Sirona

www.dentsplysirona.com/worldsummit



Innovative implant solutions and digital workflows

The Implant Solutions World Summit 2023, will also feature an interactive exhibition and sign up for exciting master class workshops to learn more about Dentsply Sirona's products, solutions, and workflows, including Dentsply Sirona's premium implant portfolio—DS Prime-Taper Implant System, DS Omni-Taper Implant System and Astra Tech Implant System—OSSIX regenerative solutions, DS Signature Workflows for single-tooth, partial and full-arch restorations, the cloud-based DS Core platform for improved practice efficiency, and practice building.

The innovative, comprehensive implant solutions portfolio from Dentsply Sirona is designed to help practices grow their implant dentistry business and get the best results for their patients.

International Osteology Symposium

27-29 APRIL 2023
BARCELONA

International Osteology Symposium Barcelona 2023

The expert meeting for oral tissue regeneration

The 2023 edition of the International Osteology Symposium will be taking place in Barcelona from 27 to 29 April. As the only global organisation specialising in the field of hard and soft tissue management the foundation will offer an impressive programme of 80 lectures, 14 workshops, two live surgeries and many other formats, all held by world-leading experts in the field of oral regeneration. The event motto "WE ARE RE:GENERATION" reflects the foundation's main focus on oral regeneration, and at the same time its mission to link science with practice, by gathering all the globally available knowledge—in one place at the same time.

Seven reasons to attend

Oral regeneration is your passion and investing in continuing education is important to you? Then you should consider the following seven reasons why to attend the International Osteology Symposium in Barcelona. "There is nothing more inspiring than a great conference to bring that motivation back into your daily practice on a Monday morning", says Ronald E. Jung, member of the Osteology Foundation Board.

1. Be up to date and learn from the best: In Barcelona, the world's experts in oral tissue regeneration will meet, share knowledge and exchange ideas. Learn about the latest research results, new practices and emerging technologies and standards. Bringing this knowledge into your daily practice will improve your clinical results for sure.

2. Sharpen your surgical skills: 14 workshops will be offered alongside the symposium programme. Choose one of these hands-on workshops and refine your skills through practice and feedback. Learning the right surgical procedure step-by-step from an expert will improve your daily work.

3. Meet experts face to face: Leading experts will gather in Barcelona on and off stage and will be accessible to participants. Take the opportunity for personal exchange and leave a lasting impression. We all know that careers, collaborations and friendships can emerge from chance encounters.

4. Explore different career options: The promotion of the next generations is close to the hearts of many of the renowned experts—whether in research or clinical practice. Take the chance to connect with them and learn from their experience.

5. Gain new perspectives: The symposium will cover all aspects of oral regeneration and also address perspectives on

related disciplines. Become inspired by the whole conference package and maybe it will guide you to new horizons in the world of oral tissue regeneration.

6. Osteology is the place to be in oral regeneration: We are the only global specialist organisation in the field of oral-tissue regeneration. There is nothing like being in a room of like-minded people and taking that energy back to your workplace. Be part of the community and connect with your peers from near and far.

7. Have fun: Enjoy three days of learning in a pleasant atmosphere with exciting formats, like live surgeries, clinical roundtables and battles of concepts. Do not miss the opportunity to combine meeting your educational needs with inspiration and fun.

All information on the programme, workshops, case competition and poster exhibitions as well as registration is available at osteology-barcelona.org.



Osteology Foundation

Landenbergstrasse 35
6002 Lucerne, Switzerland
+41 41 3684444
www.osteology-barcelona.com

OSSTEM IMPLANT

Digital dentistry trends: OSSTEM World Meeting in Istanbul

After the successful OSSTEM World Meeting in Tokyo, Japan, in 2019 OSSTEM IMPLANT is delighted to hold its next World Meeting in Istanbul, Türkiye, on 12 and 13 May 2023. This year's symposium will show how fast digital dentistry has evolved during the pandemics.

The event will start with practical hands-on courses where attendees can experience how easy and convenient it is to use OSSTEM products. Due to the limited number of seats available preregistration is a must. On the second day, eight lectures focusing on the most recent development in digital dentistry will be presented by renowned speakers including Dr David Chong (USA) and Prof. Darko Božić (Croatia).

A live surgery, the highlight of the symposium, will be performed in South Korea, where the headquarters of OSSTEM



IMPLANT are located, and will be livestreamed directly to Istanbul.

On Friday evening the "OSSTEM World Night", a spectacular gala dinner, will offer a great opportunity for networking with fellow dentists from all over the world in a pleasant atmosphere, accompanied by delicious traditional meals and surprising entertainment and performance.

The whole symposium will be livestreamed through its own online platform—DenAll, with translation into several languages. For the last symposium more than 40,000 dentists from all over the world were connected online.

OSSTEM IMPLANT
<https://en.osstem.com/>

ITI International Team for Implantology

All about the patient: The ITI World Symposium 2024

The ITI World Symposium is back and better than ever: More than 50 world renowned speakers will present at the world's largest scientific implant dentistry event in Singapore from 9 to 11 May 2024. Building on its previous highly successful online edition, the ITI World Symposium 2024 once again puts patients at the centre of the action. Over three days, the more than 4,000 participants will experience real patients and their stories on stage. The speakers will discuss various treatment options based on the latest scientific evidence. But it does not stop there: world class clinicians will provide commentary on exclusively recorded clinical procedures live on stage.

"With our unique, patient-centred programme structure, we aim to combine practical, clinical insights with the discussion of scientific findings", explains ITI president Charlotte Stilwell. "We ran a survey in our community last year to identify the topics of currently greatest relevance, and these form the core of our scientific programme: soft tissue management, GBR/bone augmentation, immediate implants, peri-implantitis and the digital workflow."

Registration for the ITI World Symposium opens early April.

ITI members as well as early registrations will benefit from significant discounts.

ITI International Team for Implantology
www.worldsymposium.iti.org



Oral Reconstruction Global Symposium 2023 | 18–20 May 2023 | Rome, Italy

Quo vadis Implant Dentistry— The future of dental implantology

The Oral Reconstruction (OR) Global Symposium, themed "Quo Vadis Implant Dentistry", will be held 18–20 May 2023, in Rome, with more than 30 world-renowned speakers who will address the future of implant dentistry and dental tissue regeneration. Numerous practical details about proven and new clinical therapeutic approaches will be discussed during the event.

With the OR Global Symposium in Rome, the OR Foundation is building a bridge to traditional international congresses. Elected last year, OR Foundation President Dr Luca Cordaro also serves as Congress Chair. Together with the scientific committee, Prof. Juan Blanco (Spain), Prof. Dehua Li (China), Prof. Michael Stimmelmayer (Germany), Prof. Irena Sailer (Switzerland), Prof. Anton Sculean (Switzerland) and Dr Homa Zahed (USA), more than 30 world-renowned speakers have been recruited to share their knowledge and experience

in a practical way. Together they will present a differentiated and groundbreaking programme aimed at dental professionals from all areas of dental oral reconstruction.

A must on the dental agenda

The OR Foundation's mission is to drive progress for the benefit of patients, from cutting-edge education to research and the world's most exclusive network of specialists in oral reconstruction. "Our goal is to enable the continuous improvement

of treatment through close collaboration with universities, dentists and industry, via the sharing of expertise and presentation of research results, especially at our symposia," said Dr Martin Schuler, Executive Director of the OR Foundation.

The programme will start the morning of Thursday, 18 May 2023, with five practical and two theoretical workshops. Participants will learn a variety of techniques that can be incorporated into their daily practice. The afternoon is dedicated to the pre-symposium titled "Technological innovation helps the clinic". The pre-symposium with renowned speakers is included in the participation fee.

The main programme on Friday and Saturday is divided into eight sessions. One session will discuss different options for hard and soft tissue augmentation, including Guided Bone Regeneration with blocks, shells, or computer-assisted bone augmentation. The speakers will examine topics related to the ability to affect bone and soft tissue healing around implants and review options in the treatment of gingival recession. Another focus is on the use of autologous bone or allogeneic, xenogeneic, or synthetic bone graft substitutes, membranes, and soft tissue matrices. The questions of when is the right time for implant placement and what are the advantages of digitisation will be discussed, as well as prosthetic solutions for older, or even edentulous patients.



The board members of the OR Foundation: President Luca Cordaro, Irena Sailer, Mariano Sanz, and Executive Director Martin Schuler (from left to right).



The Oral Reconstruction International Symposium in October 2022 in Munich was a packed event, with a full audience in attendance. On stage, Dr Ilaria Franchini from Stuttgart was presenting.

The Research Award and the poster exhibition

Young researchers whose studies are supported by the OR Foundation will present their latest findings in a dedicated session on the main podium on the morning of Saturday, 20 May 2023. The best researcher will be awarded the OR Foundation Research Award. In addition, dentists are encouraged to submit their abstracts for the poster exhibition by 5 March 2023. The best abstracts will be presented on Friday afternoon on the main stage during a science slam. Participants whose posters have been accepted will have their registration fee waived.

Participants from all over the world in the Auditorium Parco della Musica

Participants from all over the world are expected to attend the OR Global Symposium in Rome. The congress language is English, and the lectures will be simultaneously translated into German, French, Italian, Japanese and Spanish. With its sights, Rome, whose historic center is a UNESCO World Heritage Site, is a "global city", and for thousands of years, it was

the center of one of the greatest civilizations.

The Auditorium Parco della Musica, where the congress will be held, is located just outside the city. For the weekend, this venue, reminiscent of Roman architecture, will become a multicultural meeting and exchange place for interested dental professionals.

The symposium is supported by Bio-Horizons and Camlog, founding sponsors of the OR Foundation.

For information on the programme or to register, please visit:
<https://symposium2023.orfoundation.org/>



Dr Frederic Hermann from Switzerland presented his extraordinary case to the scientific committee of the Oral Reconstruction International Symposium, led by Dr Gerhard Iglhaut (second from left) and Prof. Mariano Sanz (right).

Contact address

Sonja Mumenthaler

sonja.mumenthaler@orfoundation.org

Oral Reconstruction Foundation
 Margarethenstrasse 38
 4053 Basel, Switzerland
 +41 61 5654151
www.orfoundation.org

Oral Reconstruction Foundation–US
 2300 Riverchase Center
 Birmingham, AL 35244, USA
 +1 205 986 7989
info.us@orfoundation.org

OSSTEM IMPLANT

New chapter as a scientific community

During its academic symposium in Rome from 28 to 29 October 2022 OSSTEM IMPLANT's Advanced Dental Implant Research and Education Center, also known as AIC Europe, officially revealed its new logo (Fig. 1) and announced its introduction to Europe starting in 2023.

The new OSSTEM IMPLANT Scientific Community

Now renamed into OSSTEM IMPLANT Scientific Community (OIC) it aims to maintain the legacy of AIC with its more than 20 years of history. The renaming demonstrates the company's clear ambitions to further focus on the development of its scientific community.

Since its foundation in 2000 OSSTEM AIC has established a professional and systematic education system for clinical education in implantology. About 100,000 dentists globally have completed courses in the past 22 years. Starting in 2023, OIC will be continuing the offered training of implant clinicians through global instructors with abundant clinical experience. OIC aims

to be a place where all dentists can share knowledge and learn about new trends in implantology on a global scale. More importantly, it will allow all its members—both students and clinicians—to actively participate in every aspect of the community.

One of the most important changes of the rebranding is setting the focus of the scientific community on research. Mem-

bers of all levels will be able to share and participate in research.

As Prof. Marco Tallarico, president of OIC Italy, stated: "Our scientific community is like a town square where you can meet and sharpen your skills. This is very important for improving your daily practice. The concept is, firstly, to stay up to date for the benefits of the patients, and then, in addition, to help support young dentists because they do not have sufficient support when they leave university. So, we can say that our community is a place where the clinician is not alone, but it is a place to share, in an open way, our plans, successes, solutions, training activities and everything else."



Fig. 1: The new logo.

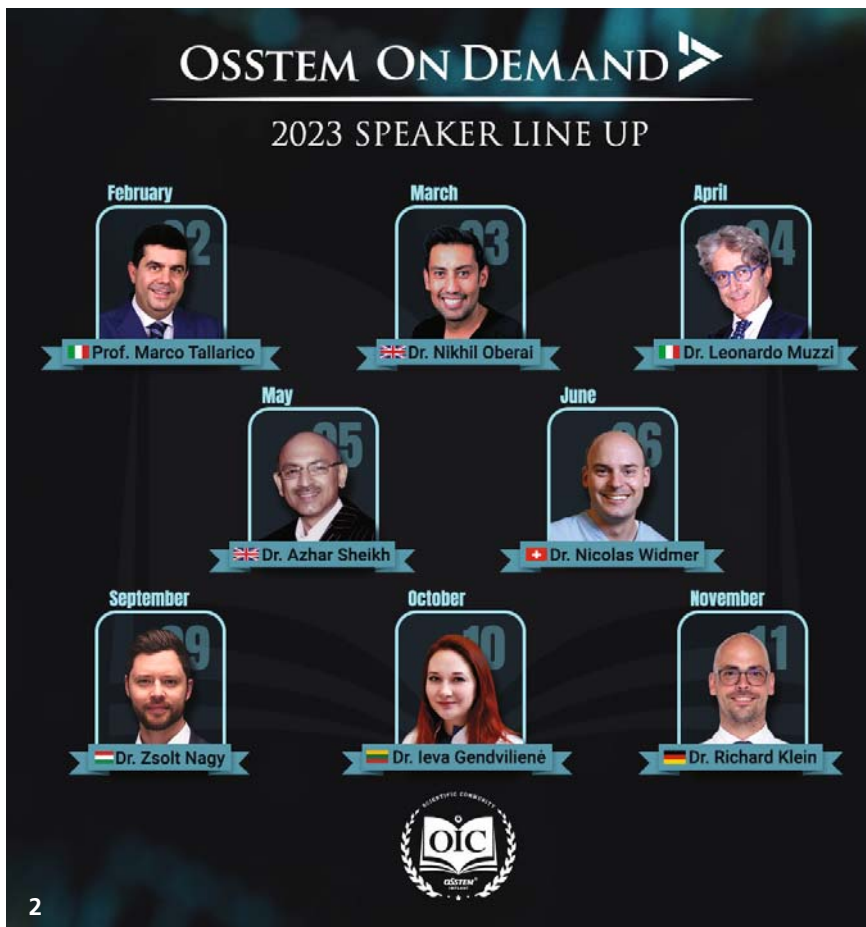

Fig. 2: The Osstem OnDemand renowned specialists for online lectures in 2023.

2023 speaker line-up for OSSTEM OnDemand

The scientific community has proven itself as a stable and significant provider of all kinds of education programmes including online learning. It has recently announced its 2023 speaker line-up for its video-on-demand lecture programme called OSSTEM OnDemand.

After having successfully offered online training and lectures for more than three years, the scientific community recently renamed into OIC will keep the dental community well informed, no matter where members are located globally.

Throughout 2023, a total of eight speakers will present lectures covering topics such as dental implantology, sinus grafting, narrow ridge reconstruction, aesthetics, and digital dentistry (Fig. 2). The main focus lies on continuing to work with renowned specialists as well as on giving a

chance to young professionals to show and share their knowledge within the scientific community.

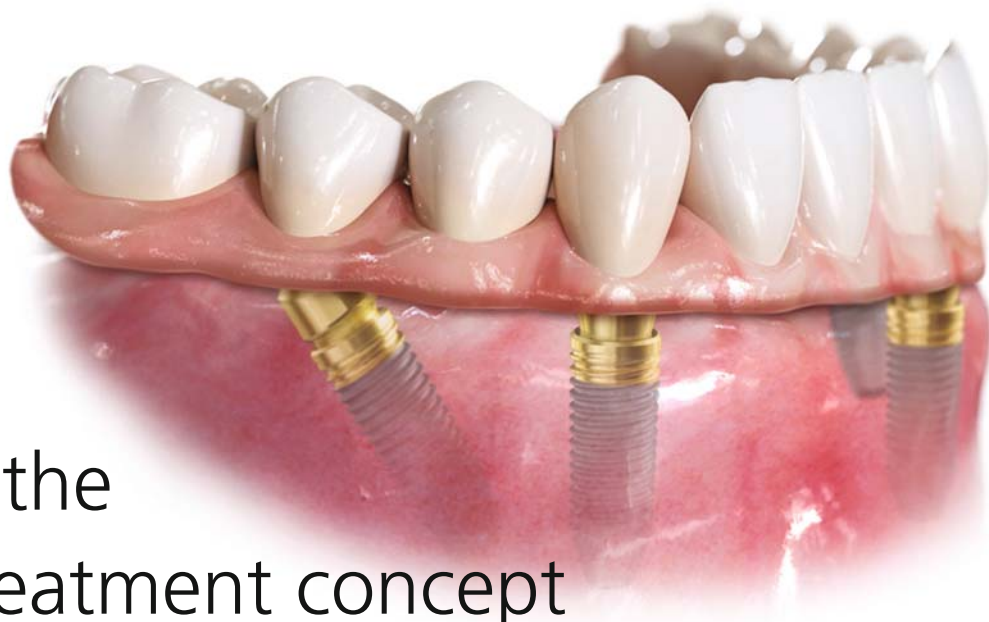
More than 50 lectures by European as well as global professionals have already been presented as part of the OSSTEM OnDemand seminar programme. On February 23, Prof. Marco Tallarico from the University of Sassari in Italy kicked-off the educational year with his lecture on "Treatment of Peri-Implant Defects using Titanium Mesh" (Fig. 3). Prof. Tallarico's presentation added to the impressive amount of informative and dynamic content already available for professionals desiring to learn new skills and techniques through the OIC.

Throughout the year, a new lecture will be released on every third Tuesday of each month. Dental professionals interested in receiving updates on new content available can register on the platform.

For more information, please visit: www.oic-europe.eu.

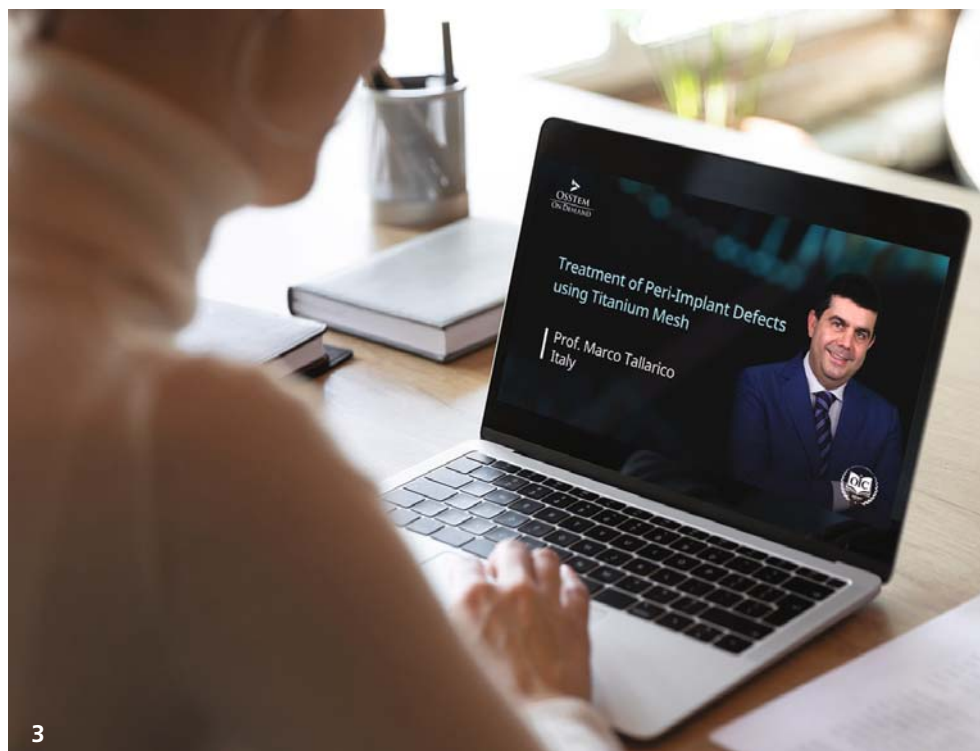

Fig. 3: Online lecture of Prof. Tallarico from the University of Sassari, Italy.



Nobel Biocare

25 years of the All-on-4® treatment concept

Dr Paulo Malo has been presented a Quarter Century Award from Nobel Biocare, honoring the twenty-fifth anniversary of the revolutionary All-on-4® treatment concept. At a gathering in Nobel Biocare's Dental Experience Center in Zurich, Switzerland, company President, Patrik Eriksson presented the trophy.



Patrik Eriksson, President of Nobel Biocare, presented the trophy to Dr Paulo Malo.

Dr Paulo Malo led the development of this treatment protocol in the early 1990s, with much-valued support from the late Dr Bo Rangert of Nobel Biocare. In 1998, he treated the first patient documented in the first scientific study¹, with the final version of the concept that became commercially launched.

The All-on-4® treatment concept is widely recognised as one of the most significant developments in implant dentistry. It brought a revolutionary way of providing patients with a cost-efficient, graftless solution for fixed full-arch prostheses on the day of surgery, on just four implants.

With edentulism estimated to affect over 350 million people globally², implant-supported restorations are recognised as one of the optimal treatment solutions.³ The All-on-4® treatment concept is one of the best-documented restorative solutions for

edentulous patients, proven to provide clinically successful long-term outcomes.^{4,5} Dr Malo said: "In the early years of the All-on-4® treatment concept, very few people believed that it was possible. But I was seeing firsthand how successful the technique was for my patients and became completely dedicated to making it available for more people who suffer from edentulism. Twenty-five years ago, it was beyond my wildest dreams that it would reach the scale that it has today."

He continued: "This level of impact is all thanks to Nobel Biocare. They could see its true potential despite skepticism in the industry, and they took it to a global level like no other company would."

Patrik Eriksson, President of Nobel Biocare said: "I'm delighted to award Dr Malo in recognition of this milestone. While many companies have tried to copy the All-on-4® treatment concept, Dr Malo and Nobel Biocare have focused on pushing the boundaries to improve the products and further develop the end-to-end workflow." He concluded: "Together, we continue taking the lead for the future of the All-on-4® treatment concept."

Throughout 2023 there will be a series of events to mark the 25th anniversary, including training courses, webinars and the continuation of the All-on-4® Center of Excellence programme, which awards practices that have distinguished experience in, and loyalty to, the genuine All-on-4® treatment concept.

Nobel Biocare

Literature



Nobel Biocare
AG Nobel Biocare Services
8058 Zürich-Flughafen
Switzerland

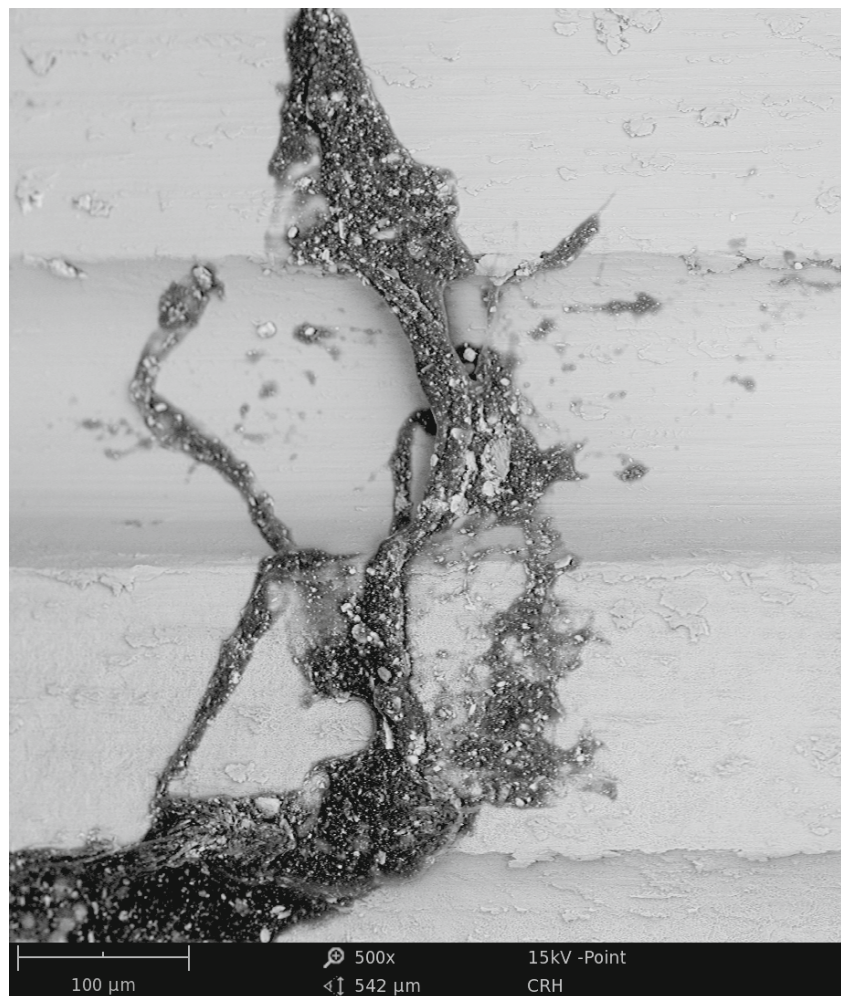
Implant contamination ex-factory— The widely underestimated risk factor for early implant failures

In the search for the causes of peri-implant bone loss, poor oral hygiene, smoking, pre-existing diseases, or existing periodontitis are often identified. A largely neglected factor that may influence an implant's short- and long-term survival is likely to be factory-related particulate and film-like contaminants on the sterile implant surface.

This is the conclusion of recent analyses by the non-profit CleanImplant Foundation. Elaborate SEM and ToF-SIMS analyses were performed at two independent, accredited testing laboratories on implant types sent to the CleanImplant Foundation for review by concerned dentists. These reported conspicuous early failures in individual implant systems. Sterile packaged samples of the same type then showed in the analyses, inter alia, significant contamination of the implant shoulder with so-called polysiloxanes. Residues of cell-toxic cleaning agents were also identified as a possible cause of implant losses.

Organic contaminants are associated in the literature with peri-implant bone loss and peri-implantitis.¹ Foreign bodies with a size of 0.2 to 7.2 μm are considered to be particularly pro-inflammatory.²⁻⁴ Macrophages take up the particles by phagocytosis if these detach from the surface during implant placement. Subsequently, activated macrophages release pro-inflammatory cytokines such as TNF- α , IL-1b, and IL-6. These not only stimulate the differentiation of osteoclast precursors into mature osteoclasts but also lead to the expression of matrix metalloproteinase (MMP-8).⁵ The result is an expanding zone of soft tissue damage and inflammation at the site of implant placement as well as peri-implant bone resorption.

At the IDS in Cologne, visitors can not only obtain information on the CleanImplant Foundation's quality assessment studies. A team of experts from the Foundation will be conducting analyses directly at the exhibition booth using a scanning electron microscope on-site. Interested visitors can bring sterile-packaged samples of their preferred implant system and attend the live quality assessment. Over the past few years, more than 300 implant systems have been examined for residues in the SEM, so the majority of systems are already recorded in the CleanImplant Foundation database. Dental trade show visitors can learn more in Hall 10.2, Booth O042.



Sterile packaged implant with significant organic contaminants (SEM 500x).

References



Corresponding author

Dr Dirk U. Duddeck

CleanImplant Foundation
Founder and Head of Research
duddeck@cleanimplant.org

Oral tissue regeneration is undergoing a paradigm shift right now

The Osteology Foundation marks its 20th anniversary this year. This jubilee will be celebrated at the International Osteology Symposium in Barcelona from 27–29 April 2023. To mark the occasion, we spoke in advance with Christer Dahlin, President of the Osteology Foundation Board and Professor in Oral Surgery and Guided Tissue Regeneration at the Department of Biomaterials Science at the Sahlgrenska University of Gothenburg, Sweden, about the Foundation's beginnings and its impressive path to becoming a global specialist organisation in the field of oral tissue regeneration.

Professor Dahlin, can you take a brief look back in time and tell us when oral tissue regeneration began as a discipline?

Let me start with the beginnings of implant dentistry, as implantology and oral tissue regeneration complement one another as disciplines. For me, the era of implantology began with the pioneering work of the late Per-Ingvar Brånemark from Gothenburg. He operated on the very first patient in 1965, and from 1977 implantology was officially recognised as a treatment concept. In 1982, George Sorb invited all universities from America and Canada to a congress in Toronto, where the Gothenburg

group could present its work. This meeting launched the world-wide spread of implantology. At the same time, André Schröder was working on similar ideas in Switzerland. He had a slightly different philosophy, because Switzerland was and still is number one when it comes to orthopaedic medical devices. The developments took place concurrently, but I would say that the big push and the more structured approach to implant development took place in Gothenburg.

In the mid-1980s, interest in the regeneration of oral tissue grew, as often insufficient bone volume made implant treatment impossible. So, people began to look for new techniques that went beyond traditional bone grafting.

Guided bone and tissue regeneration (GBR and GTR) were the revolutionary treatment concepts that catapulted oral tissue regeneration into the highest disciplinary ranks of dentistry. You have had a significant pioneering role in the development of these treatment concepts. Can you give us more details about the beginnings?

It all started with guided tissue regeneration and the need for better periodontal treatment. At that time, the realistic treatment goal of periodontal disease was to halt progression. In the late 1970s and early 1980s, Thorkild Karring from the University of Aarhus and Sture Nyman from the University of Gothenburg explored different reconstructive approaches using barrier membranes to achieve periodontal reattachment.

As a very young dentist, I attended a postgraduate course with Sture Nyman. I was immediately excited about this biological concept, which I thought must also be applicable to other indications such as bone defects. A few weeks later, I mustered up the courage to call him and convinced him to meet with me and discuss the issue further. Long story short, I travelled to Gothenburg and became his PhD student. Our first experimental study on rats published in 1988 showed the regenerative effect on bone defects. We then wanted to know if it was possible to regenerate bone around dental implants as well and did the first experimental study to demonstrate this, published in



1989. This major publication demonstrated the regenerative effect of oral tissues around teeth and implants. And I was lucky enough to be able to formulate my PhD project from my own thoughts. That was a blessing.

Later, Sture Nyman also moved to Bern to work with Klaus Lang and Daniel Buser. In Gothenburg we did basic research to understand the underlying biology. The first clinical case was then conducted and published in Bern by Daniel Buser and Sture Nyman.

At that time, oral tissue regeneration supported implant dentistry in its growth, but nowadays there's a paradigm shift.

It is a paradigm shift! Thanks to the significant rise of implant treatment within dentistry, oral tissue regeneration has evolved strongly in recent decades. In the future, this area is set to become even more important through the paradigm shift in implant dentistry: what was originally function-oriented intervention has, on top of this, become treatment with high aesthetic standards and minimal invasiveness as a prerequisite. Nowadays, effective techniques of oral tissue regeneration enable implants to be placed correctly from a prosthetic point of view, even in suboptimal bone conditions and despite gingival deficits. Implant dentistry has become more of what it should be: Namely a prosthetically-driven treatment method that focuses on the tooth or the final restoration. Oral tissue regeneration and guided bone regeneration have proven to be very useful in optimising medium to small-size defects instead of doing more invasive surgery with bone grafts.

In this sense, oral tissue regeneration has perhaps been a booster or catalyst for implant treatment, making it a more aesthetically oriented procedure.

Oral regeneration has always developed in parallel with implantology, but now that the trend is back to preserving a tooth as long as possible, it has, in a way, emancipated itself from implantology. What does this mean for research and education, the two pillars of the Osteology Foundation?

Bone regeneration has been the focus of research for decades and is now practised at a correspondingly high level. And for quite some time, it was considered that soft tissue simply follows the bone. This is true to a certain extent, but we also see great potential in optimising soft tissue independently. We can look forward to decisive progress in this area in the coming years. The research for gaining specific evidence is on-going and will provide clinicians in the future with valuable guidelines.

Another trend is the increased use of sophisticated tissue regeneration techniques in tooth preservation. This is also where the

Osteology Foundation comes into play: this organisation is a true specialist in oral tissue regeneration, covering all relevant indications from hard and soft-tissue management to the biologisation of regeneration as well as interdisciplinary regenerative approaches. As such a specialist, we strive to accompany these trends, be it with implant-oriented or tooth-preserving procedures.

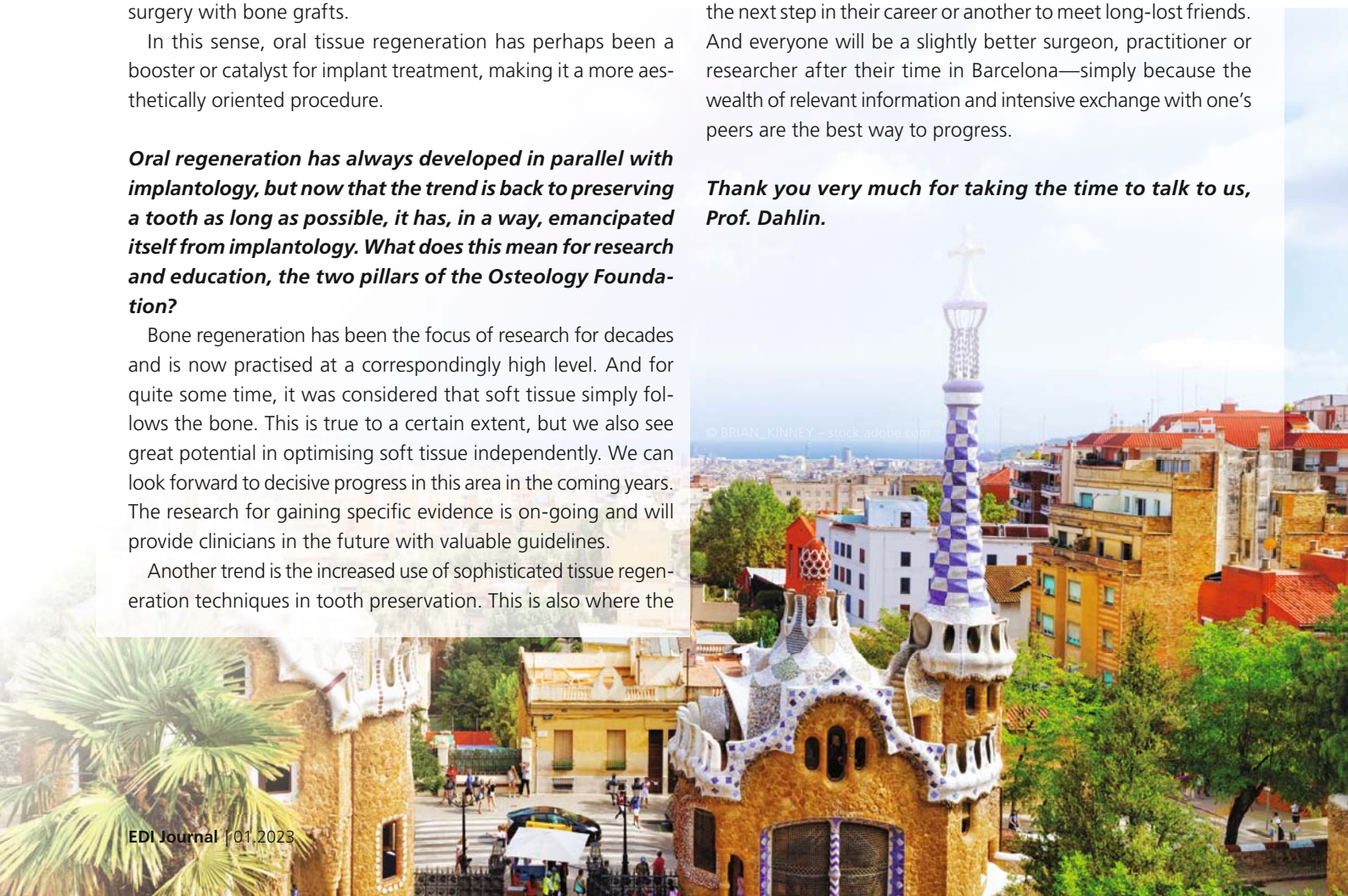
To this end, the Osteology Foundation offers a finely balanced system of research funding and training opportunities at every level and in many countries around the world

The Osteology Foundation will mark its 20th anniversary this year. Will there be any celebrations?

The Osteology Foundation is celebrating its 20th anniversary in 2023 with the absolute highlight of the year: the International Osteology Symposium, held 27–29 April in Barcelona. Thanks to its longstanding presence, the organisation can look back on an eventful history and has supported oral tissue regeneration virtually since its beginnings as a discipline. The symposium will provide relevant theoretical and practical knowledge to all interested parties, from the student to the general practitioner to the experienced specialist. This event is a unique opportunity for a deep dive into the exciting world of regeneration: the most renowned experts worldwide will share their knowledge through a multitude of lectures and hands-on workshops. For young and established specialists alike, Barcelona is the place to be this April.

For sure, the unique networking at the International Osteology Symposium for three days can enable one participant to take the next step in their career or another to meet long-lost friends. And everyone will be a slightly better surgeon, practitioner or researcher after their time in Barcelona—simply because the wealth of relevant information and intensive exchange with one's peers are the best way to progress.

Thank you very much for taking the time to talk to us, Prof. Dahlin.



B. Braun

The PTFE suture for happy smiles

B. Braun has extended its wide dental product portfolio: with Elasyne it now offers a non-absorbable suture material made of polytetrafluorethylene (PTFE/teflon) which due to its characteristics is especially valuable for wound closure in oral and maxillofacial surgery. The smooth

surface and its suppleness improve both handling and patient comfort.

More product advantages: In comparison to braided standard sutures Elasyne offers a low bacterial adhesion. Elasyne will currently be offered in ten different needle-thread-combinations.

During the International Dental Show—the international trade fair of the dental industry, which will be held in Cologne from 14–18 March—B. Braun will be presenting the product in Germany for the first time (Hall 10.1, Booth B020/C021).

Contact address

B. Braun Deutschland GmbH & Co. KG, Germany
+49 5661 9147-7000
info.de@bbraun.com
www.bbraun.de

bredent medical

The all-round solution package for implantology

With ALL-IN-ONE, the bredent group presents itself as an all-round solution provider for dental therapy forms. Under the motto "360° Implantology", the company offers a complete package for implant care.

Whether treatment planning, the correct choice of materials and gentle insertion of the implant or the prosthetic care—bredent accompanies users from start to finish.

360° Implantology is an open system that offers its users maximum flexibility. The bredent group has optimised its CAD/CAM systems so that, for example, the prefabs for making individual abutments function smoothly.

For a successful immediate treatment, the position of the implant is of great importance, which is why all bredent implants have great primary stability in all bone qualities. For over 15 years, bredent has been successfully on the market with its SKY fast &

fixed therapy and has been able to bring a smile to more than 100,000 patients in this time. With the help of sophisticated, standardised procedures, edentulous patients can be fully treated with a small number of implants. And in just one day and with a success rate of over 98 per cent.

All bredent implants also have a back taper according to the "Bone Growth Concept", which means they have a crestal bevel. This leaves more room for bone and soft tissue to support the growth of bone.

Get to know ALL-IN-ONE live at IDS 2023!

Contact address

bredent medical GmbH & Co. KG, Germany
info-medical@bredent.com
www.bredent-medical.com

3Shape

Wireless intra-oral scanner

TRIOS 5 Wireless is recognised for its innovative performance and design. A double winner at the UK's Dental Industry Awards, Dental Products Report also named TRIOS 5 one of the Top Game Changers of 2022. In an interview, Dr Sundeep Rawal, Senior Vice President of Implant Support Services at Aspen Dental, stated: "TRIOS 5 nails it."

TRIOS 5 provides excellent performance in a redesigned compact body. The scanner is 30% smaller than the previous 3Shape models, and delivers next-level ergonomics, effortless scanning, and improved hygiene.

The intra-oral scanner achieves a unique level of scanning simplicity with its groundbreaking ScanAssist technology that minimises misalignment and distortion in 3D models. With TRIOS 5, professionals can create a scan path they prefer.

Furthermore, it has received clearance from the U.S. Food and Drug Administration. The scanner features all-day battery life with Smart Power Management. Its closed autoclavable scanner tip is protected by scratch-free sapphire glass. The new enclosed tip means TRIOS 5 never needs calibration.

For availability of 3Shape products in your country or region, please contact your reseller.



Contact address

3Shape Germany GmbH,

Germany

Contactus.de@3Shape.com

www.3shape.com/de-de

Fotona

A multiwavelength laser approach to successful implantology

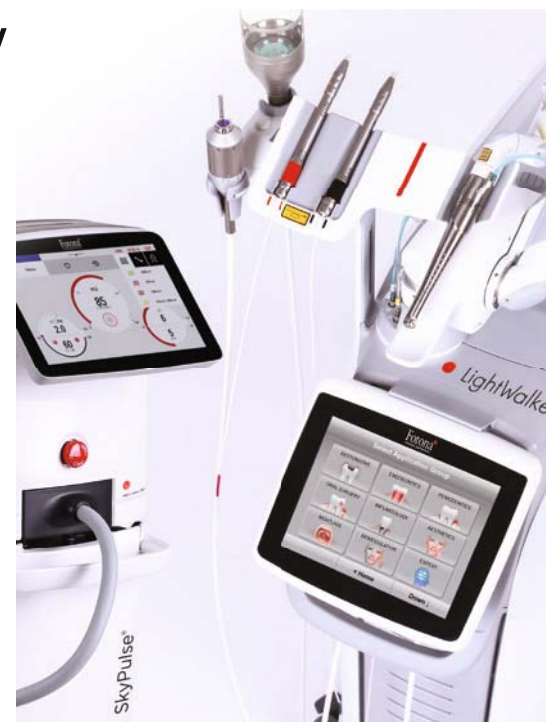Fotona's award-winning LightWalker® and SkyPulse® dental lasers are widely recognised as uniquely versatile tools in dentistry and implantology. With high-precision Er:YAG lasers, they are perfect for the treatment of peri-implantitis, including the removal of granulomatous tissue from inflamed surfaces and direct implant decontamination. They are also highly suitable for fast and safe de-epithelialisation of the gingiva surrounding the extraction socket, which prevents the ingrowth of epithelium into the socket and produces a rough surface that enhances retention of the blood clot. In addition, LightWalker's pulsed Nd:YAG and SkyPulse's high-performance diode lasers allow for highly effective soft-tissue procedures with simultaneous coagulation and disinfection, as well as tissue regeneration, making them ideal for applications in implant surgery. Fotona's comprehensive laser peri-implantitis and post-extraction treatment protocol utilising a multiwavelength approach for degranulation, disinfection, de-epithelialisation, clot stabilisation and photobiomodulation, has proven to be a safe and effective solution for facilitating optimal treatment outcomes.

Contact address

LA&HA, Laser and Health Academy, Slovenia

journal@laserandhealth.com

www.laserandhealthacademy.com



Champions-Implants

Minimally invasive implantology with a two-piece system

The implant market offers not only different implant systems, but also different implantation procedures. As an alternative to conventional approaches, the MIMI Flapless method with the specially developed Champions (R)Evolution® implant offers a minimally invasive workflow with a unique organisational, surgical and prosthetic approach. Read this interview with Armin Nedjat, Professor (PMS College Science & Research), dentist and developer of the MIMI procedure.

Professor Nedjat, what is unique about the Champions (R)Evolution® implant?

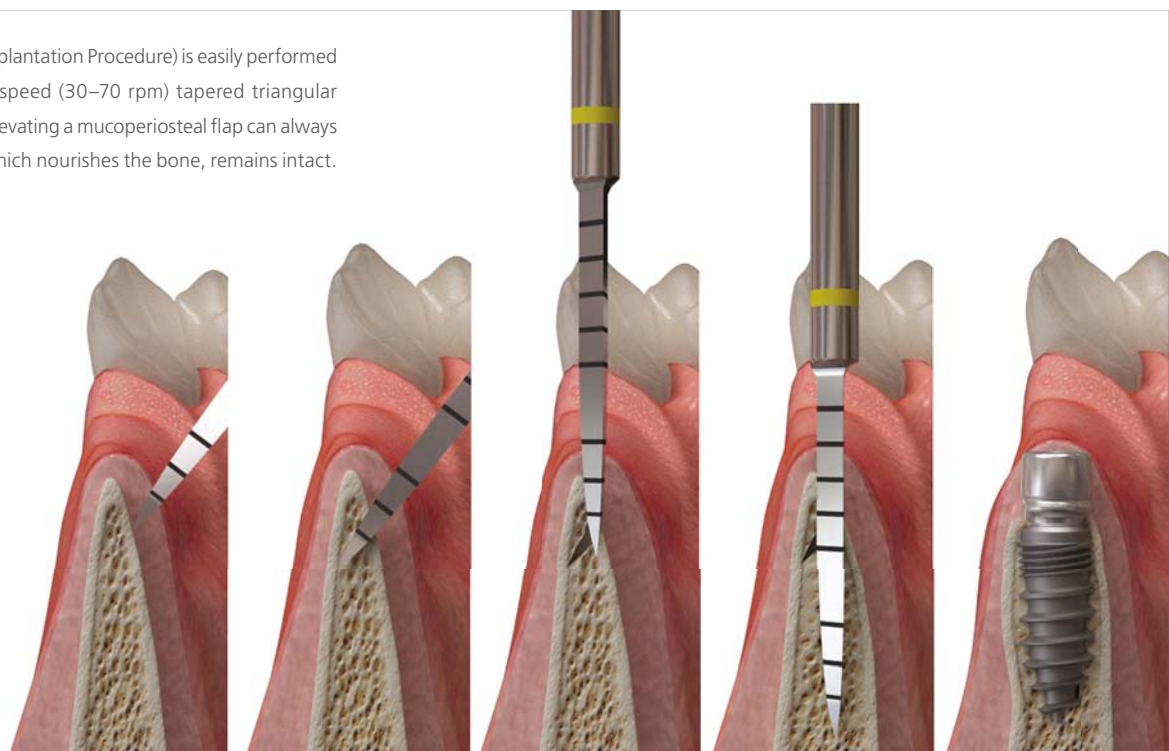
The Champions (R)Evolution® implant is a targeted bone-densifying implant body made of grade 4 titanium (pure titanium) with an exceptional surface roughness due to irradiation and triple etching. Good osseointegration is achieved quickly and permanently. The double 9.5° taper provides a tight bacterial seal against the future abutment and meets the demand for a common prosthetic platform for all implant diameters—3.5, 4.0, 4.5 and 5.5 mm. The ingeniously simple principle of the Champions (R)Evolution® is the shuttle. Assembled sterile at the factory, it serves as an insertion and impression tool, cover screw and healing abutment. This is the real innovation that allows for

minimally invasive implant placement according to the MIMI protocol, a major change in the dental workflow.

What is the implant placement procedure for the two-piece Champions (R)Evolution® implant using the MIMI placement protocol?

At the first appointment, the cortical bone is penetrated either transgingivally or with the help of a small incision or punch, either with a sterile diamond in the irrigated high-speed handpiece or at only 250 rpm in a green contra-angle handpiece with a conical triangular drill. When the cancellous bone is reached (after approximately 1–3 mm), the drill speed is reduced to 50–70 rpm to “activate” the CNIP navigation. The tapered triangular pilot drill

The CNIP (Cortical Navigated Implantation Procedure) is easily performed in cancellous bone using low-speed (30–70 rpm) tapered triangular drills. Exposure of the bone by elevating a mucoperiosteal flap can always be avoided. The periosteum, which nourishes the bone, remains intact.

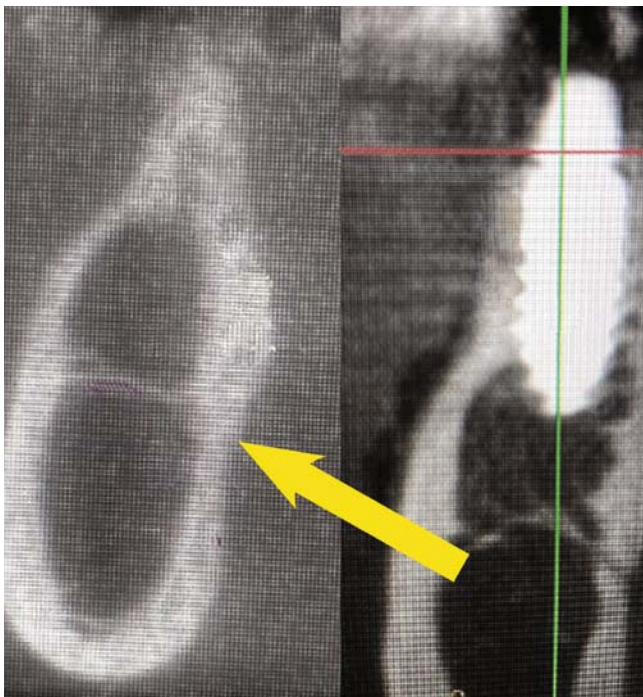


will not penetrate the lateral cortical bone at this low speed—this is similar to the way a Hedström file works, which can never perforate a tooth during root-canal preparation.

The other drills used after the yellow Champions pilot drill are also used at very low speeds and therefore only navigate the “softer” parts of the bone. After preparing the implant site with so-called crestal relief in the hard D1/D2 bone (a drill 0.5 mm wider than the diameter of the implant is used crestally), the implant is inserted with a torque of about 20–60 Ncm, if possible 1–2 mm subcrestally.

What is the research on the success of the MIMI procedure?

Evaluation of a ten-year study of 13,834 Champions (R)Evolution® implants placed showed a success rate of over 96%. The study was evaluated according to the strict Albrektsson criteria, which concluded that subcrestal implantation is preferable to bone-level implantation. A MIMI principle is therefore that it is better to use shorter implants and to place them subcrestally. In many cases in the lateral mandible, shorter implant lengths, e.g. 8 mm, can also be used to achieve a prosthetically ideal implant position due to the mylohyoid lobe.



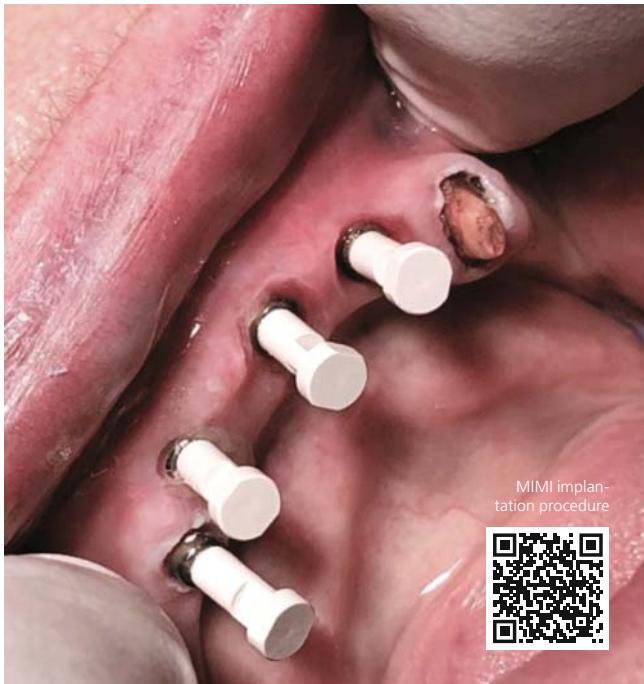It is better to use shorter implants and to use them subcrestally. In the lateral mandible, shorter implants, for example 8 mm, are ideally in many cases, even in the presence of a mylohyoid lobe (yellow arrow).



The Champions (R)Evolution® implant has a bone-condensing body made of grade 4 titanium (pure titanium), which is exceptionally rough due to irradiation and triple etching. Good osseointegration is achieved quickly and permanently. The 9.5° telescopic crown provides a tight bacterial seal against the future abutment and meets the demand for a common prosthetic platform for all implant diameters—3.5, 4.0, 4.5 and 5.5 mm.

Classic implant placement

The classic method of implant placement involves preparing the implant site at 400 to 1,500 rpm (with irrigation), inserting an implant in a “closed” procedure, sealing it with a cover screw and carefully suturing the large wound to seal it against saliva. The sutures are removed after seven to ten days. Complications in the form of soft-tissue inflammation, swelling, haematomas and pain are the rule rather than the exception with this conventional implantation procedure in the first two weeks. At the third appointment, a few months later, the implant site is surgically re-entered, the cover screw is removed, and a so-called gingiva former or healing abutment is placed. After a further one to two weeks, the gingiva former is then removed—often in conjunction with a control radiograph to check correct placement—to allow a metal impression post to be connected to the implant, which is then again unscrewed again for an “open impression” using a custom impression tray. The gingiva former is then reconnected. At the fifth and final appointment, the gingiva former is again removed, the definitive abutment is connected, and the final screw-retained or cemented restoration is connected. The entire procedure, which requires five appointments, takes an average of three hours of chair time for a single crown. This highly complex workflow has not changed since the early days of oral implantology. The MIMI procedure, with the dedicated Champions (R)Evolution® implant system takes a new approach to implant placement.



MIMI—one of the keys to successful dental implantation.

Comparison with cardiac stents

I like to compare MIMI implantology with cardiac stenting, which was first used by US radiologist Charles Dotter in 1963—against considerable resistance from the medical profession at the time. Prior to this, aortic stenosis was treated by extensive open-heart surgery, which involved opening the entire chest. Fourteen years later, German cardiologist Andreas Grüntzig helped catheter-based dilatation achieve a breakthrough. In 1977, he was the first to dilate a narrowed coronary artery using a balloon catheter he had developed. Another decade later, Dotter's idea of using a stent, a small tube, to keep a vessel open permanently became a reality: in 1986, Jaques Puel and Ulrich Sigwart placed the first coronary stents into a human coronary artery. In 1989, the first inflatable stent was implanted using a balloon catheter. High-pressure implantation, developed by Italian cardiologist Antonio Colombo in 1996, was the final breakthrough for stents. In orthopaedic surgery, too, the entire surgical site is no longer opened if possible, because the aim is "to work with nature, not against it". Everything is done as atraumatically and minimally invasive as possible, in the interest of the patient's health, to achieve an improved "workflow" and healing process without the risk of complications. MIMI implantology follows the same philosophy.

What is the MIMI procedure at the first appointment?

After a MIMI implantation with equigingival shuttle closure (to prevent lateral micromovement during healing or bone remodelling in the first six to eight weeks after surgery), a closed impression is taken with a prefabricated impression tray at the first appointment, immediately after implant placement. A PEEK impression post is clipped into the shuttle, which is then scanned intra-orally as a scanbody or left in a conventional polyether or silicone compound, duplicating the oral situation for the dental laboratory with extreme precision. In softer D3/D4 bone, the Champions condensers are used after the first two tapered triangular drills. These bone-compressing instruments can convert D4 bone into D2 bone and achieve primary implant stability of up to 60 Ncm in the cancellous bone in just a few minutes. We call this "osseous metamorphosis" (OMM) because the bone can be gently and carefully "transformed" into a denser structure.

What prejudices does MIMI face?

Surgical exposure of the bone by raising a mucoperiosteal flap in implant-bed preparation should be obsolete by now. Long-term studies have shown that iatrogenic peri-implantitis, including bone and soft-tissue resorption, is a predictable consequence. Prejudices voiced against MIMI, namely that the surgeon is "flying blind" in the bone, are entirely obsolete. With the correct procedure, complete control is maintained at all times.

What does the MIMI procedure achieve, and what does it avoid?

The inside of the implant usually remains sterile until the second and final appointment, when the restoration is delivered. There will be no "breeding ground" for anaerobic bacteria inside the implant body during the so-called healing period. Nor is the all-important biologic width compromised or impaired by "active" reentry. In addition, the internal threads of the implant are not subjected to multiple stresses when using the MIMI procedure with Champions (R)Evolution® implants. Multiple changes of screws, gingiva formers, impression posts, etc. would inevitably result in significant loss of soft and hard tissue.



Contact address

Champions-Implants GmbH, Germany
+49 6734 914080
www.championsimplants.com

16th Europe Symposium of BDIZ EDI

GIORNATE VERONESI

**IMPLANTOLOGY AND
GENERAL DENTISTRY**

**16TH - 17TH JUNE 2023
VALPOLICELLA (ITALIA)**

**OEMUS
EVENT
SELECTION**

**REGISTER
NOW!**

www.giornate-veronesi.info



© Kamira/Shutterstock.com



Economic success in the implantology market in Germany

What role does the choice between two-piece implants with conical and non-conical internal connections play?

Since the first dental implant consensus conference a good 40 years ago, the development of modern implantology has been impressive, both scientifically thanks to the discovery of the biocompatibility of the titanium surface and economically: the number of dental implants placed in Germany has risen from 400,000 per year around 20 years ago to an estimated 1.3 million today—and the upwards trend is stable. Over the years, not only has an independent, innovation-driven industry developed, but also established global competitors in the dental industry want to participate in this solid market.

In Germany, there are currently more than 200 independent endosseous implant systems, an unusually high number are approved and accordingly many national and international suppliers are vying for the favour of the dental profession. There is no doubt that the German market is a key market in which every market participant wants to succeed, particularly in order to succeed globally. It is not easy for dentists to find their way around the selection of implant systems on offer, especially as the pricing of the products varies greatly. The same applies to the effort that suppliers put into the publication of studies, advertising, customer care and training events.

Unsurprisingly, the market is dominated by a manageable number of established providers, who are well known by the public thanks to extensive marketing and are often owned by listed companies. In addition, there are the smaller, often independent manufacturers who are characterised by their innovative spirit rather than advertising presence and large field service organisations. There are also numerous outsiders who are known neither for exceptional presence and pricing nor for innovation and customer proximity. Their market share is small.

The role of innovative spirit for success

In dental implantology, besides one-piece systems and the still young ceramic implant systems, the group of two-piece titanium implants has established itself as the dominant one on the market because it is the most versatile. Among their numerous further developments over the decades, the (not so recent) invention of the conical internal connection between implant and abutment is certainly the most significant innovation, dividing the market roughly into conical and non-conical internal connection implant systems. Some of the large established providers



do offer a conical internal connection implant, some do not. Many of them offer both.

With the conical internal connection, the aim is to mitigate or even eliminate the system-inherent weaknesses of the rightly popular two-piece implant systems. These concern primarily the enormous mechanical stress on the connecting screw between implant and abutment and in the gap between these two parts triggered by masticatory forces, which can promote bacterial colonisation of the interior of the implant when positioned subgingivally. Conical internal connection designs aim to seal this gap or relieve the abutment screw, ideally achieving both.

Dental professionals' needs

Implant manufacturers must always be aware of limited time and limited staff, even in established and successful practices. Accordingly, dentists want lean and easily reproducible processes, especially with regard to teamwork, but without compromising quality. This does not apply only to implantology. While the differences in surgery between conical and non-conical internal connection systems are minor, they are sometimes clear when it comes to implant exposure and impression taking. Non-conical internal connection implants are usually placed crestally or supra-gingivally, which is advantageous for quick and easy exposure and impression taking. For implants with a conical internal connection, more care is required, especially in the correct positioning of the impression aids. The special features of optional sub-crestal insertion, not recommended for non-conical internal connection implants, must also be taken into account.

At the time of restoration, the differences become greater: the butt joint or joint connections of non-conical internal connection systems enable, for example, a clear determination of the correct height for single crowns without the abutment screw being necessary at this point. With many conical internal connection systems, press fit with the connection screw is first

required to determine the fit and occlusion in order to seal the implant and establish the correct fit of the crown. Special unscrewing instruments are often required here to make the extra work easier for the dentist.

Dental technicians too want standardised procedures in order to work economically and avoid mistakes. Furthermore, a diverse selection of abutments is required for modern and sustainable implant prostheses. Conical internal connection implant systems gained a poor reputation among dental technicians in this respect, as the prostheses are considered to be limited and the press fit between abutment and laboratory analogue on the model is considered to be a hindrance. However, many innovative conical internal connection systems now provide dental technicians with the tools to enable them to work as efficiently as with the butt joint. In particular, consistent digitalisation in the fabrication of dental restorations has led to impressive prosthetic possibilities in recent years—and this now applies equally to both designs.

Preventing complications

The enormous increase in the number of implants placed in Germany over the years automatically brought with it a significant increase in the number of high-risk patients treated. A decisive indicator of the predictability of long-term implant success is therefore whether an implant has the necessary design prerequisites to prevent peri-implantitis. With non-conical internal connection systems, it is inherent in the design that some play remains between implant and abutment, which inevitably results in micro-movements and gap formation. These factors are not suitable for preventing gingival recession and bone resorption in the case of subgingival implant positioning. Good results are nevertheless possible, but only if the surgeon pays the utmost attention to sufficient tissue volume, especially mucosa of at least 3 mm thick, which can seal the micro-gap from bacterial intrusion. High surgical effort is unavoidable in many cases.



Conical internal connection implant systems score points in the long term with their tightness and are accordingly more forgiving of tissue deficits. If the construction is designed to completely eliminate micro-movements between abutment and implant, subcrestal positioning is possible and thus a bony seal can form around the implant shoulder, providing the best conditions for stable soft tissue.

Complications include loosening or even fracture of the abutment screw. No one wants regular visits from their patients just to tighten or even replace the screw. It is inherent in the system of non-conical internal connection implants that the screw always has to cope with the force of the connection, and thus complications are latent. With conical internal connection systems, it is worth taking a closer look at the individual details. Especially a large Morse taper can significantly relieve the abutment screw by creating strong self-friction between implant and abutment.



Patients' needs

The patient's desires are ultimately a combination of perfect aesthetics, sustainability and tolerability, as the implantological solution has been recommended to him or her as the best for his or her case. Aesthetically, conical internal connection implants are usually at an advantage, as they are always placed crestally or subcrestally. However, non-conical internal connection systems can also deliver convincing results, provided they are positioned subgingivally, unlike tissue-level implants, and, for example, with a polished shoulder to allow soft tissue on top and bone underneath.

For the patient, the sustainability of the implantological restoration means not only the best possible prevention of peri-implantitis but also, of course, a high degree of tolerance with the aim of achieving the most biological solution possible. While it is up to the dentist to carry out careful patient selection and, in case of suspicion, to test for titanium intolerance, the implant manufacturer of a two-piece system can positively influence the long-term result with its individual design approach to the abutment connection. This is because micro-movements of the abut-

ment in the implant involuntarily result in abrasion of titanium particles, which permanently enter the human organism unnoticed. This must be separated from possible intolerance to titanium surfaces.

The extent and effects of this titanium abrasion are the subject of initial studies, but it can already be said that highly biological solutions with titanium implants can only be achieved if this abrasion is eliminated. It is apparent that the conical internal connection has an inherent advantage here, since it avoids micro-movements.

Market development

The coming years will be characterised by numerous further developments of conical internal connections—which makes sense, because this principle is the more recent one. The much respected large established providers will also present innovations in this area, and thus the market share of conical internal connection systems will continue to increase, but will also soon reach a point where both designs converge in market share. Because of the efficient prosthetic restoration and the simpler workflow, non-conical internal connection systems will retain their supporters. The key to success will be keeping up to date with customers' wishes and responding to these. Customers will succeed in finding exactly the product that suits their philosophy, owing to the enormous diversity of the German implant market that becomes apparent upon closer inspection.

About the author



Andreas Halamoda has been Key Account Manager for the German-speaking markets at a medium-sized German implant manufacturer since 2012. He is also responsible for the areas of training courses with external speakers and internal staff training. He advocates demand-oriented sales and

holistic customer care, starting with the surgeon, continuing with the prosthetic dentist and ending with the dental technician.



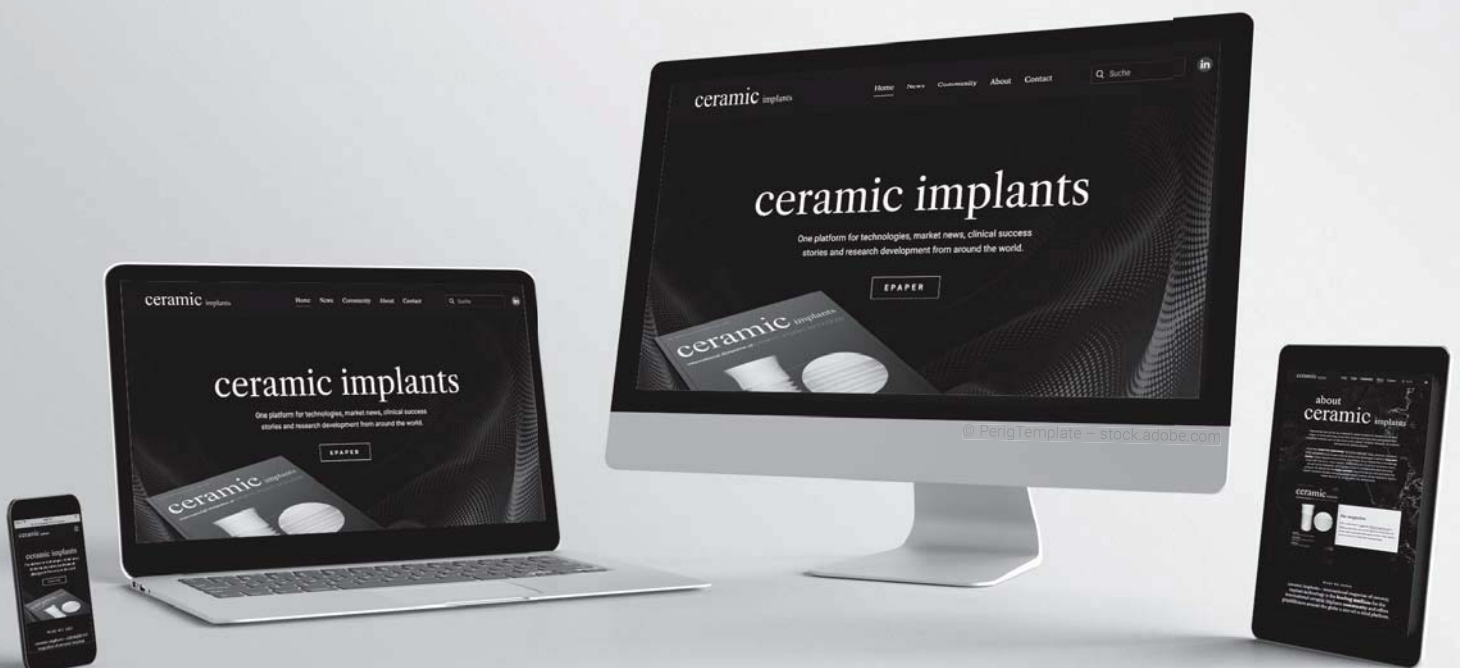Contact address

Andreas Halamoda, Germany
+49 1511 2697915
andreas.halamoda@gmail.com

ceramic implants

is **ONLINE!**

e-paper · news · articles · community · newsletter



Check out the
new website!

ceramic-implants.info



Subscribe to
the newsletter!

ceramic-implants.info/subscribe

	Event	Location	Date	Details/Registration
03/2023	IDS	Cologne Germany	14–18 March 2023	www.ids-cologne.de
04/2023	12 th IAOCI World Congress	Atlanta (GA) USA	13–15 April 2023	www.iaoci.com/iaoci-2023/
	International Osteology Symposium	Barcelona Spain	27–29 April 2023	www.osteology-barcelona.org/delegates/registration
	23. Expertensymposium „Innovationen Implantologie“	Mainz Germany	28–29 April 2023	https://oemus.com/events/7608/23-expertensymposium-innovationen-implantologie
05/2023	ITI Congress Germany & Austria	Dresden Germany	12–13 May 2023	https://events.iti.org/congressgermany-austria/Startseite
	Oral Reconstruction Global Symposium	Rome Italy	18–20 May 2023	https://symposium2023.orfoundation.org
06/2023	Implant Solutions World Summit	Athens Greece	08–10 June 2023	www.dentsplysirona.com/worldsummit
	16 th European Symposium of BDIZ EDI and Giornate Veronesi	Valpolicella Italy	16–17 June 2023	www.giornate-veronesi.info

EDI Journal – Information for authors

EDI Journal – the interdisciplinary journal for prosthetic dental implantology is aimed at dentists and technicians interested in prosthetics implantology. All contributions submitted should be focused on this aspect in content and form. Suggested contributions may include:

- Original scientific research
- Case studies
- Product studies
- Overviews

Manuscript submission

Submissions should be made in digital form. Original articles will be considered for publication only on the condition that they have not been published elsewhere in part or in whole and are not simultaneously under consideration elsewhere.

Manuscripts

Pages should be numbered consecutively, starting with the cover page. The cover page should include the title of the manuscript and the name and degree for all authors. Also included should be the full postal address, telephone number, and e-mail address of the contact author.

Manuscripts can be organised in a manner that best fits the specific goals of the article, but should always include an introductory section, the body of the article and a conclusion.

Illustrations and tables

Each article should contain a minimum of 20 and a maximum of 50 pictures, except in unusual circumstances. Our publishing house attaches great importance to high quality illustrations. All illustrations should be numbered, have a caption and be mentioned in the text.

The photos should have a size of 10x15 cm, the image or graphic files must have a resolution of 300dpi. TIFF, EPS and JPG file formats are suitable. Radiographs, charts, graphs, and drawn figures are also accepted.

Captions should be brief one or two-line descriptions of each illustration, typed on a separate page following the references. Captions must be numbered in the same numerical order as the illustrations. Tables should be typed on a separate page and numbered consecutively, according to citation in the text. The title of the table and its caption must be on the same page as the table itself.

References

Each article should contain a minimum of 10 and a maximum of 30 references, except in unusual circumstances. Citations in the body of the text should be made in numerical order. The reference list should be typed on a separate sheet and should provide complete bibliographical information in the format exemplified below:

[1] Albrektsson, T.: A multicenter report on osseointegrated oral implants. *J Prosthet Dent* 1988; 60, 75–82.

[2] Hildebrand, H. F., Veron, Chr., Martin, P.: Nickel, chromium, cobalt dental alloys and allergic reactions: an overview. *Biomaterials* 10, 545–548 (1989).

Review process

Manuscripts will be reviewed by three members of the editorial board. Authors are not informed of the identity of the reviewers and reviewers are not provided with the identity of the author. The review cycle will be completed within 60 days. Publication is expected within nine months.

Copyright

With acceptance of a manuscript, the publisher has the right to publish and translate the text, permit its reproduction, electronically store it in databases, produce reprints, photocopies and microcopies, and publish the text online. Any further utilisation or publication of the article is subject to prior approval by OEMUS MEDIA AG.

Page charges and reprints

There are no page charges. The publisher will cover all costs of production. The journal will provide the primary author with a PDF file of the article and a free copy of the journal issue in which the article appears.

Editors office

OEMUS MEDIA AG
Holbeinstraße 29 · 04229 Leipzig · Germany
Phone: +49 341 48474-224 · Fax: +49 341 48474-290
s.thieme@oemus-media.de
www.oemus.com



MEMBERSHIP REGISTRATION FORM

I hereby apply for a membership in the BDIZ EDI
(European Association of Dental Implantologists)

Name:

First Name:

Country:

Zip Code/City:

Street:

Phone:

Fax:

E-Mail:

Homepage:

Date of Birth:

Practicing implantology since:

Member of other Societies:

ICOI BDO DGI DGZI DGMKG EAO

Continuing education Courses:

.....

Fellowship status / diplomate status in implantology

Yes No Organisation

Entry in BDIZ EDI Directory: Yes No

(For information on BDIZ EDI Directory of Implant Dentists see overleaf)

The annual membership fee for:

FULL MEMBERSHIP

Full member – clinical EUR345.00

Assistant dentist / young professional
(up to 5 years after graduation) EUR172.50

Second membership / family member EUR172.50

EXTRAORDINARY MEMBERSHIP

Co-operative Member EUR165.00
(Professionals without practice
and dental technicians)

Students non-contributory

Supporting Membership EUR530.00
(Companies etc.)

Payment

Membership cannot be confirmed until payment is processed. Method of payment is by bank transfer. Please use the following banking account

Commerzbank Bonn

Account Number: 310 144 100
Bank Code: 380 400 07
IBAN: DE96 3804 0007 0310 1441 00
BIC: COBADEFFXXX

Membership cards will be sent upon receipt of the annual subscription fee.

City/Date:

Seal/Signature:

Please return the completed registration form to:

European Association of Dental Implantologists e.V.

Lipowskystr. 12 · 81373 Munich · Germany

Phone: + 49 89 7206-9888, Fax: + 49 89 7206-9889

E-Mail: office@bdizedi.org, Homepage: www.bdizedi.org

BDIZ EDI • Lipowskystr. 12 • 81373 Munich, Germany • Phone: +49 89 7206-9888 • Fax: +49 89 7206-9889
office@bdizedi.org • www.bdizedi.org

The commercial processing of your personal data on this form is based on the EU General Data Protection Regulation (GDPR – Regulation (EU) 2016/679 of 27 April 2016), Article 6 f GDPR by the European Association of Dental Implantologists (BDIZ EDI), Lipowskystr. 12, 81373 Munich/Germany.

You have the right to obtain information about personal data concerning you (Article 15 of the GDPR). You can also request the correction (rectification) of incorrect data (Article 16 of the GDPR). More information: Privacy Statement on www.bdizedi.org.

WE CAN WORK IT OUT.

These implant systems were awarded the CleanImplant “Trusted Quality” seal after an unbiased and peer-reviewed quality assessment.



BlueDiamond
MEGAGEN

UnicCa
BTI

Patent
CHAMPIONS IMPLANTS

In-Kone
GLOBAL D

Conelog
CAMLOG

AnyRidge
MEGAGEN

Kontakt S
BIOTECH DENTAL

ICX-Premium
MEDENTIS MEDICAL

Prama
SWEDEN & MARTINA

SDS 1.2
SWISS DENTAL SOLUTIONS

(R)Evolution
CHAMPIONS IMPLANTS

whiteSKY
BREIDENT MEDICAL

SDS 2.2
SWISS DENTAL SOLUTIONS

T6
NUCLEOSS

IDS Köln

**SEM-checks
on-site!**

**HALL 10.2
BOOTH 0-042**

- Receive quality information about your implant in use.
- Provide more safety for your patients and avoid negligence claims.
- Win new patients as a CleanImplant Certified Dentist.
- Find out more. Join in and support the charitable initiative.



More information about this non-profit initiative:
www.cleanimplant.com/dentists

CLEAN IMPLANT
FOUNDATION