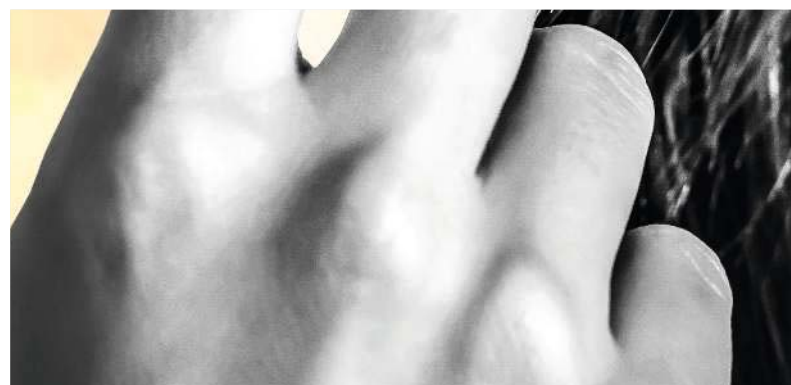
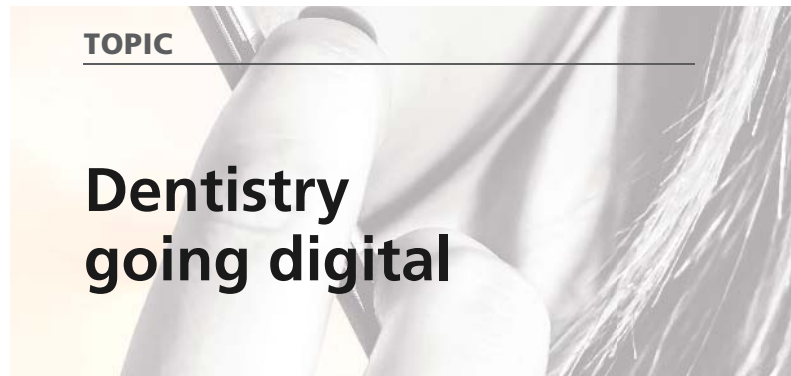
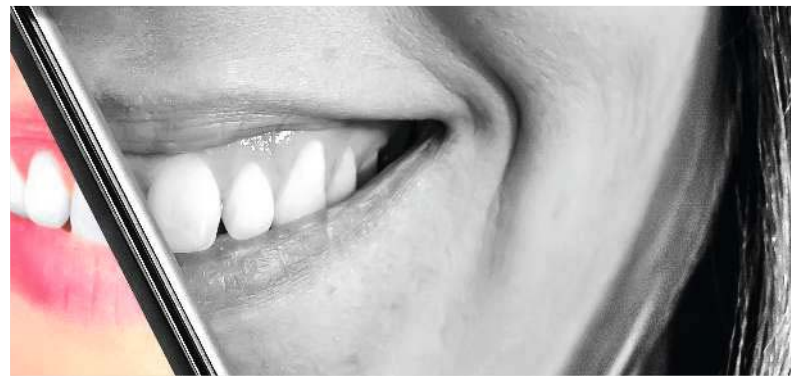# EDI Journal

European Journal for Dental Implantologists



© terovesalainen – stock.adobe.com

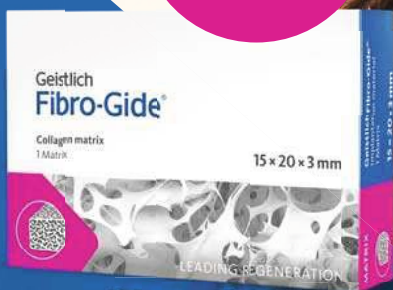»EDI News: Interview with Dr Tina Mandel about her dental app · Recommendations for national governments »European Law: Not every breach of the GDPR automatically entitles to compensation »Case Studies: Treatment of a patient with severe bruxism, loss of vertical dimension, tooth wear and fracture of dental implants · Augmentation and implantation in a two-stage approach · Implant and alloplast synergy in a complex anterior maxillary case · Report on the 18<sup>th</sup> Expert Symposium of BDIZ EDI



# What solution would your patient choose?

66.7% of patients prefer Geistlich Fibro-Gide® over connective tissue graft treatment at 6 months.<sup>1</sup>

NEW SIZES



Explore our Palate Free solutions.



## BDIZ EDI and legal action

Dear colleagues,

These days, BDIZ EDI is waiting for a letter from the German Federal Ministry of Health. On behalf of the BDIZ EDI, Prof. Thomas Ratajczak, our legal counsel, has requested a statement on the inequality of treatment inherent in the German medical and dental fee regulations. In his five-page letter, he asks how it is possible that the value of a fee point according to the German Standard Schedule of Fees for Dentists (GOZ) has remained unchanged for 65 (sixty-five!) years. "After this immense period of time, there is no way to justify a situation in which dentists (and physicians) are treated so unfairly as the Federal Ministry of Health has treated them for decades, compared to other liberal professions—veterinarians being a good example", Ratajczak writes.

As the saying goes, hope dies last, but I dare to predict that we will wait in vain for a positive message from Prof. Karl Lauterbach, the Federal Minister of Health. But we are prepared for that. Our legal counsel is preparing the arduous legal action of six dentists—including our President Christian Berger, our Vice President Prof. Joachim Zöller, and other board members—before the competent administrative court in Berlin, which is responsible for this case because in Germany, administrative courts also have jurisdiction over the state. They rule on disputes between citizens, in this case dentists, and administrative authorities.

As many of our members know, BDIZ EDI was founded in 1989 as a result of the failure to adjust the GOZ point value in 1988. Since then, the association has stood up for its members and for colleagues in Germany and Europe and has not shied away from legal action. In 2001, BDIZ EDI was instrumental in obtaining a ruling from the German Federal Constitutional Court, to establish the "Focus of Professional Activities: Oral Implantology"

(Tätigkeitsschwerpunkt Implantologie) as an official designation and an indication of a narrower area of specialisation for dentists, in the face of opposition from the federal and state dental associations. In 2013, BDIZ EDI filed a lawsuit against the 2012 GOZ on behalf of six dentists, also before the Federal Constitutional Court. At the time, Germany's highest court skilfully side-stepped the issue and did not accept the case for decision. We were also involved in Brussels and Strasbourg with a BDIZ EDI statement when the European Commission was about to launch the EU Service Directive. Similarly, we have repeatedly criticised the impact of the EU Medical Device Regulation (MDR) on dentists, manufacturers and the market as a whole.

We have learned from years of battling with politicians and legislators in Germany that it is not enough to stick to a single approach. We have launched an information campaign against a new health reform law called the Financial Stabilisation Law for Statutory Health Insurance, which will affect patients through the budgeting of dental services from 2023. We provide regular advice to dentists on billing—through the distribution of written information and through Christian Berger's webinars.

So we take different ways to support our members, the dentists—in Germany or elsewhere in Europe.

A handwritten signature in black ink, appearing to read 'Stefan Liepe'.

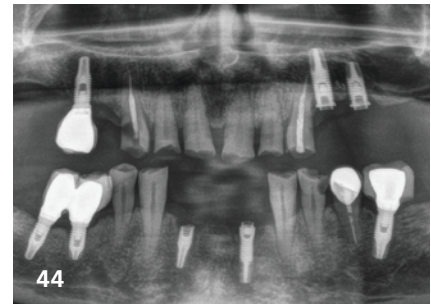
Dr Stefan Liepe, Managing Director, BDIZ EDI



This was IDS 2023



International Implantology Congress in Nepal



Treatment of a patient with severe bruxism, loss of vertical dimension, tooth wear and fracture of dental implants

## EDI News

- 08 Seminar offers**  
BDIZ EDI will provide online lectures in 2023
- 10 “Implantology step by step”: Start of the training series**  
BDIZ EDI offers webinar series on implantology
- 12 A proud anniversary: 25<sup>th</sup> Curriculum Implantology**  
Register now for Cologne—Curriculum South starts in 2024
- 14 A cornucopia of small innovations**  
This was IDS 2023
- 18 Diagnosis the digital way**  
Interview with Dr Tina Mandel about her dental app
- 20 President-elect of the Academy of Osseointegration**  
Meet Prof. Jörg Neugebauer
- 22 We want YOU!**  
BDIZ EDI and its multifaceted work
- 24 A versatile mixture**  
16<sup>th</sup> Europe Symposium and Giornate Veronesi 2023
- 26 BDIZ EDI on social media**  
Instagram, Facebook, Twitter, YouTube
- 28 Oral implantology in the Himalayas**  
International Implantology Congress in Nepal
- 30 Concepts of prosthetic care**  
32<sup>nd</sup> Expert Symposium on Regenerative Procedures in Dentistry
- 32 Recommendations for national governments**  
Position on dental workforce
- 34 Europe Ticker**
- 36 A leading authority on expert opinions has left us**  
Obituary: Dr Hans-Hermann Liepe
- 37 Did you ever know...**  
Facts about the BDIZ EDI
- 38 Not every breach of the GDPR automatically entitles to compensation**  
Judgement of the European Court of Justice in Case C-300/21
- 40 “Regulation is legally possible and urgently needed”**  
Investor-owned medical care centres (MCCs)
- 42 Qualification for experienced implantologists**  
Certification as an EDA Expert in Implantology

## Case Studies

- 44 Treatment of a patient with severe bruxism, loss of vertical dimension, tooth wear and fracture of dental implants**
  - 50 Augmentation and implantation in a two-stage approach**
  - 54 Implant and alloplast synergy in a complex anterior maxillary case**
  - 60 Soft-tissue thickening—natural revascularisation with NovoMatrix®**
  - 62 Compact know-how**  
Report on the 18<sup>th</sup> Expert Symposium of BDIZ EDI
- ## Business & Events
- 66 Cutting edge science and innovation**  
Dentsply Sirona Implant Solutions World Summit 2023
  - 68 Osteology Symposium 2023: New approaches to immediate restoration and soft-tissue management**  
BioHorizons Camlog
  - 69 A global academic symposium uniting dental professionals**  
OSSTEM World Meeting 2023
  - 70 Digital dentistry—the sky is the limit**
  - 72 More manufacturers prove the production quality of their implant systems**  
CleanImplant “Trusted Quality” seal
  - 74 Whither ceramic implantology?**  
New trends in oral implantology
  - 76 Empowering dentists: comprehensive educational programmes in Europe**  
OSSTEM IMPLANT Scientific Community

## News and Views

- 03 Editorial**
- 06 Partner Organizations of BDIZ EDI**
- 07 Scientific Board/Imprint**
- 78 Product Reports/Product Studies/Product News**
- 82 Calendar of Events/Publisher’s Corner**



## NovoMatrix™ Reconstructive Tissue Matrix – the next generation material

NovoMatrix™ Reconstructive Tissue Matrix is an acellular dermal matrix derived from porcine tissue intended for soft tissue applications. The proprietary LifeCell™ tissue processing is designed to maintain the biomechanical integrity of the tissue, which is critical to support tissue regeneration.

### Indications

- Localized gingival augmentation to increase keratinized tissue (KT) around teeth and implants
- Alveolar ridge reconstruction for prosthetic treatment
- Guided tissue regeneration procedures in recession defects for root coverage

### Product features

- Consistent thickness (1 mm)
- Pre-hydrated
- Controlled source

[www.biohorizonscamlog.com](http://www.biohorizonscamlog.com)

Before use, physicians should review all risk information, which can be found in the Instructions for Use attached to the packaging of each NovoMatrix™ Reconstructive Tissue Matrix graft. NovoMatrix™ is a trademark of LifeCell™ Corporation, an Allergan affiliate. ©BioHorizons. All rights reserved. Not all products are available in all countries.

# Partner Organizations of BDIZ EDI



## Association of Dental Implantology UK (ADI UK)

ADI UK, founded in 1987, is a registered charity committed to improving the standards of implant dentistry by providing continuing education and ensuring scientific research. It is a membership-focused organisation dedicated to providing the dental profession with continuing education, and the public with a greater understanding of the benefits of dental implant treatment. Membership of the ADI is open to the whole dental team and industry, and offers a wealth of benefits, education and support for anyone wishing to start out or develop further in the field of dental implantology.



## Ogólnopolskie Stowarzyszenie Implantologii Stomatologicznej (OSIS EDI)

OSIS EDI, founded in 1992, is a university-based organisation of Polish scientific implantological associations that joined forces to form OSIS. The mission of OSIS EDI is to increase implant patients' comfort and quality of life by promoting the state-of-the-art and high standards of treatment among dental professionals. OSIS EDI offers a postgraduate education in dental implantology leading to receiving a Certificate of Skills (Certykat Umiejetnosci OSIS), which over 130 dental implantologists have already been awarded.



## Sociedad Española de Implantes (SEI)

SEI is the oldest society for oral implantology in Europe. The pioneer work started in 1959 with great expectations. The concept of the founding fathers had been a bold one at the time, although a preliminary form of implantology had existed both in Spain and Italy for some time. Today, what was started by those visionaries has become a centrepiece of dentistry in Spain. SEI is the society of reference for all those who practice implantology in Spain and has been throughout the 50 years, during which the practice has been promoted and defended whereas many other societies had jumped on the bandwagon. In 2009 SEI celebrated its 50<sup>th</sup> anniversary and the board is still emphasizing the importance of cooperating with other recognised and renowned professional societies and associations throughout Europe.



## Sociedade Portuguesa de Cirurgia Oral (SPCO)

The SPCO's first international activity was the foundation—together with their counterparts in France, Italy, Spain and Germany—of the European Federation of Oral Surgery (EFOOS) in 1999. The Sociedade Portuguesa de Cirurgia Oral's primary objective is the promotion of medical knowledge in the field of oral surgery and the training of its members.



## Udruženje Stomatologa Implantologa Srbije-EDI (USSI EDI)

USSI EDI was founded in 2010 with the desire to enhance dentists' knowledge of dental implants, as well as to provide the highest quality of continuing education in dentistry. The most important aims of the organisation are to make postgraduate studies meeting the standards of the European Union available to dentists from Serbia and the region; to raise the level of education in the field of oral implantology; to develop forensic practice in implantology; and to cooperate with countries in the region striving to achieve similar goals.

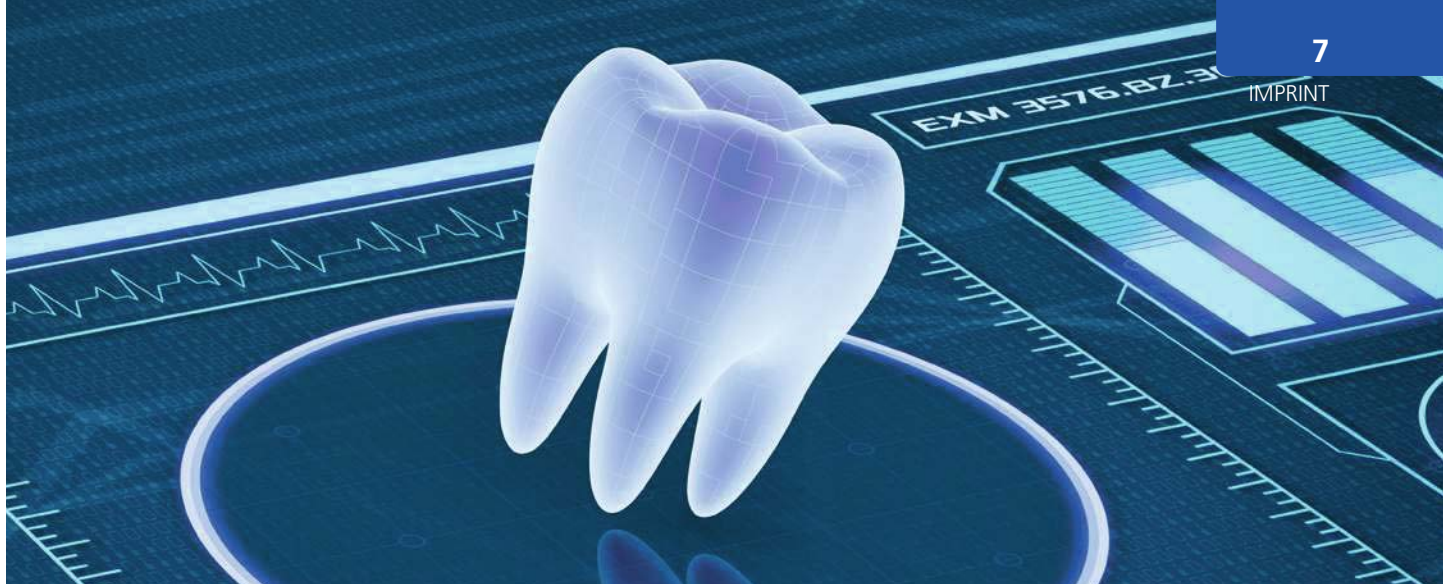

## EDI of Macedonia

The Association is Albanian Implantology Association of Macedonia—AIAM was founded in 2013 as a branch of Albanian Dental Society of Macedonia. The association was created to advance education in the field of dental implantology for the benefit of the population. The objectives of the association are:

- To promote the progress of education, research and development of dental implantology in Macedonia
- To encourage postgraduate education, study and research in dental implantology through:
  - Appointment of meetings, lectures, seminars and courses either individually or with others
  - Encouraging the publication of dental implantology articles!
  - To cooperate and make agreements with relevant, national, local, foreign and different institutions.

In 2017, AIAM & MAOS (Macedonian Association of Oral Surgeons) became EDI of Macedonia and signed a Cooperation Agreement with BDIZ EDI to cooperate in dental implantology!



## Scientific Board

 <b>Dr Iyad Abou-Rabii, Coventry</b>	 <b>Dr Maher Almasri, Coventry</b>	 <b>Professor Alberico Benedicenti, Genoa</b>	 <b>Dr Eduardo Anitua, Vitoria-Gasteiz</b>	 <b>Dr Marco Degidi, Bologna</b>	 <b>Dr Eric van Dooren, Antwerp</b>	 <b>Professor Rolf Ewers, Vienna</b>
 <b>Professor Antonio Felino, Porto</b>	 <b>Professor Jens Fischer, Basel</b>	 <b>Dr Roland Glaser, Zurich</b>	 <b>Professor Ingrid Grunert, Innsbruck</b>	 <b>Dr Detlef Hildebrand, Berlin</b>	 <b>Dr Axel Kirsch, Filderstadt</b>	 <b>Professor Ulrich Lotzmann, Marburg</b>
 <b>Professor Edward Lynch, Coventry</b>	 <b>Dr Konrad Meyenberg, Zurich</b>	 <b>Professor Georg Nentwig, Frankfurt</b>	 <b>Professor Jörg Neugebauer, Landsberg a. Lech</b>	 <b>Professor Hakan Özyuvaci, Istanbul</b>	 <b>Professor Georgios Romanos, Stony Brook</b>	 <b>Luc Rutten, MDT, Tessenderlo</b>
 <b>Patrick Rutten, MDT, Tessenderlo</b>	 <b>Dr Henry Salama, Atlanta</b>	 <b>Dr Maurice Salama, Atlanta</b>	 <b>Dr Ashok Sethi, London</b>	 <b>Professor Joachim E Zöller, Cologne</b>		

All case reports and scientific documentations are peer reviewed by the international editorial board of EDI Journal.

Chair is Professor Jörg Neugebauer.

## Imprint

**Association:** The European Journal for Dental Implantologists (EDI) is published in cooperation with BDIZ EDI.

**Publisher Board Members:** Christian Berger, Professor Joachim E. Zöller, Professor Jörg Neugebauer, Professor Thomas Ratajczak

**Editor-in-Chief (responsible according to the press law):**  
Anita Wuttke, Phone: +49 89 72069-888, wuttke@bdizedi.org

**Advertising Management:** OEMUS MEDIA AG, Stefan Thieme,  
Phone: +49 341 48474-224, s.thieme@oemus-media.de

**Publisher:** OEMUS MEDIA AG, Holbeinstraße 29, 04229 Leipzig, Germany  
Phone: +49 341 48474-224, Fax: +49 341 48474-290  
s.thieme@oemus-media.de, www.oemus.com

**Managing Director:** Ingolf Döbbecke, Lutz V. Hiller

**Subscription:** OEMUS MEDIA AG, Jenny Panke,  
Phone: +49 341 48474-200, j.panke@oemus-media.de

**Translation:** Per N. Döhler, Triacom Dental

**Editorial Management:** OEMUS MEDIA AG, Dr. Alina Ion,  
Phone: +49 34148474141, a.ion@oemus-media.de

**Layout:** Dipl.-Des. (FH) Alexander Jahn, Lisa Greulich

**Printing:** Silber Druck oHG, Otto-Hahn-Straße 25, 34253 Lohfelden, Germany

**Publication Dates:** March, July, September, December

**Subscription Rates:** Annual subscription: Germany €40 including shipping and VAT. All other countries €58 including shipping. Subscription payments must be made in advance. Ordering: in written form only to the publisher. Cancellation deadlines: in written form only, eight weeks prior to end of subscription year. Subscription is governed by German law. Past issues are available. Complaints regarding non receipt of issues will be accepted up to three months after date of publication. Current advertising rate list of 1/1/2022. ISSN 1862-2879

**Copyright and Publishing Rights:** All rights reserved. The magazine and all articles and illustrations therein are protected by copyright. Any utilisation without the prior consent of editor and publisher is inadmissible and liable to prosecution. No part of this publication may be produced or transmitted in any form or by any means, electronic or mechanical including by photocopy, recording, or information storage and retrieval system without permission in writing from the publisher. With acceptance of manuscripts the publisher has the right to publish, translate, permit reproduction, electronically store in databases, produce reprints, photocopies and microcopies. No responsibility shall be taken for unsolicited books and manuscripts. Articles bearing symbols other than of the editorial department or which are distinguished by the name of the authors represent the opinion of the aforementioned, and do not have to comply with the views of BDIZ EDI or OEMUS MEDIA AG. Responsibility for such articles shall be borne by the author. All information, results etc. contained in this publication are produced by the authors with best intentions and are carefully checked by the authors and the publisher. All cases of liability arising from inaccurate or faulty information are excluded. Responsibility for advertisements and other specially labeled items shall not be borne by the editorial department.

**Copyright:** OEMUS MEDIA AG · **Place of jurisdiction:** Leipzig



## BDIZ EDI: Update Implantology 2023

BDIZ EDI will provide  
online lectures in 2023

# Seminar offers

There is a great demand for information on advanced dental topics in continuing professional development. European and international members and other interested parties can choose from several BDIZ EDI online seminars. For members of associated partner organisation, the seminars are free of charge.

Just tick the topic you would like to be presented online.

Send your selection either to the Editorial office at [office-munich@bdizedi.org](mailto:office-munich@bdizedi.org)  
or by fax to +49 89 72069889

- Topic 1: Update on peri-implantitis; Guideline of the European Consensus Conference in 2020**  
**Presenter: Professor Jörg Neugebauer (Landsberg/Germany), Secretary General of BDIZ EDI, 7–8 p.m.**  
 About this seminar: Biological complications cannot be avoided completely; they occur at different times following the delivery of the implant restoration. The etiology of these complications is diverse as the way in which they manifest themselves. This issue has been addressed three times before by the European Consensus Conference under the auspices of BDIZ EDI; this panel of experts has re-evaluated the current literature and updated the recommendations of the Guideline. Prof. Neugebauer will present the most recent findings from the literature with numerous clinical examples to ensure the best possible care for patients with peri-implantitis, with a view to avoiding implant loss and eliminating risk factors.
- Topic 2: Update on bone augmentation surgery**  
**Presenter: Dr Dr Markus Tröltzsch (Ansbach/Germany), Member of the BDIZ EDI Board, 7–8 p.m.**  
 About this seminar: For implantological restorations to achieve long-term stability, both hard and soft tissues must be available in sufficient quantity and quality. There are many ways in which this can be achieved or maintained. In this online seminar, Dr Tröltzsch, who was in charge of the new DGI/DGZMK-Guideline on implantological indications for the use of bone replacement materials, will highlight the various “minor” and “major” techniques. One of the topics Dr Tröltzsch will discuss how tissue volume can be (re)built or maintained and which of the relevant techniques are suitable for practitioners with different types of practices and different levels of experience.
- Topic 3: Update on short, angulated and diameter-reduced implants—**  
**Guideline of the European Consensus Conference to be updated in 2023**  
**Presenter: Prof. Jörg Neugebauer (Landsberg/Germany), Secretary General of BDIZ EDI, 7–8 p.m.**  
 About this seminar: “The use of short, angulated or diameter-reduced implants in case of reduced bone availability represents today—if the specific treatment parameters are taken into account—a reliable therapy option compared to the risks associated with the use of implants with standard dimensions in combination with augmentative procedures.” The conclusion the BDIZ EDI Practice Guide 2023 will be put to the test in this lecture.

Please contact me via e-mail at:


[www.bdizedi.org/seminare](http://www.bdizedi.org/seminare)



EXPERIENCE THE ART OF  
**ESTHETIC  
DENTISTRY**

21.09. – 23.09.23 | BADEN-BADEN, GERMANY

Explore new perspectives.  
Meet world-class experts.  
Grow your capabilities.  
Join the community.



GET YOUR TICKET

INTERNATIONAL  
**ES  
THE DAYS  
TIC**

 **straumann**

A0046\_1/en/B/00/1/01\_05/23

From the basics to the master class: BDIZ EDI offers webinar series on implantology

# “Implantology step by step”: Start of the training series

BDIZ EDI is launching a series of webinars that will leave no questions unanswered when it comes to oral implantology and related disciplines. Starting this autumn, everything will revolve around implantology—step by step. Hosted by Prof. Johannes Einweg (Würzburg), the series covers the entire range from the basics to the master class.



The series has been designed and will be moderated by Prof. Johannes Einweg, known for his successful continuing-education presentations, and by BDIZ EDI President Christian Berger. It covers everything from planning, preparation and implant placement to provisionalisation, prosthetics, orthodontics—and billing for these therapies. It is a great way for beginners to get started in implant dentistry

and for everyone else to expand their knowledge. The training series can only be booked as a complete package.

## The speaker pool

Well-known speakers are on board: Prof. Christof Dörfer, Dr Markus Tröltzsch, Dr Dirk Heering, Dr Ali-Reza Ketabi, Horst Dieterich, Prof. Johann Müller, Dr Kathrin

Becker, Christian Berger and Kerstin Salhoff.

By way of introduction, BDIZ EDI is offering two separate free webinars. Like the rest of the series, they can be booked as “training on demand” after the series has completed.

## Our compact offer

The online lectures will take place from 7:00 to 7:45 p.m., followed by a discussion. The series starts on 26 September 2023 with Dr Dirk Heering talking about “Planning”. Two continuing education (CE) credits are available per webinar. If you register for the full package and attend all webinars, you will receive 14 CE points.

- Registration fee: €560
- Members: €300
- New members: €290
- Training on demand: See fee above

Once the training series has been completed, it will be available as “training on demand” at the same price. The final webinar will be held on 19 December 2023. Please turn over for the programme overview. For more information and to register, please visit [www.bdizedi.org](http://www.bdizedi.org).

The series is in German language only. However, if you are interested in this post-graduate education, please contact us: [office-munich@bdizedi.org](mailto:office-munich@bdizedi.org)



AWU

ONLINE TRAINING SERIES

# IMPLANTOLOGIE STEP BY STEP

with Prof. Johannes Einwag



## Two free webinars to start

### 13.06. ORAL HEALTH AND GENERAL HEALTH

Prof. Christof Dörfer

### 27.06. DEMOGRAPHICS: HOW IS IMPLANTOLOGY CHANGING?

Dr Markus Tröltzsch

### 26.09. PLANNING Dr Dirk Heering

**Implant and patient selection  
for your prosthetic cases**

### 10.10. PREPARATION Dr Ali-Reza Ketabi

**From extraction (socket and ridge preservation)  
to gingiva formers and drilling templates**

### 24.10. IMPLANT PLACEMENT Dr Markus Tröltzsch

**Bone grafting versus short, angulated  
and/or reduced-diameter implants**

### 07.11. PROVISIONALISATION Horst Dieterich

**Provisionals as an alternative to immediate dentures**

### 21.11. PROTHETICS Prof. Johann Müller

**Does the occlusion concept change with the number  
and positions of implants?**

### 05.12. ORTHODONTICS Dr Kathrin Becker

**Implants  
as retention elements in orthodontics**

### 19.12. BILLING FOR THESE TREATMENTS

Kerstin Salhoff, Christian Berger



#### REGISTRATION FEE:

Full package (non-members)	€560
BDIZ EDI members	€300
“Join and save”	€290

REGISTER NOW TO SECURE YOUR PLACE:  
[WWW.BDIZEDI.ORG](http://WWW.BDIZEDI.ORG)



You can book the complete package “on demand” (after completion of the series)  
See “Full package” for the applicable fee.

Register now for Cologne—Curriculum South starts in 2024

# A proud anniversary: 25<sup>th</sup> Curriculum Implantology

The BDIZ EDI Curriculum Implantology is a must for beginners—but not only for them. The BDIZ EDI regularly offers profound basic training in oral implantology in cooperation with the University of Cologne. The Curriculum stands out for the great emphasis it places on hands-on exercises. A special feature is that training modules completed elsewhere can be integrated into the BDIZ EDI Curriculum Implantology if their scientific character is recognised. The 25<sup>th</sup> Curriculum will start in Cologne in October 2023. And as a result of the tremendous demand, BDIZ EDI now announces its new Curriculum South, to start in Munich in 2024.

A noteworthy feature of the Curriculum at the University of Cologne is that all participants receive guidance by the Cologne team (Prof. Joachim E. Zöller, Prof. Hans-Joachim Nickenig, Dr Mathias Kreppel) throughout all eight modules. Up-to-date scripts for all modules ensure that the common thread is never lost.

## Eight modules

Each module is designed to systematically build on previous modules, so that Curriculum participants will receive a complex total implantological package for their future practical work, ranging

from simple standard protocols to 3D augmentation techniques and complex and implant prosthetics.

To ensure easy access to oral implantology as a whole, coverage will be very broad—deliberately including even seemingly self-evident aspects, such as protocols, different implant systems, required instrument sets, simple and advanced diagnostics and implant-prosthetic restoration concepts. The accompanying workshops facilitate subsequent implant surgical and prosthetic training. In addition to the scheduled live surgeries, and following previous joint preparation, implant surgery may be performed on pa-

tients presented by participants by one of the Cologne-based speakers, assisted by the participant who introduced the case.

To complement the learning results, participant cases will regularly be presented within the group. Towards the end of the Curriculum, the techniques acquired will be practised on human specimens.

The integration of current topics and treatment methods (3D surgery, bone preparation using ultrasound, CAD/CAM technology for bone regeneration, etc.) round off the practical benefits of the Curriculum Implantology.

For the final examination, candidates are expected to present and discuss two surgical and/or prosthetic implantological cases. Certificates will be presented immediately once the exam has been passed.

## DCourse schedule:

**Day 1:** Thursday, 2 p.m. to 8 p.m.

**Day 2:** Friday, 8 or 9 a.m. to 6 p.m.

### Course fees and registration

€4,500 for BDIZ EDI members\*

€5,800 for non-members

**Registration:** [office@bdizedi.org](mailto:office@bdizedi.org) or using our online form at [www.bdizedi.org/wp-content/uploads/fortbildung/curriculum/Anmeldung-Curri\\_\\_neu\\_2023-1.pdf](http://www.bdizedi.org/wp-content/uploads/fortbildung/curriculum/Anmeldung-Curri__neu_2023-1.pdf)

\* The reduced fee applies to new members only if they agree to join for at least 36 months.

## Curriculum South

Encouraged by the increasing demand for the Curriculum in Cologne, BDIZ EDI will set up the Curriculum South on the same principles. It will also be directed by BDIZ EDI Vice President Prof. Joachim E. Zöller. The modules will be identical to those of the Cologne model. For more information, visit [www.bdizedi.org/en/curriculum-implantology](http://www.bdizedi.org/en/curriculum-implantology).

EB

# The 8 modules of the BDIZ EDI Curriculum Implantology

## Module 1

13–14 October 2023

### Fundamentals of oral implantology

- Anatomy and histology of the stomatognathic system
- General diagnostics in oral implantology
- Patient education
- Cologne ABC Risk Score

+ external presenters

## Module 2

1–2 December 2023

### Indications, diagnosis and treatment planning

- High-risk patients and monitoring
- Description of indications
- Avoiding malpositioning
- Patients with coagulation disorders

+ *Workshop I:*  
*Surgical and prosthetic protocols*  
+ external presenters

## Module 3

26–27 January 2024

### Implant systems, instruments, advanced diagnosis

- Diagnostic tomography
- Fundamentals of 3D diagnostics
- Surgical templates/guide sleeves
- Choice of implants
- Comparison of implant systems

+ *Workshop II:*  
*3D workshop with interactive planning*  
*Demonstration of different instrument sets*  
*Case presentations by participants I*

## Module 4

15–16 March 2024

### Implant prosthetics I and minimally invasive surgery

- State-of-the-art in tooth extraction
- Implant prosthetics (instruments, impressions, abutments)
- Minimally invasive procedures (flapless surgery, 3D bone splitting, sinus floor elevation)
- Emergencies in the dental practice

+ *Workshop III:*  
*Surgical and prosthetic protocols, instrument sets*  
*Modified bone splitting using Piezosurgery*  
*Case presentations by participants II*

## Module 5

17–18 May 2024

### Augmentation I: Regional bone augmentation

- Unfavourable biomechanics vs augmentation
- Immediate implant placement
- Sinus floor elevation

+ *Workshop IV:*  
*Sinus floor elevation training on models and animal specimens*  
*Exercise in customised bone regeneration*  
+ external presenters  
*Case presentations by participants III*

## Module 6

5–6 July 2024

### Implant prosthetics II and soft-tissue management

- Antibiotic therapy
- Implant re-entry and soft-tissue corrections
- Implant prosthetics II: Teeth and implants
- Implant prosthetics III: Removable restorations

+ *Workshop V:*  
*Hard- and soft-tissue management: Exercises on porcine jaws*  
*Soft-tissue techniques I and II for augmentation, implantation and exposure*  
+ external presenter  
*Case presentations by participants IV*  
*Written examination*

## Module 7

2–3 August 2024

### Augmentation II: Bone grafting and distraction

- Iliac crest transplants
- Fundamentals and results of distraction osteogenesis
- Implant prosthetics in the anterior region

+ *Practical exercises on human specimens;*  
*practical training of the acquired surgical techniques*  
+ external presenters  
*Case presentations by participants V*

## Module 8

16–17 August 2024

### Recall—coping with complications—future perspectives

- Recall
- Peri-implantitis therapy
- Oral implantologists in court
- Ceramic coating of implants

+ external presenters

## Curriculum online

For more information on the curriculum visit the BDIZ EDI website: [www.bdizedi.org/en/curriculum/](http://www.bdizedi.org/en/curriculum/)

## Final exam



## This was IDS 2023

# A cornucopia of small innovations

The 40<sup>th</sup> International Dental Show (IDS) celebrated 100 years of IDS with a ceremony on the eve of the opening day and the obligatory ribbon-cutting by the Lord Mayor of Cologne, Henriette Reker. The general mood in Cologne was good. After five days of the fair, the organisers were satisfied with the number of exhibitors and visitors. Digital workflows and sustainability were the trending topics at IDS 2023.

This report describes some of the innovations presented at the show—although it is limited to a few, given the wealth of innovation in the dental field.

### New developments in direct restorative therapy

Direct restorative therapy plays a key role in many dental practices, which is why developments in this field featured prominently at IDS and attracted a great deal of interest. Current technological developments revolve around glass-ionomer cements, compomers and composites,

especially special bulk-filling and hybrid composites. How many different shades should a practice work with? The choice is immense and of particular interest because of the different pigmentation in the composite materials and the so-called chameleon effect.

An alternative to using pigments for colouring is to use the intrinsic structure of the material. The solution to a practical problem was presented at IDS 2023: bubbles that form in flowable composites. Newly designed syringes prevent bubble formation by allowing air to escape through the plunger.

### New products for oral prophylaxis

Nutritional aspects are figuring prominently in oral prophylaxis. Probiotics play a significant role and are supported by scientific results. A toothpaste and a mouthwash enriched with pre- and post-biotics were presented, which ensure that these active ingredients are administered “on the fly” during daily oral care.

A new type of hydrogel based on a mineral salt solution with low surface tension was designed to specifically combat periodontitis. The gel’s action is based on its

high redox potential; the physical charge of 850 mV has a membrane-destroying effect on pathogenic cells. Once applied and effective, the gel dissolves into its original components (water + salts) without leaving any residue.

**Endodontics: minimally invasive and regenerative**

Endodontic files have become more flexible and fracture-resistant over the years, leading to changes in concepts and procedures. Less hard tissue is now removed in the coronal region during tooth preparation while still providing sufficient space in the apical region for effective irrigation. Reciprocating Instruments have made it possible to prepare many root canals with a single file. A new endo-motor has taken reciprocating technology to the next level. Treatment is simplified by combining patency, glide path creation and shaping using the same operating mode. The motor also features an improved OTR (Optimum Torque Reverse) mode, which also prevents file breakage.

**New intra-oral and image plate scanners**

In all areas of dentistry, imaging systems—such as intra-oral scanners—are increasingly aiding treatments. They have



Board member lady power: Dr Nathalie Khasin, Dr Renate Tischer and Kerstin Salhoff (from left). The latter is in charge of the BDIZ EDI billing hotline.

been used for years as an alternative to physical impressions using elastomers—and now it is getting even better. Known challenges associated with this technology, such as those related to reflections, saliva, and translucency, can be overcome by solving the mathematical problem of generating three-dimensional shapes in a four-dimensional space.

In future, intra-oral scanners could also assist in the initial dental examination. For example, a working group at the University of Copenhagen is proposing a method for the automated detection of occlusal caries using a fluorescence-detecting intra-oral scanner.

Diagnostic radiographs are used as a complementary imaging source. Advanced image plate scanners already rely on artificial intelligence (AI) today. AI-based software makes the daily workflow more efficient for the entire team: automatic image rotation, AI-assisted tooth recognition, automatic dose calculation and automatic image plate quality checks save valuable time. And the unit is “made in Germany” using a CO<sub>2</sub>-neutral process.

Existing software could even be used as platform technology to integrate third-party imaging data or clinical information about the patient. In the long term, the aim is to move from diagnosis, to prognosis, to AI support in treatment decisions.

A new extra-oral scanner can scan two casts at once. This is three times faster than scanning two casts one after the other. It can scan impressions as well as casts, and each impression scan takes just 45 seconds.

The simultaneous scanner uses two optical light units and eight cameras. The scanning accuracy is specified as 5 µm (according to ISO 12836) and further processing takes place within the familiar digital workflows, both in terms of software and materials.

Dental 3D printing is also gaining in speed and efficiency, through the intelligent nesting of multiple components on a single build platform. Objects are automatically placed in their optimum positions. This feature is built in the software and does not require data export. A new



High-ranking visitor: Prof. Dr Ishane Ben Yahya (2<sup>nd</sup> from left) from Morocco, acting president of the Federation Dentaire Internationale (FDI) visited the BDIZ EDI with her colleague. Also in the photo: Dr Wolfgang Neumann and Anita Wuttke.



Revolutionary approach: In a live interview, Dr Tina Mandel presented her dental app. Christian Neumann, BDIZ EDI President Christian Berger, Dr Tina Mandel, interviewer Anita Wuttke, as well as the two board members Dr Stefan Liepe and Dr Wolfgang Neumann (from left).



BDIZ EDI says bye-bye to Brigitte Nötzel (middle), who has been with us for many years. Also in the picture: Helga Karanikas (right). She is in charge of the office in Munich.

printer with compatible post-processing units was also shown at IDS.

The delivery of prosthetic restorations could become easier after this IDS, as a self-adhesive luting composite reduces the number of components required. The original MDP monomer (10-methacryloyloxydecyl dihydrogen phosphate) and the original silane for a strong adhesive bond are already included. This means that only a single component is needed—and no separate primer. This makes clinical use extremely efficient and minimises the potential for errors when permanently cementing zirconia, lithium disilicate, hybrid ceramic or metal alloy crowns and bridges.

In implant prosthetics in particular, a thin (60 µm) single-use pressure sensor with a red colour coating now makes it possible to detect incorrect loading. The distribution of the patient's chewing forces is digitally recorded at 256 pressure levels and transmitted via Wi-Fi to an iPad app for further evaluation. As a result, complications associated with unbalanced occlusal pressure during chewing or due to bruxism can be prevented from the outset.

### Help is close where space is at a premium

Developments in orthodontics are largely driven by the integration of digital com-

ponents—right up to through to the use of bending robots. Many other details make treatments easier, such as new retainers for a customised, patient-specific fit. The digital design also takes into account space constraints. After approval, the retainer is milled 1:1 from a titanium blank. This ensures maximum wearing comfort due to the high accuracy of lingual fit and smaller adhesive surfaces, which in turn allows for improved and easier oral hygiene. The material (titanium grade 5) is also suitable for patients with nickel allergies.

For acute CMD symptoms, immediate relief is now available in the form of a temporary splint that can be directly inserted. They relieve mandibular movement restrictions or compensate for occlusal interferences, tackling the root causes of problems that originate in the jaw but can quickly spread through the rest of the body.

The splint also serves as an initial diagnostic tool. If symptoms are significantly reduced within 24 hours, a neuromuscular cause can usually be assumed.

In the field of aligner therapy, a new composite material with just the right amount of flowability facilitates the precise filling of templates—no excess, no voids, correct positioning. Fluorescence in UV-A light helps. Artefacts, excess material and residues are visualised and quickly removed without damaging the enamel.



“Making of”: The perfect technical support for the live interviews was provided by Christian Neumann and Dr Stefan Liepe.

In their final report, the organisers provided figures that do not quite reflect the fact that medical device manufacturers are facing major bureaucratic hurdles as a result of the EU's Medical Device Regulation (MDR). With 1,788 exhibitors from 60 countries and 120,000 trade visitors from 162 countries, IDS is returning to the “old” or pre-COVID days. According to the organisers, the “world's largest leading dental trade show” again covered the entire field of dentistry and dental technology in 2023.

So how do the organisers, the Association of the German Dental Industry, the Society for the Promotion of the Dental Industry and Koelnmesse, sum up the impact of IDS 2023? “This year's claim, ‘100 years of IDS—shaping the dental future’ is synonymous with the outstanding significance of the trade fair today and in the future,” said Mark Stephen Pace, Chair of the Association of the German Dental Industry (VDDI). Oliver Frese, COO of Koelnmesse, added: “For five days, we experienced an IDS that more than lived up to its claim as a leading international hub. [...] The outcome of the event is all the more remarkable given the current challenging geopolitical environment.”



Everyone wants to spin the wheel of fortune!



# Go beyond.



## The new Surgic Pro2

Operability, safety, wireless extensibility: these are the crucial points where the brand new Surgic Pro2 makes the difference. The NSK surgical micromotor system represents an extraordinary innovation, designed to give the professionals the best device, for the most effective, reliable and comfortable work experience. There are so many good reasons to choose Surgic Pro2 – the brilliant progress, that lets you go beyond.



**1** Improved operability thanks to the new, more compact motor and the center of gravity moved closer to the head of the handpiece: more comfort, less stress.



**2** Safe and sensitive display thanks to the easy-clean screen and the smart touch panel, to be adjusted to respond when surgical gloves and surgical barrier sheets are in use.



**3** Superb visibility thanks to the large, back-lit, high-contrast LCD panel. The display can be adjusted with 10 brightness levels and its intuitive icons allow for smooth operation.



**4** High-resolution color LED light to let you see blood and gums as if naturally-lit and therefore give you increased visibility during treatment, generating a minimal amount of heat.



**5** Silence and smoothness thanks to the irrigation pump, that provides consistent and steady flow while fitting seamlessly in the compact design.



**6** Highest torque accuracy made possible by the optimized torque calibrations system AHC: maximum safety against torque exceeding during implant setting.



**7** Predictability and control to enhance decisions about when to load the implant, especially when a shorter treatment time is given, thanks to the dialogue with Osseo 100+.



**8** Wireless extensibility with multiple devices such as VarioSurg3, Osseo 100+, wireless foot control and iPads, to significantly broaden the scope of implant treatments.

Interview with Dr Tina Mandel, University of Cologne, about her dental app

# Diagnosis the digital way

Dr Tina Mandel, senior physician at the Clinic for Oral and Maxillofacial Surgery at the University of Cologne, has developed an app for patients that answers their dental questions before they visit their dentist. In an interview with Anita Wuttke and with “test user” Christian Berger, Mandel explains the idea behind her app.

## **Dr Mandel, what is your app all about?**

**Mandel:** The app helps people who cannot or do not want to go to the dentist in person to digitally record their dental problems and send the resulting data to the dentist. The dentist then evaluates the data within 24 hours and writes a medical report. The patient is diagnosed and receives a treatment recommendation via an entirely digital route. If the patient’s concern can be addressed remotely first, such as by writing a prescription or prescribing an antibiotic, this can be done directly through the app. However, the app is in no way intended to replace the dentist, as most dental issues need to be addressed at the dentist’s office. The app is a low-threshold way for patients who need dental help to contact their dentist.

## **What is the story behind this idea?**

I am active on social media in my role as a dentist. For two years now, I have used

my TikTok account to educate users about dental issues. It started with the realization that there was just too much misinformation being spread on social media. I wanted to counter this by offering professional information to people who are looking for solutions to their dental problems online. Interestingly, people ended up not only looking at my content, but also sending me private messages. Even though I had never directly offered any kind of digital consultation, I received a huge number of messages, with photos of their mouths and teeth and simple requests for advice. This taught me that there was a great need out there for dentists who can be contacted digitally. I created my app to meet that need.

## **Is your app already up and running?**

The app is not yet available to everyone. We are in the test-flight phase, i.e. the app is fully developed and tested and

has been released by Apple in the App-Store...

## **...What exactly does test-flight mean?**

The app can only be downloaded by approved users. This is what we are doing at the moment to make sure that the app really works flawlessly and can be used by anyone who wants to. We will be ready in a few weeks.

**We have someone here who has already tested the app—Christian Berger, dentist and president of BDIZ EDI. I am sure he will be able to tell us if the app works?**

**Berger:** Yes, it certainly works! We dentists are also constantly learning throughout our professional lives. I believe that telemedicine and teledentistry will be an important part of dentistry in the future. We dentists have to get used to these developments. But dentists can certainly make diagnoses quite quickly and reliably based on short videos or on photographs of the patient’s mouth, as long as the patient provides a few key details. This app puts patients on a safe path to a clear and reliable diagnosis. We will always have some patients who are deeply afraid of going to the dentist. As you said, Dr Mandel, an app like this can be a low-threshold offer. If only to reassure the patient that no, not every toothache requires an immediate extraction. It tells me that I can go to the dentist’s office, where the problem can be fixed quickly, and then I will be relieved of my pain. I think this is an important way for patients to get a diagnosis without having to sit in the dentist’s chair.



Anita Wuttke and Christian Berger spoke with Dr Mandel at IDS 2023.

A second important area I have in mind is the treatment of patients needing nursing care, whether at a nursing home or—and we are talking about a very large number here!—at home, being cared for by relatives. In both cases, it is helpful to use an app like this to make a diagnosis before you have to move that patient from the nursing home to the dentist's office or bring the dentist to the patient's bedside. For us dentists, it is important to know how to treat in advance, because then we can decide whether we can treat the patient at the bedside or whether we need to take the patient to a fully equipped dental office.

**Dr Mandel, how exactly does your app work?**

**Mandel:** The core aspect of the app is the patient's detailed medical history, which is critical to our dental diagnosis. The app is designed for patients—so that they can enter their data themselves. There is no need for a professional nurse or dental assistant to do this. Once the app is launched and the user has given legal consent, it goes straight to the heart of the matter, the questionnaire, which starts dynamically and follows a certain dynamic logic—patients are not asked to answer the same questions over and over. Rather, the follow-up questions are based on the answers already given. In other words, patients work their way towards their own diagnosis based on the ques-

tions and their answers. In this way, it is possible to collect specific data on relevant dental symptom patterns. To help us locate the affected site, we have developed a 3D model of the head and teeth with right/left markings to help patients orient themselves and locate the problem area.

As an additional tool for us dentists, we decided to use video. The smartphone's camera automatically focuses while taking a video, which is not the case with still images. In addition, the app automatically uses the flash of the rear camera so that the patient's mouth is always illuminated. This way we almost always get nice visual results.

So much for data collection. Patients are guided through creating a profile and then returned to the main menu, where the case is displayed along with its processing status. At this point, the data is transmitted to a live dentist in the background, who has received a signal and will evaluate the case within 24 hours. Patients receive push messages and see their report and treatment recommendation in the main menu, and a prescription if necessary. If they still have questions, they can use the chat function.

**Does the app cost money or is it free for patients?**

The app itself is free to download. However, due to the high development costs, intensive use is not free at the moment.

**Have you contacted health insurance companies?**

Yes, we have contacted major health insurance companies, and our discussions are already at an advanced stage.

**Back to the "test user". Mr Berger, how easy is it to use the application?**

**Berger:** The developers have obviously put a lot of effort into this application. Dr Mandel has already said that this is an intelligent application, which means that patients are guided in the right direction by their own answers. It is no secret that a diagnosis costs between 30 and 40 euros, about the same as a haircut, but you know that for that kind of money you do not always get a dental or medical diagnosis that is really helpful. In fact, it costs many times more for a bedridden patient to travel to a dentist's office than it does to use this app. If we can save a patient a trip to the dentist in the future because the diagnosis is something like you bit your cheek or tongue and it will heal without a dentist, then this app has provided value to that patient and to society. Personally, I find it fascinating that you can reach an individual diagnosis very quickly by asking questions. I have been able to verify that the conclusions are in line with the dentist's diagnoses. I think that there is a lot of potential in this for a lot of different patient groups.

**Dr Mandel, are there other similar apps?**

**Mandel:** In the field of dentistry, this is actually the first app anywhere. There are comparable apps in general medicine.

**Thank you very much for your interesting comments. We will certainly stay on the ball!**



In this interview, Dr Tina Mandel presents the app she developed for remote dental diagnoses.

The interview was recorded live at IDS Cologne. The video is available on the BDIZ EDI YouTube channel.



Meet Prof. Jörg Neugebauer

# President-elect of the Academy of Osseointegration

He was the second European, after Michael Norton, to become a member of the prestigious AO, the Academy of Osseointegration in the United States. Now Prof. Jörg Neugebauer (Landsberg, Germany), Secretary-General of BDIZ EDI, is in the starting blocks for the highest office in the AO as President-elect. He will be the first President from Germany of this internationally leading association. In this interview, he outlines the importance and goals in the AO.

***Professor Neugebauer, what are the challenges and the importance of the AO? How does this differ from comparable European professional societies?***

With over 4,000 members in more than 70 countries, the Academy of Osseointegration is considered the leading international association in the field of oral implantology. Since its inception in 1982, it has been characterised by a high level of practical relevance. This is no doubt due to the fact that most academics in the US consistently maintain a private practice and therefore remain in touch with day-to-day challenges. For example, the Academy of Osseointegration has always been concerned with the importance of patient and staff management, which other professional organisations are only beginning to recognise. The AO specifically brings together professionals with diverse interests and backgrounds to advance scientific research and best clinical practice in implant dentistry. Implantological specialists and general dentists come together to provide optimal patient care using the latest evidence-based science and methods. I like the motto of the AO: we have the specialists, but the work is done in clinical practice, so we need to support this in the best possible way.

***How does someone from Germany get to be President-elect of the AO?***

I am a native of Germany, from the Baden region, but because I was so enthusiastic about the practical approach of the AO, I have attended all their meetings since 1995 and then became one of only 100 Fellows—with only two Germans following me so far, Professors Fouad Khoury and Christian Mertens.

I have repeatedly presented my scientific results, even winning the prize for best poster presentation in 2002, and have been able to participate in many committees of the AO in addition to my research activities at the University of Cologne. For example, I was a member and then Chair of the Clinical Innovations Committee. During this time more than 200 participants attended my sessions at the annual meetings.

The AO is not only practice-oriented, but also performance-oriented: You do not become President just by spending enough time as a member of the academy; you have to prove yourself by successfully contributing to the various committees. I have also been able to take an active part in one of the international AO summits, held every four years on a specific theme.

Thus, I will have the pleasure of succeeding Professor Hom-Lay Wang as President of the AO in Charlotte in 2024 and of playing a major role in shaping the 2025 Annual Meeting in Seattle.

***What is the most hotly debated topic in oral implantology in Europe? Is this different from the situation in the USA?***

You would think it should be obvious, but in fact it is only now that patient-oriented outcomes—the benefits of treatment to the patient—are coming to the fore. The dental industry and academic teaching will have to adapt to the fact that practitioners are increasingly demanding simplified treatment procedures. Our generation still grew up with construction kits that taught us elementary mechanical techniques. Later generations have usually not had the opportunity to learn about the “mechanics of me-

chanics” in this playful way. Younger people expect straightforward mechanisms and techniques.

“What’s the data?” used to be a ubiquitous question when something new was introduced. But this is also much less common among the younger generation. Methods or techniques that do not carry the ballast of a long history and start directly into digital mode may well have an easier time of it today.

This is not to deny the importance of sound research and evidence-based approaches, but they will always have to face the question of how quickly and easily they can be implemented in practice. Rather than drifting off into the realms of artificiality, there will be much more emphasis on what works or does not work in real life. That is actually something that I find extremely attracting about the American approach, something that we in Germany and Europe can certainly learn from: you have to perform and to convince others of your approach, but once you have done that, things are implemented very quickly.

***What goals have you set for yourself as the future President of the AO?***

Of course, I can use the situation to personally build a bridge between Germany, Europe and the USA, to promote and expand mutual exchange and cross-fertilisation—for example simply by being Secretary-General of BDIZ EDI and a member of other professional associations such as EDA, EAO and many more. In addition, under my presidency, the Annual Conference will be given a completely new format. We will have an even stronger international focus, we will specifically involve the younger generation and we will put much more emphasis on digital knowledge transfer. Last but not least, as Associate Editor of *JOMI*, I am very keen to do even more to combine research and practice in this internationally respected journal.

***Thank you for your insightful answers.***

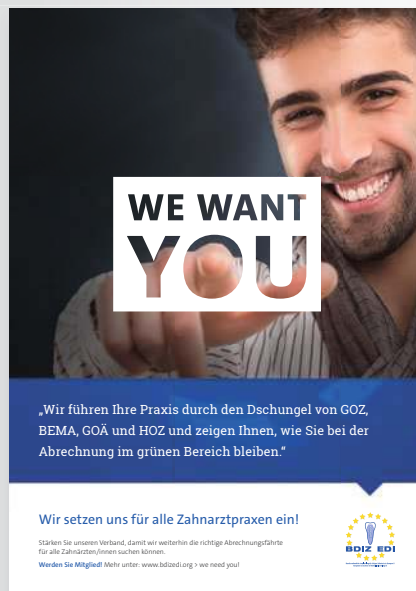EB



## BDIZ EDI and its multifaceted work

# We want YOU!

At IDS 2017, BDIZ EDI launched its “We want you” information campaign. The aim is to interest young dentists from Germany and Europe in oral implantology and in the work of BDIZ EDI. These efforts have been intensified at IDS 2023.



have adopted, and adapted, the modules for their countries: Greece, Serbia, Poland—and soon even India.

- Each year, the BDIZ EDI Expert Symposium provides an update on a current issue in implant dentistry, and the associated European Consensus Conference (EuCC) provides guidance for practitioners.
- The Europe Symposium of BDIZ EDI provides an opportunity to look beyond the local dental fence and to appreciate the work of European colleagues and exchange ideas. This year’s Europe Symposium took place in June in a villa near Verona in cooperation with OEMUS MEDIA.

### A wide field

The full scope of BDIZ EDI’s work is illustrated by the “BDIZ EDI informs” webinar series, which the association has been organising since the start of the COVID-19 pandemic in 2020. The continuing-education webinars feature top-notch presenters and cover dental topics (not just implantology!) as well as legal issues. The webinars are particularly suitable for strategic practice orientation for current and future practice owners. BDIZ EDI webinars are aimed at dentists and all members of the dental team. Participation is free of charge for members. On average, BDIZ EDI webinars are attended by between 150 and 400 participants. Members can view the recorded webinars in the seminar archive after the live broadcast.

With the “We want you” campaign, the association wants to draw attention to the many different support services it offers for all dental practices, even beyond implantology, including continuing education for newcomers to the profession and seasoned practitioners alike.

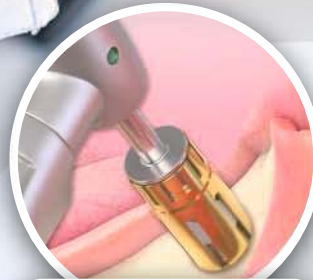BDIZ EDI is an active Europe-wide association that in 2002 went beyond the borders of Germany to forge collaborations, support partner associations and make its voice heard in EU politics. Of course, health policy interventions are also initiated at the federal level. BDIZ EDI is the only association to have presented its own draft law on combating corruption in the health sector. It is currently working intensively on the Medical Device Regulation (MDR) and its many problems.

With its information offensive, BDIZ EDI is highlighting its work in the field of continuing education:

- “Meet the Experts” allows newcomers to get in touch with experienced implantologists and top lecturers.
- An absolute must for anyone interested in implantology is the Implantology Curriculum, which is run in cooperation with the University of Cologne. This eight-module course teaches the key building blocks of implant dentistry to small groups of participants. The curriculum takes place at the University of Cologne. It runs for one year and is designed to be affordable for newcomers to the profession. It is planned to start the Curriculum South in Munich later this year. Some partner associations

AWU

# For Implant Stability & More



Autogenous Bone

**A-Oss**

Osteoconductive  
bovine bone substitute

Xenograft

**Q-Oss +**

Synthetic,  $\beta$ -TCP major  
Biphasic Calcium Phosphate

Alloplast



Titanium Mesh

**OssMem\_Soft**

OssMem Collagen Membrane

Collagen Membrane

**EAO**  
EUROPEAN ASSOCIATION  
FOR OSSEointegration

**BERLIN 2023**  
**RELOADED**


30<sup>th</sup> EAO annual scientific meeting  
37<sup>th</sup> DGI annual congress

September 28th - 30th 2023



**Stand C25**

Industry forum Thu 28th | 10:30-12:00

Hands-on  Fri 29th | 9:00-11:30 and 14:00-16:30

**DIAMOND SPONSOR**

**OSSTEM**  
IMPLANT



## 16<sup>th</sup> Europe Symposium and Giornate Veronesi 2023

# A versatile mixture

Under the Italian sun, implantology and modern dentistry were on the agenda in the best weather in Valpolicella/Italy. The Giornate Veronesi 2023 once again offered a varied mix of scientific lectures, seminars as well as table clinics and scored a lot of points with the supporting programme. As an official cooperation partner of OEMUS MEDIA AG and the 16<sup>th</sup> Europe Symposium, BDIZ EDI was also in attendance.



The BDIZ EDI was available to answer all questions from the participants.

In mid-June, the Giornate Veronesi opened its doors for the third time at the congress resort VILLA QUARANTA TOMMASI WINE HOTEL & SPA in Valpolicella. The BDIZ EDI was there for the second time, providing the latest information on oral implantology. This year, the numerous participants were once again able to experience an interesting programme.

### Blood concentrates topic

Friday morning was dedicated to the pre-congress programme. As a premiere, a combined theory and hands-on course with Prof. Dr Dr Dr Shahram Ghanaati (Frankfurt am Main, Germany) and colleagues was held on the topic of obtain-

ing and producing blood concentrates—a current trend in regenerative dentistry. At the same time, Iris Wälter-Bergob (Merschede, Germany) focused on the topic of documentation in her seminar and showed how this can be properly and, above all, legally implemented in the dental practice and what the possible legal consequences are in case of negligence.

The main conference started with a lecture by Prof. Ghanaati, who spoke about improved wound healing in hard and soft tissue using autologous blood concentrates and explained biological and pharmacological factors for success in regenerative dentistry. Afterwards, the participants had extensive opportunity to discuss various special topics in modern dentistry





Exciting exchange among colleagues at the Table Clinics.



The lecture hall was well filled.

with proven experts and to look beyond their own horizons in a relaxed atmosphere and with typical Italian finger food and wine.

The first day of the congress ended with an awesome open-air get-together in the garden of VILLA QUARANTA, inviting participants to get to know northern Italy in its most beautiful form: with evening sun, wine, and conversation. The collegial exchange of experiences between participants, speakers, and the industry partners, coupled with very personal encounters, worked very nicely.

### Implantology and tooth preservation

On Saturday, the congress started with scientific lectures including two separate focus podiums: implantology and tooth preservation. The topics of the implantology panel, under the scientific direction of Prof. Dr Ralf Smeets (Hamburg, Germany), ranged from complications in implantation and augmentation surgery to peri-implantitis and implant ageing to single-tooth restoration with ceramic implants and the question of how to get through the daily routine of information, documentation, and treatment with legal certainty. The dental preservation panel, under the scientific direction of Prof. Dr Thorsten M. Auschill (Marburg, Germany), looked at topics such as periodontitis and risk factors, dental trauma treatment in daily practice as well as fluorosis treatments and vitality preservation of teeth.

In the subsequent interdisciplinary panel on soft-tissue management in daily practice, Prof. Smeets, Dr Theodor Thiele (Berlin, Germany) and Prof. Auschill mainly discussed central issues such as gum problems and their causes, suitable treatment approaches as well as do's and don'ts in implantology and soft-tissue management.

The parallel place taking team programme with Iris Wälter-Bergob was dedicated in detail to the topic of hygiene in the dental practice as well as MDR (Medical Device Regulation) and showed a comparison between BEMA and GOZ.

The absolute highlight at the end of the second congress day was the dinner party in the pool area of VILLA QUARANTA, where live music and a DJ, dinner and a long Italian night with good music, dancing and, of course, intensive discussions created a wonderful holiday atmosphere.

Source: OEMUS MEDIA AG



The symposium was also a culinary highlight.



A live band provided the best party atmosphere in the evening.

## Instagram, Facebook, Twitter, YouTube

# BDIZ EDI on social media

Facebook, Instagram, Twitter and YouTube are the most popular social networking channels. BDIZ EDI uses these platforms to keep its own members and the members of partner associations, as well as all users interested in oral implantology, informed.

“In addition to Facebook, YouTube and Twitter, Instagram has become another important component of our social media activities”, says Dr Stefan Liepe, Managing Director of BDIZ EDI. “We want our channels to provide impartial information, both nationally and internationally, that is free of third-party interests. BDIZ EDI regularly provides information on implantology and topics relevant to dental practices in the areas of law, billing and prac-

tice hygiene. Of course, we also provide links to interesting professional articles and exciting behind-the-scenes insights about our association, which is active in Germany and in Europe.”

The online seminars that BDIZ EDI launched at the height of the COVID-19 crisis can be viewed on the YouTube channel. The latest information can be found on Instagram, Twitter and Facebook. BDIZ EDI often plays a pioneering

role when it comes to scrutinising laws and regulations that affect dentists—even taking cases to the German Constitutional Court if necessary. It intervenes in health policy on behalf of all dentists at the German and European level.

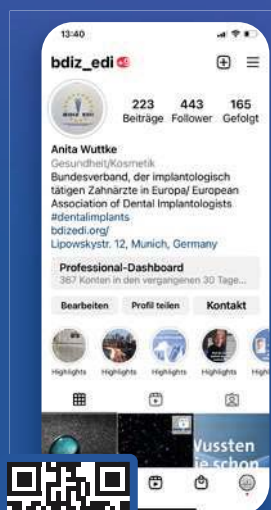At IDS 2023, BDIZ EDI will provide up-to-date news via its social media channels.

AWU

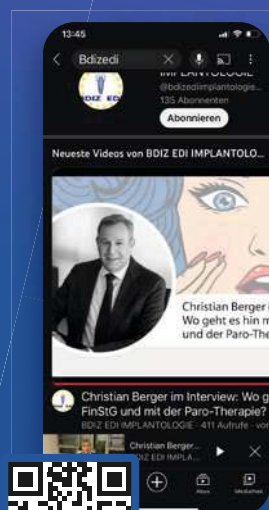## BDIZ EDI on social media:



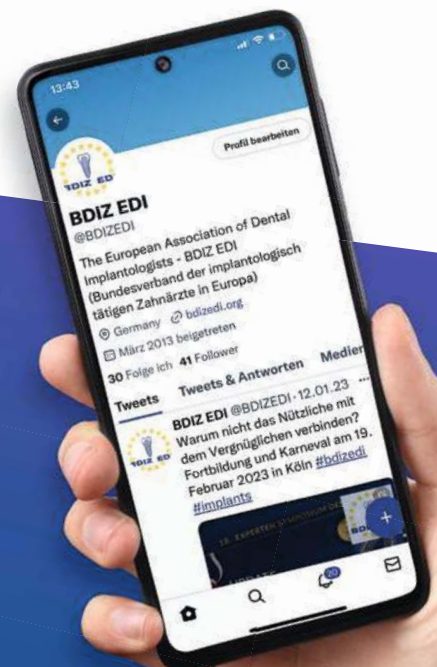Facebook  
@bdizediorg



Instagram  
@bdiz\_edi



YouTube  
@bdizediimplantologie7192



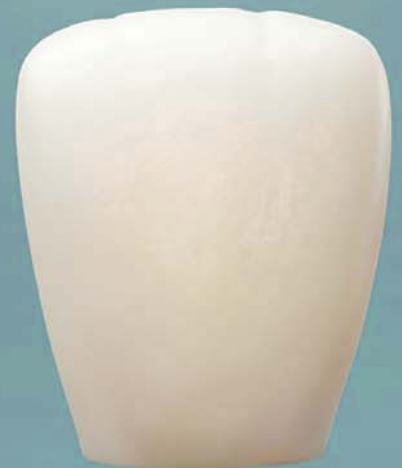Twitter  
@BDIZEDI

## No peri-implantitis after 9 years

Independent long-term study (University of Düsseldorf)

Brunello G, Rauch N, Becker K, Hakimi AR, Schwarz F, Becker J. Two-piece zirconia implants in the posterior mandible and maxilla: A cohort study with a follow-up period of 9 years. Clin Oral Implants Res. 2022 Dec;33(12):1233-1244. doi: 10.1111/clr.14005. Epub 2022 Oct 31. PMID: 36184914.

- Healthy soft tissues (12.9% BOP)
- Stable bone levels (MR < 1 mm)
- No implant fractures



### The New Standard



Long-term oral health: Patent™ redefines success in the first long-term study on two-piece zirconia implants. Learn more: [www.mypatent.com/scientific-studies](http://www.mypatent.com/scientific-studies)



## International Implantology Congress in Nepal

# Oral implantology in the Himalayas

After almost three years of delays by the Corona pandemic and several forced cancellations, the Nepal Society of Implant Dentistry (NSID) ventured a new start. Now it could finally take place in Kathmandu in April 2023. BDIZ EDI was there as a cooperation partner.



The NSID Board with Dr Sybille Keller, President of Dentists Without Borders, and Christian Berger (middle) on the podium.



“Embracing the Future” was the topic of the Congress.



Christian Berger: How long-term success in implant therapy can be achieved.

The Nepalese Society of Implant Dentistry (NSID) had invited BDIZ EDI and two speakers, Christian Berger and Prof. Jörg Neugebauer, to the congress in Kathmandu.

More than 250 dentists and trade partners from several countries including Nepal, UK, India, China, USA, Australia, Germany, and Romania attended the event. Sixteen international speakers shared their expertise and provided evidence-based guidelines and a consensus for better patient care.

In her welcome address, NSID President Dr Rita Singh spoke about Nepal’s journey in providing dental implants to the Nepalese population and the importance of oral health for the whole body, highlighting the multiple effects of oral disease on general health.

As the first speaker of the two-day congress, BDIZ EDI President Christian Berger presented consensus recommendations for every dental practice to achieve long-term success in implant therapy. Secretary General Prof. Jörg Neugebauer demonstrated how digital technologies can bring about improvements in implant prosthetics.

### A lot of public attention

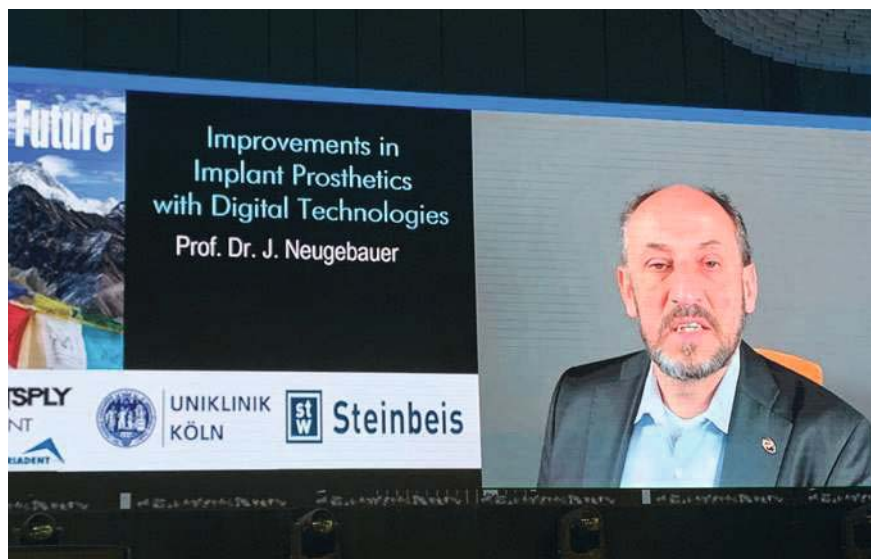The congress was an outstanding event—not only for the NSID board members and other participants. The public was at least as much interested in the event as the dentists were. The media covered the congress every day, and the *Himalayan Times* interviewed Christian Berger at length about the



The official handover of the speaker certificate in Nepalese.



Dr Rita Singh opened the Congress as President.



Prof. Dr Jörg Neugebauer was connected online.

importance of implantology in patient care.

Also present was Dr Sybille Keller (Waltenhofen, Germany), president and founder of Dentists Without Borders, who continued her work building her dental clinics in Sushma Koirala (Sankhuwashaba district) and Ampipal (Gorkha district). She was warmly welcomed by the Nepalese implantologists. Keller's presence is sure to open up new opportunities for support in the regions where she works.

If you would like to see the TV report or the interview (in English), you can access it via the BDIZ EDI website: <https://bdizedi.org/embracing-the-future>



AWU Participants in the auditorium.

## 32<sup>nd</sup> Expert Symposium on Regenerative Procedures in Dentistry

# Concepts of prosthetic care

For the 32<sup>nd</sup> time, the Expert Symposium under the direction of Prof. Joachim Zöller (Cologne) will take place on Fuerteventura this year, bringing together academic research and clinical practice. From 27 October to 3 November 2023, there will be many interesting lectures, leisure and sports at the Robinson Club Esquinzo Playa in Fuerteventura.



The 32<sup>nd</sup> Expert Symposium will focus on different approaches to prosthetic care using implant-supported restorations, from single crowns, implant-supported bridges and the all-on-4/all-on-6 concept to coverdentures and much more. These concepts will be explored and critically evaluated by experienced speakers who offer different solutions for different clinical situations and patient needs. The presentations are designed to help dentists recommend the best treatment options based on the patient's individual situations and plan their prosthetic restorations accordingly.

For more information and to register, please contact:  
**[info@reisebuero-gup.de](mailto:info@reisebuero-gup.de)**



The White Night is a tradition on Fuerteventura.



Lectures take place in the pyramid.





## Position on dental workforce

© yurkaimortal – stock.adobe.com

# Recommendations for national governments

The Council of European Dentists (CED) adopted policy recommendations on solving imbalances in dental workforce numbers and distribution, calls for robust measures to improve current status quo. This is the result of the General Meeting of CED in Stockholm in May 2023.

On 27 May 2023, the Council of European Dentists (CED) delegates discussed and adopted unanimously the “Position on dental workforce” during their General Meeting in Stockholm, Sweden. The meeting was held under the Chairmanship of CED President Dr Freddie Sloth-Lisbjerg and was kindly hosted by the Swedish Dental Association (Sveriges Tandläkarförbund).

CED Vice-President Dr Anna Lella who is also Chair of its Board Task Force Internal Market that developed the Position together with Working Group Education and Professional Qualifications, welcomed the adoption. Dr Lella highlighted the crucial need for continuous work on this complex issue that impacts the dental profession of today and tomorrow alike. The Position is based on the existing CED White Paper on workforce challenges for dentistry that the General Meeting adopted in November 2022. It sets out the CED’s position and recommendations regarding the multi-layered issues related to workforce in dentistry.

The status quo corresponds to the overall trend that Europe has been facing when it comes to healthcare professionals. There are a number of factors affecting the planning and distribution of dental professionals between and within some countries—examples include discrepancies in wages and opportunities, the rural versus urban divide, the changing nature of European demographics.

Based on a detailed analysis of this topic, CED recommends that:

- The balance in the relationship between the dentist and the dental team members should be maintained, with the dentist as the team leader. Task delegation and no substitution should be continuously encouraged, with the permanent supervision of the dentist.
- Workforce planning must begin at the national level, and all countries should be equipped and prepared to educate and train the right number of dental professionals for their own needs.
- National dental chambers and associations must have a strong role in the workforce decision-making and planning at country level.
- Education is of crucial importance for solving the issue: it is therefore recommended for national governments to consider increasing the publicly funded dental courses if there is a need for more dentists within their specific health systems.
- Universities should offer expanded education and trainings for dentists, incorporating skills such as digital skills and managing a practice and a team.
- EU policymakers should also prioritise the update of the Annex V.3/5.3.1 of the Directive 2005/36/EC (Professional Qualifications Directive) introducing competences. As a minimum, the update of the subjects listed would ensure more up-to-date relevance to current dental education.





AD

# HAMBURG FORUM FOR INNOVATIVE IMPLANTOLOGY

22-23 SEPTEMBER 2023

- The recognition of dental qualifications (as per Directive 2005/36/EC), obtained outside the European Union must be complete and in accordance with the applicable EU requirements before a dentist may start practising dentistry for the first time in the European Union.
- Prevention should continue being prioritised and promoted within national healthcare systems, ensuring a reduction of costs, reducing the burden of disease and improving public health as a whole. Prevention programmes for oral health must acknowledge that dentistry goes far beyond caries treatment. Prevention and oral health literacy should be encouraged through supranational initiatives in support of current and future national level actions.
- Better oral health means better public health. As such, national governments must prioritise the creation of policies supporting adequate remuneration (e.g. fair prices for the services performed) for dentists in all European countries.
- National governments should ensure that, as part of their health workforce initiatives and strategies, there are policies that also support appropriate workload, continuing education, favouring retention of the dental workforce. Furthermore, national governments should offer an expanded set of incentives, e.g. spouse career opportunities and children's education, that favour retention of the healthcare workforce in terms of geographical distribution, especially in relation to rural dentistry/dentistry in remote areas. This also includes regulations and financial incentives to influence the choice of practice location for new dentists.

Read more: CED Position on Dental Workforce



REGISTER  
NOW!

[www.hamburger-forum.info](http://www.hamburger-forum.info)



## Europe Ticker +++

European Health Data Space (EHDS)

### Interoperability and the connected healthcare system

At the EU level, discussions are well underway on the European Commission's proposed regulation to create a European Health Data Space (EHDS). The aim of the EHDS is to connect national healthcare systems in an interoperable way to enable the secure transfer of healthcare data. Patients should be able to access their minimum data sets (MDS) across the EU, such as prescriptions, lab results, X-rays, discharge reports and vaccination records. In addition, health data should be made available for secondary use in health research or policy-making. In a comprehensive position paper, the German Dental Association (BZÄK) welcomes the plan, but on the condition that the current principles of informational self-determination, data protection and data security are maintained. In addition, dental practices should not be burdened with additional duties—staff shortages are already severe enough. If practices incur extra costs, they should be fully reimbursed.

Public good research based on health data should be facilitated but should be based on structured data suitable for answering specific questions and be made available at reasonable cost.

Source: German Dental Association

#### Dental chains in Spain

### Patients abandoned

With treatments paid for in advance but never completed, many dental patients in Spain are facing closed doors. Several dental chains—iDental, Funnydent, Dental Line, Dentix and since March also Smydent—have ceased operations. The consumer organisation Facua speculates that these chains are bankrupt. Patients will probably have to go to court to get back the money they paid in advance for incomplete treatments.

Speaking at the spring meeting of the Federation of European Dental Competent Authorities and Regulators (FEDCAR) in early May, Óscar Castro Reino, President of the Spanish Dental Association, renewed calls for the effective application of a long-standing law that requires any company providing dental services to be in the hands of dentists and subject to the ethical principles of professional law. In this context, the association pointed out that one of the owners and founders of Smydent is not a dentist, and once again called on the Ministry of Health to respond appropriately to prevent further scandalous developments of this kind.

In addition to the clinic in central Madrid, Smydent also had clinics in Torrejón, Alcorcón and Leganés, San Blas, Vallecas and Badalona. The affected patients are now planning to file a class action lawsuit against the chain.

Source: zm, Germany

### Artificial intelligence put to the test

## Is ChatGPT better?

According to a study conducted at the University of California at San Diego, ChatGPT provided better answers to patients' questions almost eight out of ten times. Experts rated the chatbot's responses as being of higher quality and more empathetic. The study compared written responses from physicians to real-world health questions from an online forum with those from ChatGPT. To obtain a large and diverse sample of health questions and physicians' responses that did not contain identifiable personal information, the team turned to social media where millions of patients publicly post medical questions to which physicians respond: Reddit's AskDocs. The team randomly selected 195 exchanges from AskDocs in which a verified physician responded to a public question. Of these, 182 consisted of a single question and a single answer. In the remaining 13 cases, the doctors wrote two separate responses. The team submitted the original question to ChatGPT and documented its answer. A panel of three qualified health professionals from paediatrics, geriatrics and internal medicine assessed the quality and



emphatic nature of the (blinded) replies. In nearly 79 per cent of the 585 assessments, raters preferred the chatbot's responses to the physicians' responses. The percentage of responses perceived as "good" or "very good" was higher for the chatbot than for physicians (physicians: 22.1 per cent, 16.4 to 28.2 per cent; chatbot: 78.5 per cent, 72.3 to 84.1 per cent). At the same time, the panel was almost 10 times more likely to rate artificial intelligence responses as "empathetic" or "very empathetic" than physician responses (physicians: 4.6 per cent, 2.1 to 7.7 per cent; chatbot: 45.1 per cent, 38.5 to 51.8 per cent).

Source: University of California

### WHO recommendations on oral health

## Networking national strategies globally

The key WHO recommendations to governments in the new report are:

- Develop new national oral health strategies that are consistent with the WHO Global Oral Health Strategy and national strategies for the control of non-communicable diseases (NCDs) and for universal health coverage (UHC); allocate staff and resources to oral health in ministries of health.
- Implement measures to reduce the intake of free sugars, such as mandatory nutrition labelling of pre-packaged foods, setting targets to reduce the sugar content of foods and beverages, enforcing public procurement measures to reduce the supply of sugary foods, taking measures to protect children from the harmful effects of food marketing, and imposing taxes on sugar-sweetened beverages and sugary foods.
- Integrate oral health care into primary health care at all levels of care, with the necessary staffing, skill mix, and competencies.
- Develop an innovative oral health workforce model to meet the oral health needs of the population.

Source: WHO

### 100 years of the Irish Dental Association

## The Irish branch of the BDA

The Irish Dental Association (IDA) is celebrating its 100<sup>th</sup> anniversary. The IDA dates back to 1887, when an Irish branch of the British Dental Association (BDA) formed in Dublin, which split off and became independent in 1922 during the revolution. The IDA was considered the leading voice of the dental profession in the 20<sup>th</sup> century and participated in major public health campaigns, such as the inclusion of dentistry in the health insurance system and the fluoridation of drinking water in the 1960s. More recently, the IDA has been at the forefront of advocating for health insurance reform and raising public awareness of the importance of dental health.

The new (and thus 100<sup>th</sup>) IDA President is Dr Eamon Croke, who was appointed at the beginning of May, replacing outgoing President Caroline Robbins after her one-year term. Croke wants to continue the reforms in dentistry and make continuing professional development (CPD) mandatory for the profession. Over the past 15 years, he said, the number of dentists in private practice had fallen by almost nearly a quarter (23 per cent), leading to an extreme backlog in children's dental examinations.

Source: zm, Germany

## Obituary: Dr Hans-Hermann Liepe

# A leading authority on expert opinions has left us

Dr Hans-Hermann Liepe, retired dentist from Hanover, died at the age of 82 after a short but serious illness. Liepe, who had rendered outstanding services to the German dental profession in professional politics for decades, was chairman of the Expert Committee of BDIZ EDI from 2005 to 2017.

As a member of BDIZ EDI since 1 January 1991, Hans-Hermann Liepe witnessed the very beginnings of the association and influenced its development for many years after being elected Chair of the Expert Committee in 2005. The Expert Committee is one of the most important committees in BDIZ EDI. It is the place where experts in implantology—who serve as consultants and as expert witnesses in legal disputes—are trained. The Chair of the Committee manages the Association's list of experts and, together with the Executive Committee, decides on the topics to be discussed at the Expert Conferences that are held annually on behalf of the Consensus Conference on Oral Implantology.

During his time as Chair of the Implantology Expert Conference, Hans-Hermann Liepe helped define the importance of the implantological expert opinion: "Experts play an important role when new developments occur and new procedures are introduced by evaluating these procedures, amplifying either the acceptance of new treatment methods or their demise. The tenor of all Expert Conferences on Implantology of BDIZ EDI and of the various dental associations is that the experts speak the same language!" Incidentally, not only BDIZ EDI experts are invited to the Expert Conferences, but all the experts on the lists of the specialist associations and societies and of the state dental associations.

During Liepe's tenure, the Expert Conference has developed into a communica-


tion platform for experts. He also underlined the importance of well-trained court experts with the anonymised negative opinions he presented in BDIZ EDI publications from 2012 onwards.

Given the high cost of implant treatment, the amount at stake in litigation can be substantial. As implant treatment requires highly specialised knowledge and practical experience in both the surgical and prosthetic fields, Liepe had always recognised the immense importance of implantological expert opinions in legal disputes involving alleged treatment errors. He therefore attached great importance on the qualifications of the experts on the BDIZ EDI list.

But serving as Chair of the Expert Committee was by no means Liepe's only involvement and achievement in professional politics. In the 1990s he served in an honorary capacity as Vice President and then President of the State Association of Statutory Health Insurance Dentists (KZV) in the German state of Lower Saxony. He was also active in the Lower Saxony Dental Association and its Hanover district office. A highlight of his career was his service as Chair of the Assembly of the German Dental Association from 2010 to 2012. He was a member of the Expert Committee of the KZV for 25 years and served as an expert and senior expert in Lower Saxony.

Hans-Hermann Liepe chaired the Expert Conferences of BDIZ EDI with great aplomb and a sure instinct for the issues. We appreciated his enormous knowledge, not only in the field of oral implantology. His commitment extended to many areas of dental life, and he shaped the profession for decades. We have lost a colleague who was always friendly and open, an accomplished and thoughtful expert who always contributed his ideas for the benefit of his colleagues and the development of oral implantology. He will be greatly missed, and our thoughts are with his wife Ingrid and his family. We will cherish his memory with affection and respect.

Christian Berger  
on behalf of the BDIZ EDI Board



# Did you ever know...



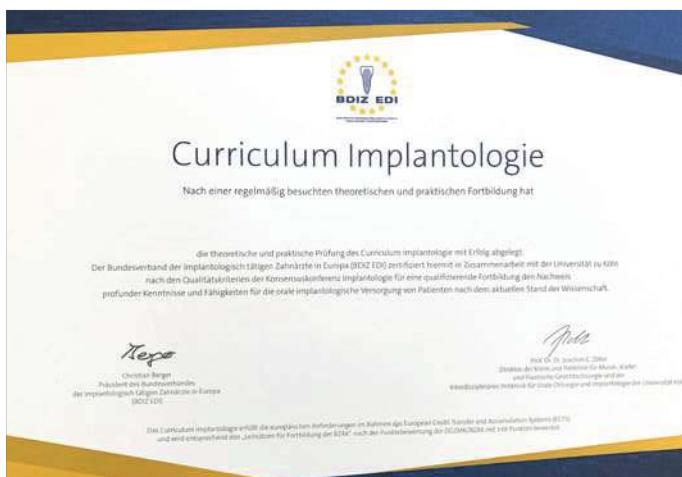## ...that for many years BDIZ EDI

and its partner associations from Europe and beyond, as well as other associations from all over the world, meet once a year to exchange ideas? Mainly at the Expert Symposium in Cologne, the latest in oral implantology news from the different countries is discussed and strategies are developed to promote the discipline.



## ...that the BDIZ EDI

closely follows the Council of European Dentists (CED), which represents the dental associations of all EU member states, through its professional journals *BDIZ EDI konkret* and *EDI Journal*? The work, aims and results of the Brussels-based umbrella organisation of European dentists are regularly presented here.



## ...that the BDIZ EDI

makes the modules of its implantology curricula available to its European partner associations so that they can develop their own country-specific curricula? This has already been done in Poland, in Serbia and in Greece.

Our Munich office will be happy to tell you more:  
office-munich@bdizedi.org

### Judgement of the European Court of Justice in Case C-300/21

# Not every breach of the GDPR automatically entitles to compensation

Starting in 2017, Österreichische Post AG (“Austrian Post”) collected information on the political affinities of the Austrian population. Using an algorithm, it defined “target group addresses” according to sociodemographic criteria. An affected citizen who had not consented to the processing brought an action for damages, initially before the Austrian courts. The Court of Justice of the European Union (ECJ) responded to a request for a preliminary ruling from the Austrian Supreme Court.

The data thus collected enabled Austrian Post to establish that a particular citizen had a high degree of affinity with a particular Austrian political party. However, that data processed was not communicated to any third parties. The citizen in question, who had not consented to the processing of his personal data, claimed that he had suffered great annoyance, loss of confidence and a sense of exposure as a result of having been attributed

a degree of affinity with the party in question. He asked the Austrian courts for compensation in the amount of €1,000 for the non-material damage he claimed to have suffered.

#### **National courts referred to the ECJ**

The Austrian Supreme Court expressed its doubts as to the scope of the right to

compensation for material or non-material damage which the General Data Protection Regulation<sup>1</sup> (GDPR) establishes for infringement. The Austrian Supreme Court asked the ECJ whether the mere infringement of the GDPR is sufficient to give rise to that right for compensation, and whether the non-material damage suffered must reach a certain threshold of seriousness to establish the right to compensation. Furthermore, the Court

<sup>1</sup> Article 15 of Regulation (EU) 2016/679 of the European Parliament and of the Council of 27 April 2016 on the protection of natural persons with regard to the processing of personal data and on the free movement of such data, and repealing Directive 95/46/EC (General Data Protection Regulation) (OJ 2016 L 119, p. 1; hereinafter “the GDPR”).



© projectio - stock.adobe.com

asked the ECJ what Union law requirements exist for determining the amount of damages.

In its judgement dated 4 May 2023, the ECJ stated, first of all, that it is clear that the right to compensation provided for by the GDPR is subject to three cumulative conditions: an infringement of the GDPR, material or non-material damage resulting from that infringement and a causal link between the damage and the infringement. Accordingly, not every breach of the GDPR in itself gives rise to a right to compensation. Any other interpretation would be contrary to the clear wording of the GDPR. In addition, according to the recitals of the GDPR that specifically refer to the right to compensation, an infringement of the GDPR does not necessarily give rise to damage, and there must be a causal link between the infringement in question and the damage suffered in order to establish a right to compensation.

An action for damages therefore differs from other remedies provided for in the

GDPR—in particular those that provide for the imposition of fines, for which the existence of individual damage does not need to be proven. Secondly, the ECJ held that the right to compensation is not limited to non-material damage that reaches a certain threshold of seriousness. The GDPR does not contain such a requirement; such a limitation would be contrary to the EU legislature's broad understanding of the concept of "damage".

Moreover, making compensation for non-material damage dependent on a materiality threshold could affect the coherence of the relevant regime introduced by the GDPR. Indeed, the gradation on which the possibility of obtaining damages would depend could be prone to fluctuations depending on the assessment of the courts involved. Thirdly and finally, the ECJ noted that the GDPR does not contain any rules governing the assessment of damages. It is therefore for the legal system of each member state to lay down the detailed rules governing actions for the protection of the rights which individuals derive from the GDPR and, in particular, the criteria for determining the amount of compensation to be awarded in that context, provided that the principles of equivalence and effectiveness are respected.

In this regard, the ECJ emphasized the compensatory function of the right to compensation provided by the GDPR, noting that this instrument is intended to ensure full and effective compensation for the damage suffered.

## Conclusion

A mere breach of the GDPR does not automatically give rise to a right to compensation. However, nor does the right to compensation depend on the non-material damage suffered reaching a certain threshold of seriousness.

*Source: ECJ press release of 4 May 2023*

## Note

A reference for a preliminary ruling allows the courts of the Member States, in disputes which have been brought before them, to refer questions to the ECJ about the interpretation of European Union law or the validity of a European Union act. The ECJ does not decide the dispute itself. It is for the national court to dispose of the case in accordance with the ECJ's decision, which is similarly binding on other national courts before which a similar issue is raised.



### Investor-owned medical care centres (MCCs)

## “Regulation is legally possible and urgently needed”

The problem is a European one. This issue includes a report (see Europe Ticker) on the situation in Spain, where several investor-owned dental chains have failed their patients. The powerful German Federal Dental Association has issued a statement calling for state regulation of medical care centres (MCCs).

Speaking at the spring meeting of the Federation of European Dental Competent Authorities and Regulators (FEDCAR) in early May, Óscar Castro Reino, president of the Spanish Dental Association, renewed calls for the effective application of a long-standing law that requires any company providing dental services to be in the hands of dentists and subject to the ethical principles of professional law.

The German Medical Association has now issued a statement on a legal opinion commissioned by the Federal Association of Operators of Medical Care Centres (BBMV). Martin Burgi, Professor of Public and European law at the University of Munich, concludes that there are “insurmountable limits under constitu-

tional and European law” to further restrictions on MCC groups. In the case of further encroachments on the constitutionally protected freedom of occupation of MCC operators, he explains, weighty public interest concerns must be taken into account and the principle of proportionality must be observed.

### Incompatible with European law?

Of the ten proposals put forward by the German Medical Association and the German Länder, Prof. Burgi considers four to be constitutionally unobjectionable, such as the ban on advertising for medical concepts or the ban on participation in medical care



© Andrey Popov—stock.adobe.com

governed by state health insurance (SHI) if the freedom of physicians to decide on treatment is not ensured. Similarly, regulatory reviews of SHI contracts or transparency requirements regarding the ownership structures of MCCs do not violate the German constitution or European law.

The situation is different, according to Prof. Burgi, when it comes to limiting investor-owned MCC chains to a radius of 50 km. Nor is the prohibition of MCCs comprising members of the same medical specialty—representatives of one specialty or general practitioners joining forces—justified by sufficiently weighty public interests.

### Statement by the German Medical Association

“Government regulation of investor-owned medical care centres (MCCs) is not only legally possible but also urgently needed from a public health perspective. Such regulation would help to protect MCCs as a sensible healthcare option from the negative consequences of patient care geared to profitability,” said Dr Klaus Reinhardt, President of the German Medical Association, commenting on the results of the expert opinion on the legality of stricter regulation of investor-owned medical care centres.

Reinhardt was referring to the regulatory proposals for investor-owned MCC that were presented by the German Medical Association in January 2023. These proposals are designed to ensure that patient welfare always takes precedence over commercial interests. The German Länder Bavaria, Schleswig-Holstein and Rhineland-Palatinate recently submitted a motion to the Bun-

desrat with the same objective. “The proposals contained in the German Medical Association’s paper and in the Bundesrat motion serve the common good and are constitutionally justified,” said Reinhardt.

In the view of the German Medical Association, medical care centres should be subject to the same rules as SHI contract physicians and for pharmacies. According to the case law of the Federal Social Court, it is necessary for the activity of SHI contract physicians that they are fully and directly responsible to their patients for the treatment itself and its factual and legal framework.

### No external influence

According to the German Medical Association, this requires that SHI contract physicians themselves determine the content and scope of their medical activities and the use of the material and human resources allocated to the practice, independent of any significant external influence. The Pharmacy Act prohibits shareholdings in a pharmacy in the form of a silent partnership and agreements in which compensation for loans made or assets provided to a pharmacist is based on the pharmacy’s turnover or profits. According to the German Medical Association, the same principle should apply to MCCs. The law on SHI contract physicians stipulates that the regulations applicable to these physicians also apply to MCCs.

Reinhardt therefore calls for the following legal clarifications: “The existing restrictions on the group of persons or entities from which the founders for MCCs originate must not be undermined by hospitals that are operated for the sole purpose of establishing a chain of MCCs without actually being interested in providing inpatient care.”

The regulatory framework should ensure high quality and dedicated patient care in MCCs. If maximising return on investment becomes the main objective, preventive measures are needed. Reinhardt: “The provision of healthcare for the population and its financing within the framework of our solidarity-based system is considered by the Federal Constitutional Court to be of paramount importance for the common good. The regulatory proposals of the German Medical Association take this into account. They allow the framework conditions to be aligned in such a way that MCCs continue to provide patients with medically sound care and that their treatments are not dictated primarily by return-on-investment considerations.”

Source: *German Medical Association, 25 May 2023*



Download the original position paper of the German Medical Association (in German).

## Certification as an EDA Expert in Implantology

# Qualification for experienced implantologists

For many years, BDIZ EDI has been catering to experienced and well-versed oral implantologists by offering the certification exam for EDA Expert in Implantology. Jointly with the European Dental Association (EDA), BDIZ EDI regularly invites interested dentists to take the certification exam, which we would like to present in this article.

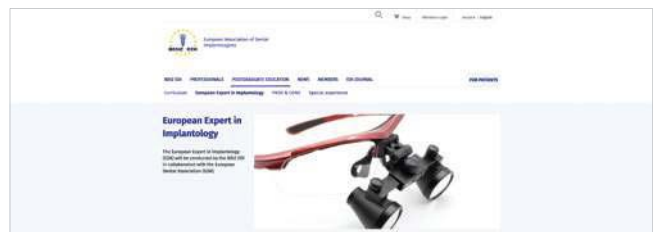That quality is of paramount importance to BDIZ EDI is no secret. BDIZ EDI has demonstrated this in many different areas—legal and accounting, materials testing, postgraduate education, the annual Guidelines of the European Consensus Conference (EuCC) on current implantological issues and finally the qualification of court experts. BDIZ EDI also supports dental education with its Curriculum Implantology that introduces aspiring dentists and young implantologists to this dental specialty in eight well-organised modules.

### Admission requirements for the certification exam

Certification as Expert in Implantology requires very good to excellent skills and knowledge. Candidates must meet the following admission requirements:

- 250 EDA-recognised continuing education/training hours in various sub-disciplines of implantology
- Submission of ten documented, independently performed implantological treatment cases
- At least five years of professional activity, primarily in the field of implantology.

Specific experience and primary activity in the field of implantology must be documented by at least 400 implants inserted and



150 implants restored within the past five years. Candidates who already obtained qualifications in oral implantology (e.g. from other professional societies) may submit the appropriate credentials with their application for certification as EDA Expert in Implantology.

### The exam

Candidates meeting all the requirements will be admitted to the examination. The examination board of BDIZ EDI and EDA consists of recognised specialists. The exam has a theoretical and a practical part, both of which must be completed successfully. The procedure is as follows: The theoretical part of the exam will start with a discussion of the documented cases. In addition, candidates are expected to answer questions related to oral implantology and closely associated fields. The theoretical examination usually takes no longer than 60 minutes; it may be administered to candidates in groups. The practical part of the examination covers one or more recognised, state-of-the-art treatment method or methods and/or treatment plans covering some aspect of oral implantology. Candidates will be informed of the respective topic two weeks before the exam date. Candidates are responsible for providing the required materials and instruments on the day of the exam. The examination as a whole is subject to a fee to cover the cost incurred by the examination board.

New EDA Experts in Implantology are nominated by the president or vice president of the EDA certification committee.

### More information...

To register for the next certification exam, please go to [www.bdizedi.org](http://www.bdizedi.org) and select English > Professionals > Expert or write to the BDIZ EDI office in Cologne at [office@bdizedi.org](mailto:office@bdizedi.org).





**Applicant's address:**

Full name: .....

Full address: .....

.....

.....

E-mail: .....

Date: .....

**Forward by mail or fax to:**

European Association of Dental Implantologists (BDIZ EDI)  
Lipowskystr. 12  
81373 Munich  
Germany

**office@bdizedi.org**

**Fax: +49 89 72069889**

**Certification exam: EDA Expert in Implantology  
Application for accreditation**

I hereby apply for the EDA Expert in Implantology certification exam (EDA = European Dental Association).

I am qualified for this exam as defined below:

Member of BDIZ EDI  yes  no

Member of the following Societies/Associations: .....

I am:  a dental clinician  an oral surgeon  a maxillofacial surgeon

I meet the training requirement of 250 hours of postgraduate education.  yes  no

**Education and experience:**

**Surgery:**

Inserted implants:  less than 400  more than 400

Sinus lift:  yes  no

Close to nerve:  yes  no

Advanced atrophy of the jaw:  yes  no

Soft-tissue augmentation:  yes  no

Bone augmentation:  yes  no

**Prosthodontics:**

Implant-supported restorations:  less than 150  150 or more

During the exam, I will be able to present documentation for 10 treatment cases.  yes  no

I understand that the examination board will review my qualifications and vote to accept or reject my application. Furthermore, I declare that all images I present are my own and that the implants have been inserted and prosthetically restored by me.

.....  
Applicant's signature

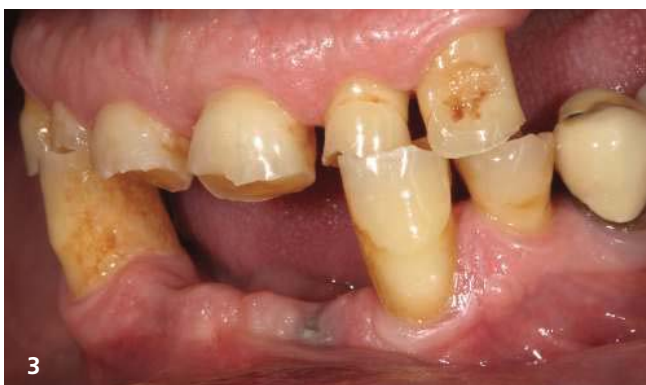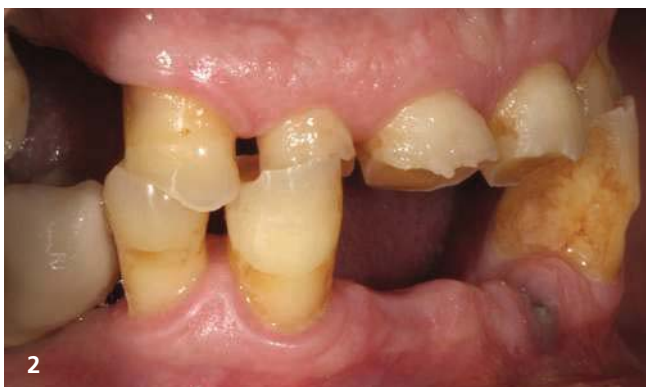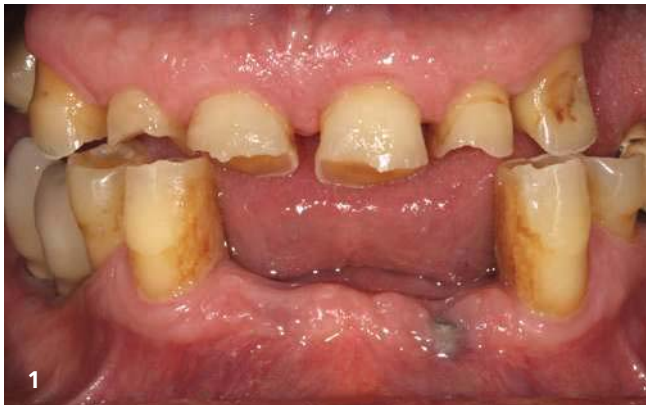.....  
Date

Having successfully passed the exam and paid the requisite fee, I will be certified as EDA Expert in Implantology.

## Multidisciplinary integration of odontology and sleep unit

# Treatment of a patient with severe bruxism, loss of vertical dimension, tooth wear and fracture of dental implants

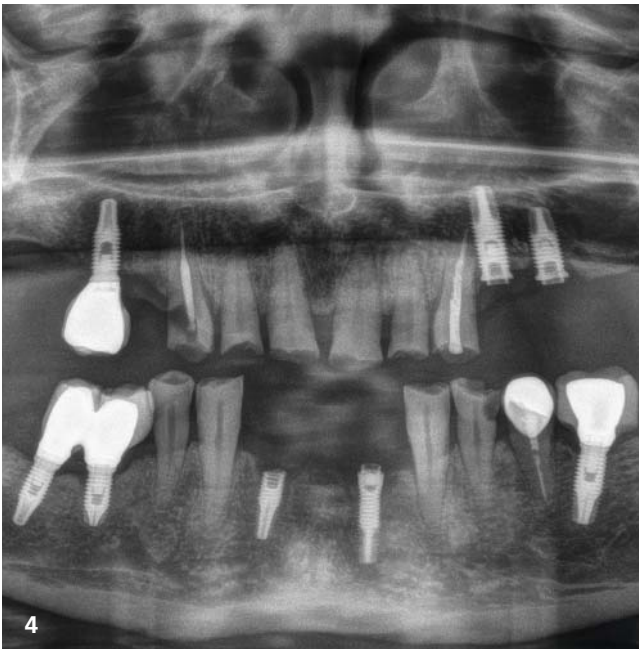
Dr Eduardo Anitua, DDS, MD, PhD, Spain



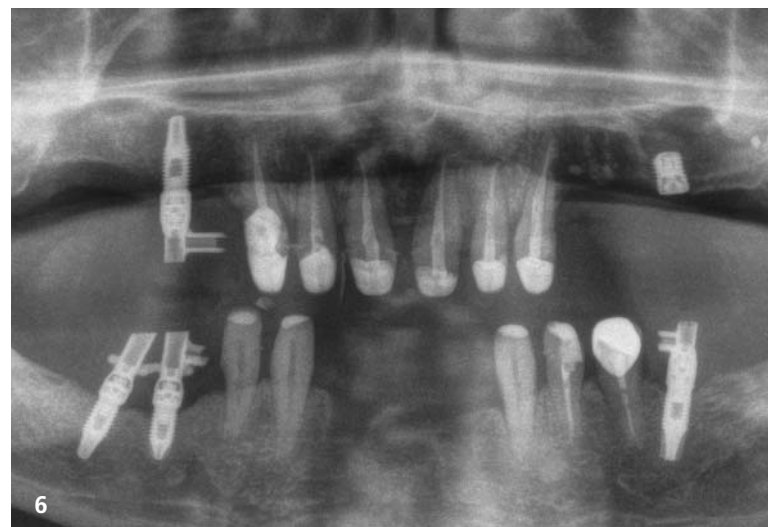
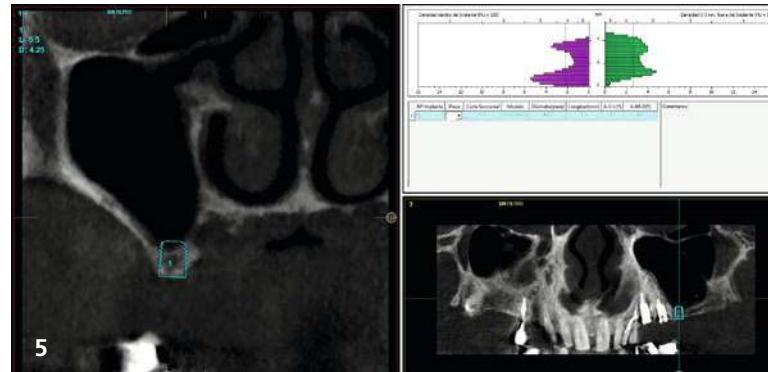
Bruxism can be defined as a repetitive masticatory activity in which teeth are clenched and/or grinded. It is accompanied by other symptoms such as headache, facial and muscular tension in the peri-oral area as well as in the head and neck and sometimes pain in the temporomandibular joint (TMJ).<sup>1,2</sup> It was first described in medical literature in 1907 by Maria Pietkiewicz<sup>1,2</sup> and was related to sleep in the first clinical approach. However later it has been shown that in some patients this habit also persists during the day, in phases of concentration or in moments of stress during daily activity.<sup>2-4</sup> The main consequence of these parafunctional movements, in addition to the consequent distress to the TMJ, is tooth wear and the appearance of fractures and fissures in the dental enamel. The attrition in some patients can be so intense that it exposes the pulp cavities with the formation of irreversible pulpitis and even pulp necrosis, which in many cases requires endodontic treatment of the affected tooth.<sup>1,5</sup>

Bruxism can be accompanied by sleep disorders, as well as body movements, respiratory problems, increased muscle activity and heart rhythm alterations.<sup>1</sup> Sleep disorders comorbid with bruxism include obstructive sleep apnea-hypopnea syndrome (SAHS), parasomnias, restless legs syndrome, mandibular myoclonus and rapid eye movement disorders.<sup>1</sup> SAHS is the sleep disorder most frequently associated with bruxism and other dental parafunctions and is nowadays a clear sign that the patient may suffer from this potentially lethal disorder. This association has been demonstrated in different epidemiological studies over the years.<sup>6-10</sup> Our study group has further shown that the presence of dental wear in patients should result in a detailed analysis of

**Fig. 1:** Initial situation: Extreme wear of the upper arch with areas where dental pulp is practically exposed and moderate wear of the lower arch can be observed, as well as an implant without its crown in the mandibular anterior-inferior area. **Figs. 2 & 3:** Images of severe occlusal wear and collapsed bite, with contact only at the level of the anterior teeth, in addition to the extrusion of some pieces of the lower arch such as canines and premolars.



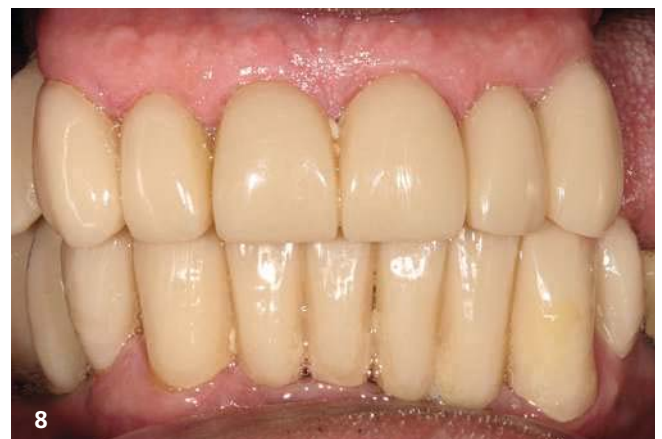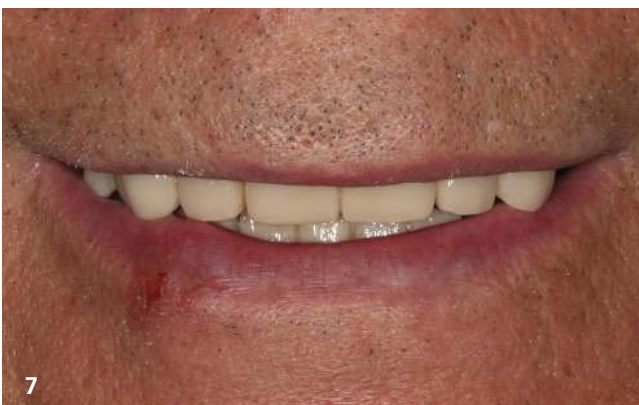**Fig. 4:** Initial radiograph showing several caries in the remaining teeth as well as implants not loaded for different reasons. Fractured prosthetic components inside the connection within the two upper implants and the implant in position 32. Implant in position 42: fractured at the level of the implant crown. **Fig. 5:** Section of the planning CBCT showing how the extra-short implant can be placed in the second quadrant. **Fig. 6:** Panoramic radiograph after upper endodontics, core build-up and placement of temporary resin crowns to raise the vertical dimension.



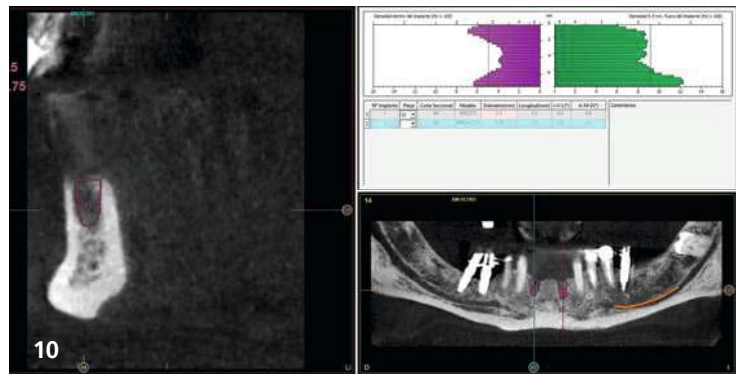
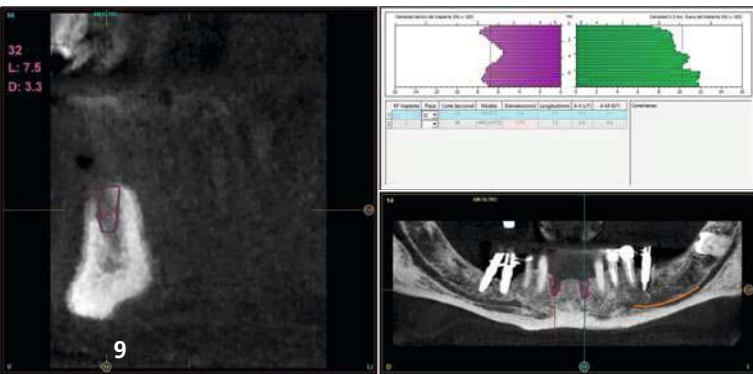
their sleep, since the degree of dental wear is directly related to SAHS by means of the apnea-hypopnea index (AHI).<sup>11-13</sup> This association is directly proportional, and it is confirmed that patients with more severe attrition also have a higher AHI index, which is also associated with a higher incidence of enamel, dental root and prosthesis fractures.<sup>12-14</sup> Therefore, patients with moderate or severe dental wear, high enamel cracks and/or destruction of prosthetic restorations should undergo a sleep study to confirm or rule out the presence of this pathology. This need is twofold: on the one hand it is necessary to know if our patient

suffers from SAHS as it can be life-threatening, and secondly, rehabilitating a patient without solving this problem (if it exists in an underlying form) will lead to the failure of any rehabilitation placed since the presence of SAHS will continue to cause the patient to have uncontrolled episodes of occlusal tension.

The present clinical case shows a patient with extreme bruxism, with a very intense wear of the remaining teeth as well as several fractures of implant prostheses, their prosthetic components inside the implants and even the implants themselves. This patient was analysed both from dental and sleep unit points of



**Figs. 7 & 8:** Temporary situation after elevation of the vertical dimension.



**Figs. 9 & 10:** Planning CBCTs of the implants for the mandibular incisors, showing the area of the removed implants has already regenerated.

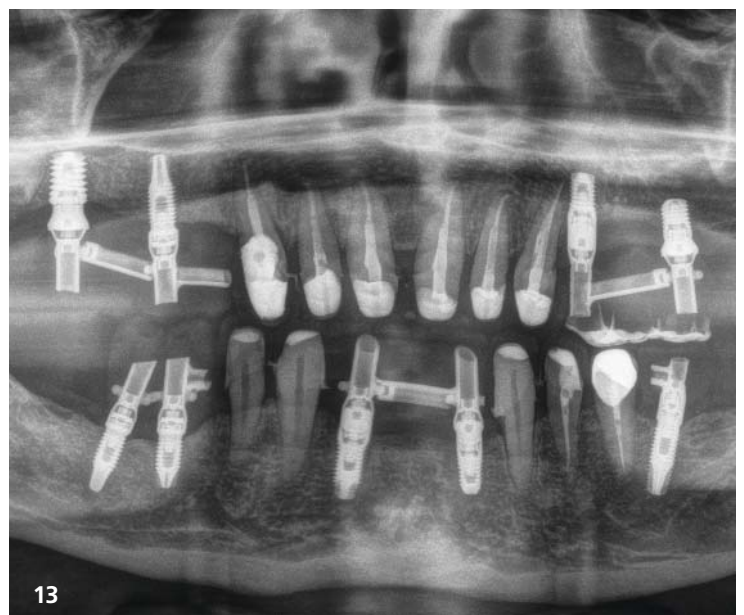
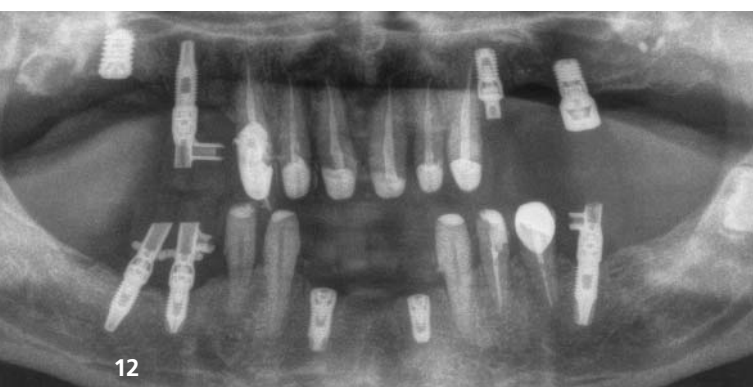
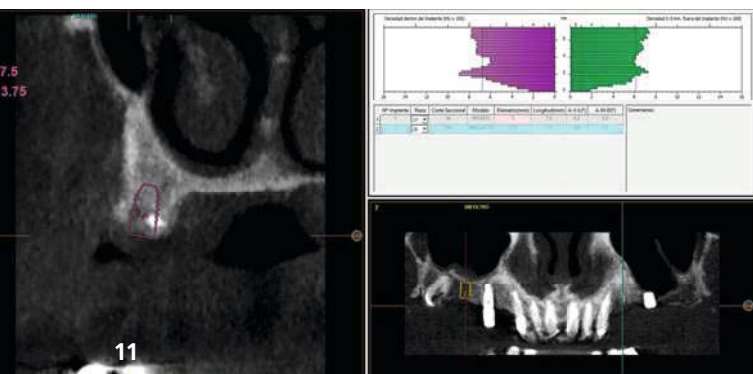
view and a joint treatment from both disciplines has been carried out to ensure the success of the procedure and achieve a substantial improvement in the patient's quality of life.

### Clinical case

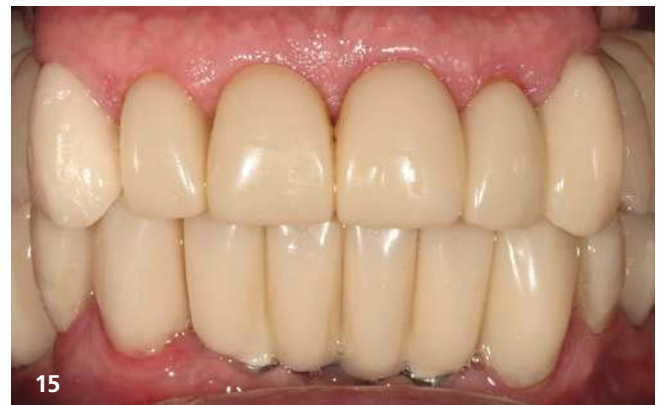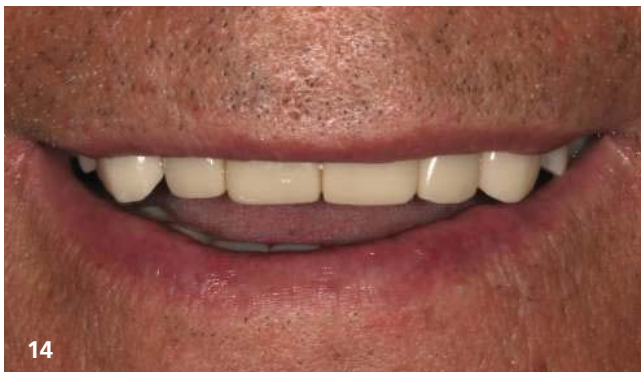The 62-year-old male patient requested treatment for his very worn and highly sensitive teeth, and to replace missing teeth, some of which had already been replaced and the treatment had failed. In the initial examination, moderate dental wear could be observed in the lower arch, and severe dental wear in the upper arch, with areas where the pulp chamber could even be seen through the dentine. In the area corresponding to the lower left lateral incisor a fractured metal component was visible through the gingiva that the patient indicated to be a dental

implant (Fig. 1). In the lateral images, the evident existing dental wear, a collapse of the occlusion with an evident loss of the vertical dimension and an extrusion of the lower teeth leaving part of their root exposed to the oral milieu was observed. These images also showed that the entire occlusion rested on the anterior area (Figs. 2 & 3). The radiograph also showed several implants without loading: two in the second quadrant, with broken prosthetic components inside the implant and two lower implants, with broken components in one of them and a fracture of the implant head in the other implant. There were also several cavities and some restorations on implants that were currently in function without complications (Fig. 4).

Considering the patient's oral condition and other related symptoms (daytime tiredness and somnolence, snoring), the patient was referred to the sleep unit for a respiratory polysomnogra-



**Fig. 11:** Planning of the second quadrant implant placed in the area of previous implant removal. **Fig. 12:** Panoramic radiograph after insertion of the new implants. The patient continued with his provisional prosthesis while waiting for the new implants to be loaded. **Fig. 13:** Radiograph with the new progressive loading prostheses with all implants integrated.



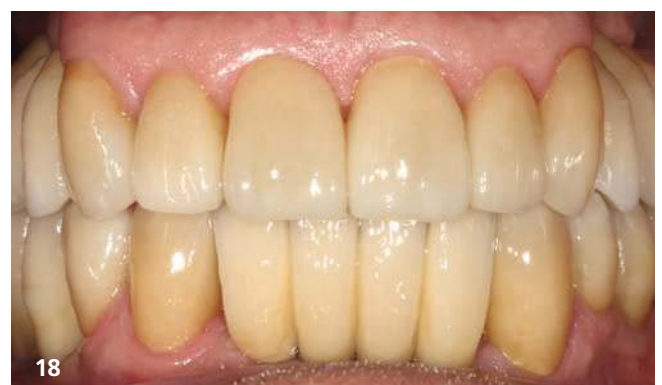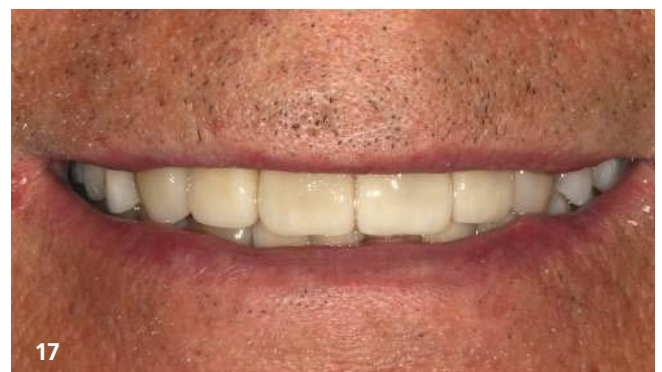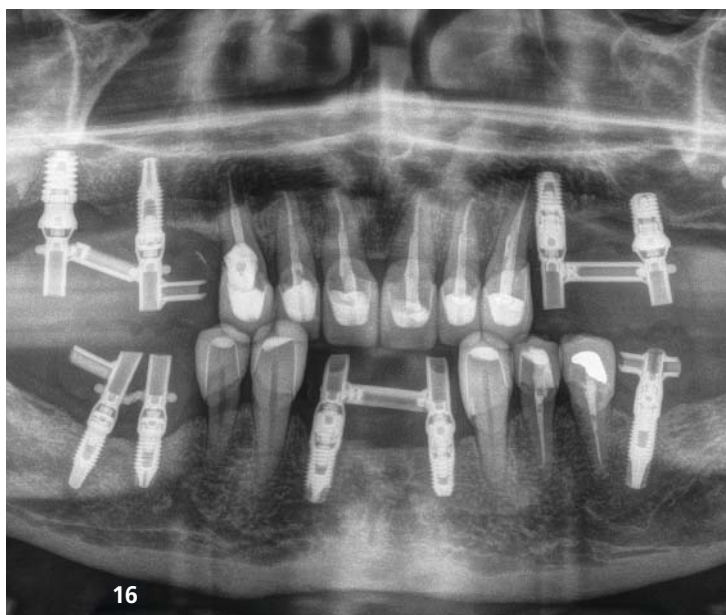**Figs. 14 & 15:** Intra-oral and smile appearance of the second set of provisionals.

phy. The result of the test indicated that the patient suffers from SAHS, with mild apneas, with an AHI of 11.8 (in supine decubitus). Thus, treatment with a mandibular advancement device (DIA-Biotechnology Institute) was indicated once occlusal stability had been recovered to stabilise the device. It was decided to begin treatment by recovering the patient's vertical dimension, for which it was necessary to perform several root restorations in the anterior-superior sector and to place provisional crowns, as well as to replace the current implant prostheses with provisional prostheses with the required increase in height.

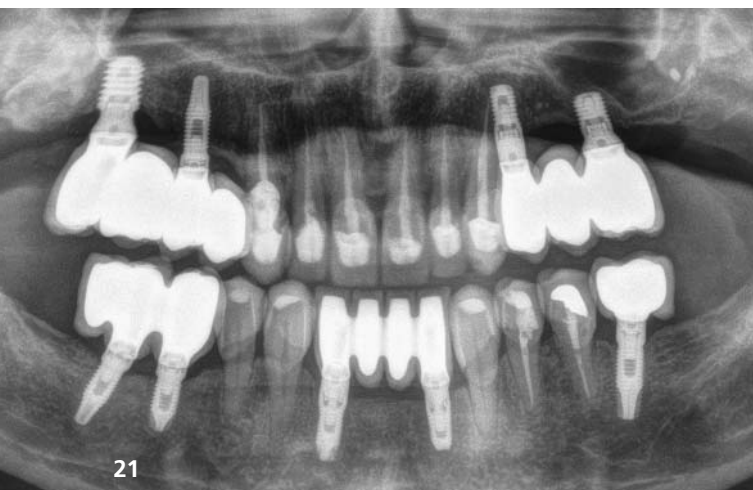
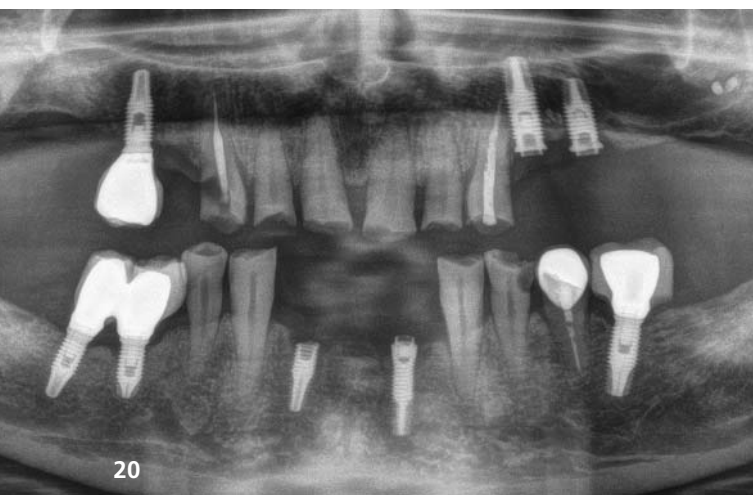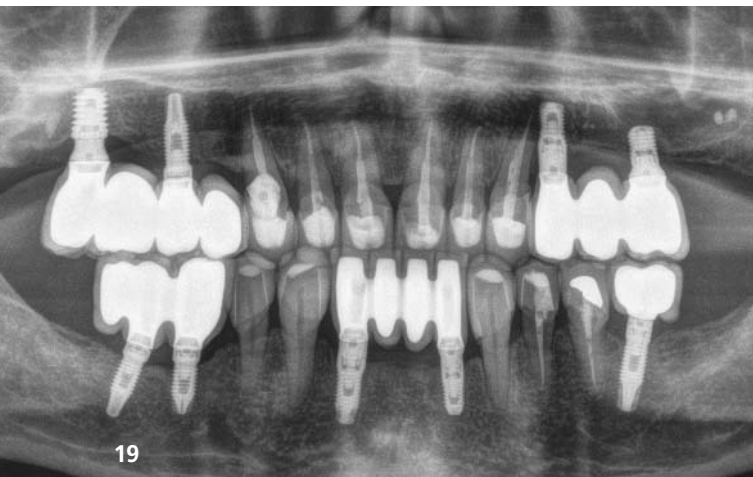In addition, surgery was scheduled to explant all the implants that were unloaded and not recoverable due to serious damage to the internal screw and fractures. Further a distal implant was placed in the second quadrant behind the explantations, which was decided to be an extra-short implant (5.5 mm), thus

avoiding a sinus lift at this level (Figs. 5 & 6) and reducing the morbidity of the process. This first opening of the vertical dimension with provisional prostheses allowed us to configure the final occlusal pattern and to generate a progressive extension of the masticatory muscles which was very contracted (Figs. 7 & 8).

Three months later, the implants could be placed in the areas of the explantations that are completely regenerated. For this purpose, the provisional prostheses were removed, and the implant placement surgery was performed in the lower incisor area (Figs. 9 & 10). The second quadrant area was also ready to receive the implant and an additional implant was placed in the first quadrant for greater stability in the future implant-supported rehabilitation of that area (Fig. 11). The patient continued with the provisionals, waiting for the new implants to be loaded,



**Fig. 16:** Radiograph with the definitive crowns and the provisional prostheses on implants adapted to them. **Figs. 17 & 18:** Clinical images of the final crowns on teeth and implants. The aesthetic parameters achieved in this phase can be observed and the occlusion, vertical dimension and occlusal plane are stable.



**Fig. 19:** Final radiograph of the patient with the complete prostheses and the definitive crowns. **Figs. 20 & 21:** Initial and final radiograph at one year follow-up with total stability of the treatment achieved.

which were scheduled in two surgical phases, while occlusal adjustment of the new vertical dimension continued (Fig. 12).

A further three months later, with the implants perfectly integrated in both the upper and lower arches, a second set of

progressively loaded provisionals was made, including all the upper and lower implants. They were still resin prostheses to allow all the necessary adjustments to be made during these planning phases of the vertical dimension. Implant prostheses were also elaborated with a metallic base structure of articulated bars and the resin with the necessary anatomy was loaded on it (Figs. 13–15). These prostheses also provided the opportunity to carry out the aesthetic adjustments requested by the patient for the final prosthesis.

Two months later, a stable vertical dimension was achieved, and the definitive crowns were placed. These crowns were made of ceramic (e.max) and cemented with resin cement. Once in place, the implant-supported temporaries were leveled for the final provisional phase (Fig. 16). One month later, the definitive crowns for the implants were placed, thus completing the case. The crowns on implants were screwed on multiple transepithelial (Multi-im) in metal-ceramic with metal drilling by CAD/CAM and subsequent addition of the ceramic by hand (Figs. 17–19). The aesthetic parameters achieved in this phase can be observed and the occlusion, vertical dimension and occlusal plane are stable.

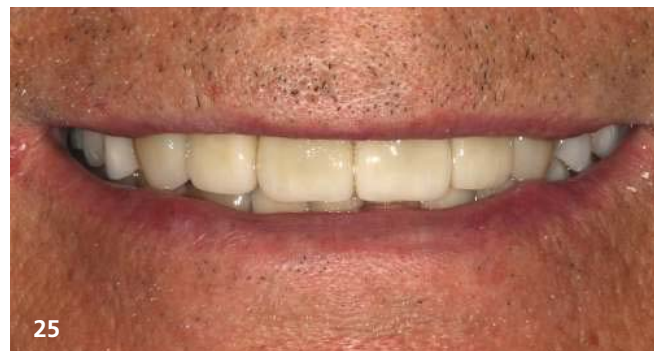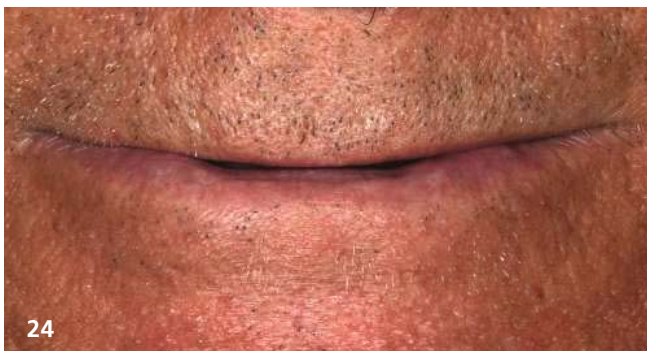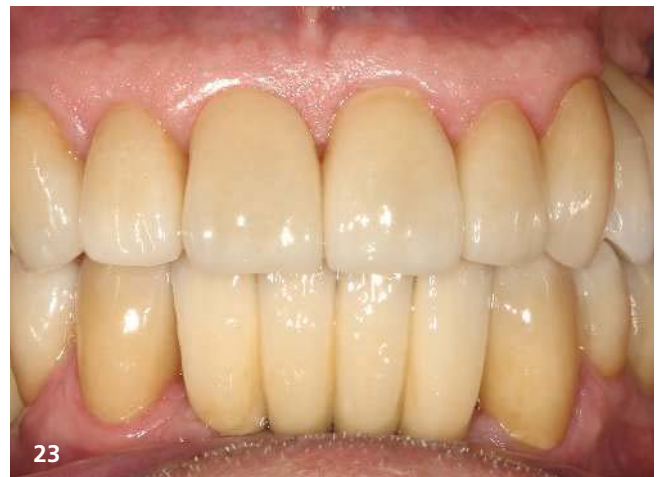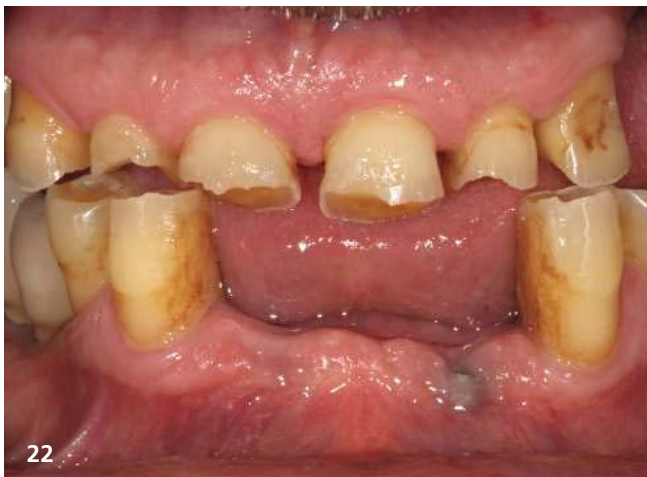At this point the patient was referred to the sleep unit, to treat his SAHS as good anterior and posterior stability and a recovered vertical dimension were achieved. The patient was treated with the mandibular advancement device and after two titrations with a change of tensor (to achieve the minimum effective protrusion) the patient's AHI was reduced to 3. The patient continued to undergo revisions and there were no prosthetic complications or fractures of the rehabilitation components one year later (Figs. 20–25).

## Discussion

It is of vital importance to identify the possible causal factors that have led the patient to a situation of severe tooth wear and to be able to correct the situation from a prosthetic point of view, avoiding the relapse of the situation by addressing all the factors involved, because if only the function is rehabilitated, without paying attention to the parafunctional habits and their etiology, we will be doomed to a new failure.<sup>15,16</sup> It is evident that once the occlusion has deteriorated to the point of generating a bite collapse and vertical dimension, the patient cannot be treated only from the point of view of the sleep disorder, or prevent further wear by rehabilitating the bite, but rather a multidisciplinary approach must be taken addressing all the factors that can influence or prolong the situation. Therefore, approaches that only focus on one of the issues usually fail in the long term in this type of cases, resulting in added frustration for the professional and the patient, who find that time and time again the treatments performed do not produce the desired result.<sup>17,18</sup>

It is also necessary for a correct result of the case not to produce severe muscular distension in patients with such a collapsed bite, considering that the opening action of the vertical





**Figs. 22–25:** Images before and after treatment at one year of follow-up showing the stability achieved and the preservation of the rehabilitation.

dimension produces a great stretching in the masticatory muscles and can generate contractures and imbalances during the reconstruction phase. Thus the more malleable and soft materials such as composite resins and the progressive stretching of the musculature through provisional prostheses can be the key to a correct result.<sup>19–23</sup> Planning is therefore of utmost importance, as in other complex cases, thus avoiding very large openings of the vertical dimension in a short time and the use of definitive prostheses without going through different phases of provisionalisation that allow us to accommodate the articulation, musculature and occlusal pattern.<sup>19–25</sup>

Finally, it is important to bear in mind that patients with significant dental wear should undergo a SAHS evaluation before undergoing dental rehabilitation and that this syndrome should be treated concomitantly once the necessary occlusal support is achieved. Tooth wear should be treated as another sign of possible SAHS and dentists should be aware of it and include it in their differential diagnoses.

## Conclusion

The multidisciplinary approach between the Sleep Unit and Odontology has led to the comprehensive treatment of a patient with severe dental wear and SAHS, and further resulted in maintaining this treatment in the long term.



Literature



Author details



## Contact address

**Dr Eduardo Anitua**

Eduardo Anitua Foundation

José María Cagigal 19, Vitoria, Spain

+34 945 160653

eduardo@fundacioneduardoanitua.org

## Rehabilitation of the edentulous posterior mandible

# Augmentation and implantation in a two-stage approach

Prof. Marcel Wainwright, Luxembourg

Patient demand for fixed tooth replacements is increasing worldwide. However, in order to provide implant-supported restorations for partially or completely edentulous patients, often bone defects resulting from atrophic changes must first be addressed.

In the following, a clinical case is described, in which the author first augmented both sides of the edentulous posterior mandible of a patient and then placed two-piece zirconia implants (Patent™ Dental Implant System, Zircon Medical Management) once the sites had successfully healed. In clinical studies, the implant system used for this case has shown high survival rates, stable marginal bone levels and a favourable soft-tissue reaction, including in grafted sites.<sup>1,2</sup> Additionally, in an independent nine-year study—the first

long-term study on two-piece zirconia implants—it demonstrated healthy and stable hard and soft tissue, no fractures, and no peri-implantitis even in the posterior region, which is subject to higher occlusal loads.<sup>3</sup> Therefore, it is well suited for the indication described in this case.

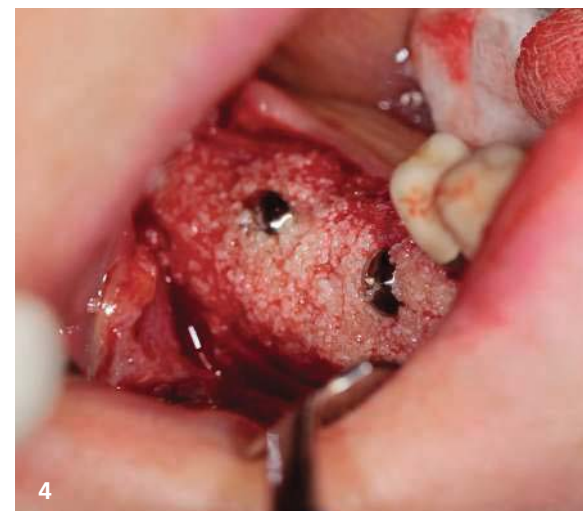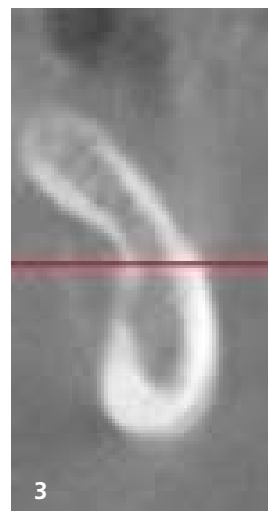
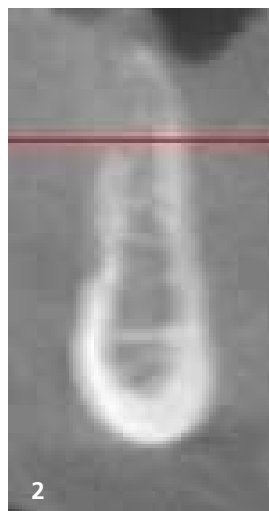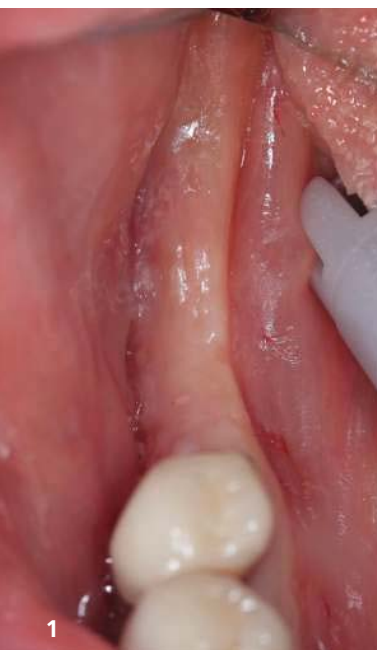### Initial situation

The female patient, aged 57, first presented to the INTEGRA clinic in Luxembourg in the autumn of 2021, complaining about an insufficient removable telescopic restoration in the left and right posterior mandible that had become mobile and impaired her masticatory function as a result. The patient expressed her desire for fixed dental restorations. Clinical examination revealed an atrophied alveolar

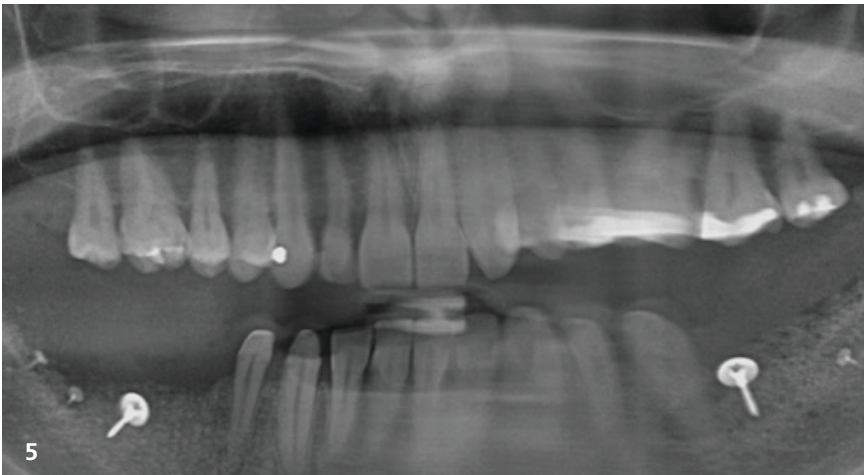
ridge in the left and right molar areas with a relatively high mouth base (Fig. 1). Radiographic examination confirmed that the alveolar ridge was too narrow on both sides to have implants placed immediately (Figs. 2 & 3).

### Preoperative planning

Treatment would first involve bilateral augmentation of the edentulous alveolar ridge using particulate bone grafting material to create sufficient bone volume (particularly in width) for the placement of implants. After successful healing, two-piece implants were planned to be placed in regions #47, 46, 45, 36 and 37 for transmucosal healing. After successful osseointegration, the glass fiber posts serving as prosthetic build ups were



**Fig. 1:** Initial clinical situation of the right side. The ridge was too narrow for implant placement. **Fig. 2:** Initial radiograph of the right side. Cross section at approximately the level where the first implants were to be placed behind the premolars. **Fig. 3:** Initial radiograph of the left side showing the medially converging ridge and substantial atrophy. **Fig. 4:** Intra-op view of the right side during augmentation. Umbrella screws *in situ*.



**Fig. 5:** Radiographic view after augmentation. Radiopaque umbrella screws and titanium pins visible.

planned to be cemented intraorally and restored with single crowns. The surgical treatment was started in February 2022 and completed by the cementation of the final single crowns in January 2023.

### Alveolar ridge augmentation

The patient was prescribed azithromycin (500 mg/day) to start three days before the surgery and continue three days thereafter. The patient's venous blood was collected chairside and processed into autologous blood concentrate (platelet-rich fibrin [PRF] system according to Choukroun). After local anaesthesia, a mucoperiosteal flap was prepared in the left molar area. Two umbrella screws were inserted for spatial stabilisation of the particulate bone grafting material (Fig. 4). Thereafter, sticky bone, a mixture of PRF and porcine bone grafting material (Apatos, OsteoBiol), was introduced into the defect to reconstruct the alveolar ridge vertically and horizontally. A cortical bone lamina of porcine origin (Cortical Lamina hart, OsteoBiol) was placed on top and then covered with a PRF membrane from the patient's blood plasma. Titanium pins were then inserted to stabilise the membranes. Thereafter, the surgical site was sutured closed using a modified mattress suture and an interrupted suture.

The procedure described was repeated for the right molar area (Fig. 5). Additionally, in order to thicken the attached gin-

giva, a tunnel was prepared in this area, into which a resorbable collagen matrix (Geistlich Fibro-Gide, Geistlich Pharma) biologised with hyaluronic acid (hyaDENT BG, Regedent) was inserted. As a result of this, an increase in the volume of keratinised gingiva was observed in this area after healing.

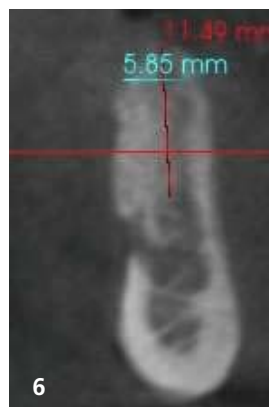### Implant placement

After the successful bilateral reconstruction of the posterior mandible and a complication-free healing period of five months, the second surgical procedure was carried out. At this point, sufficient

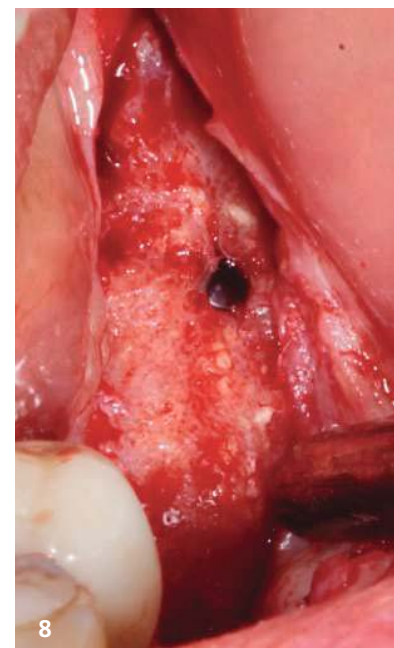
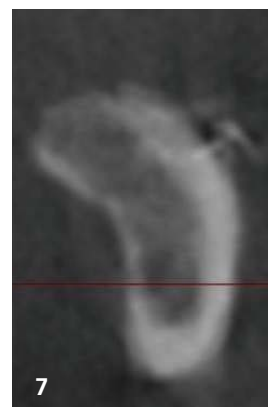
bone volume was available for the placement of the planned implants (Figs. 6–8). After administration of local anaesthesia, osteotomies were prepared in regions #47, 46, 45, 36 and 37 according to the implant manufacturer's surgical protocol, and five two-piece implants (4.5 × 11.0 mm into regions #47–45, 4.1 × 11.0 mm into region #36 and 5.0 × 11.0 mm into region #37) were inserted using the manufacturer's insertion tool and positioned equigingivally (Fig. 9). An insertion torque of 25 Ncm was not exceeded. Thereafter, the 3C connections of the implants inserted were filled with an addition-cured silicone, the sites were sutured, and the implants were left to heal transmucosally.

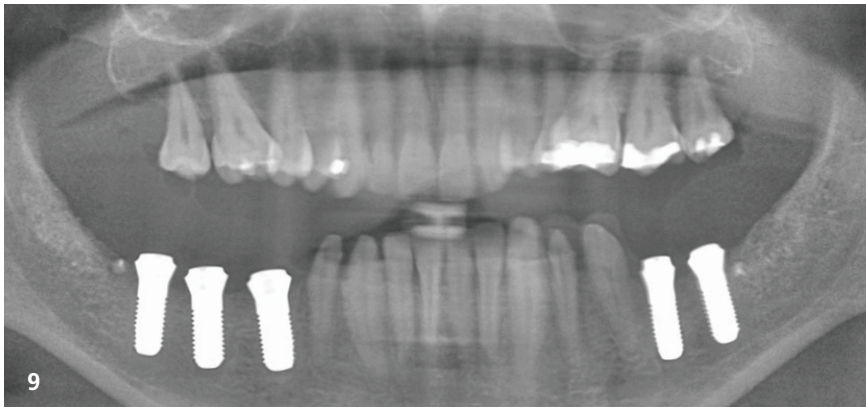
### Prosthetic restoration

After a successful healing period of four months, an intra-oral scan of the entire arch, including the 3C connections of the integrated implants, was taken (3Shape; Figs. 10–12). The implant head serves as the scan body in this process. At this time, healthy and stable soft-tissue conditions were observed around the implants. Based on the scan data, a model was printed in the dental laboratory, the glass fiber posts were prepared on it using analogs for printed models (PMA, Elos Medtech) and the single crowns made of lithium disili-

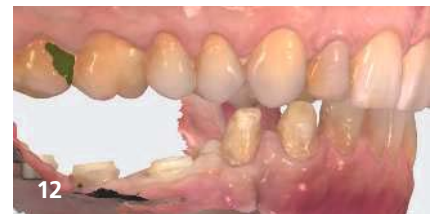
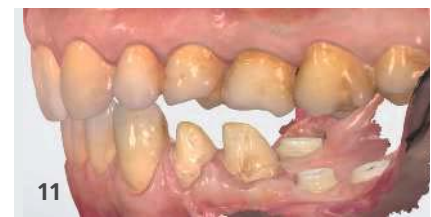
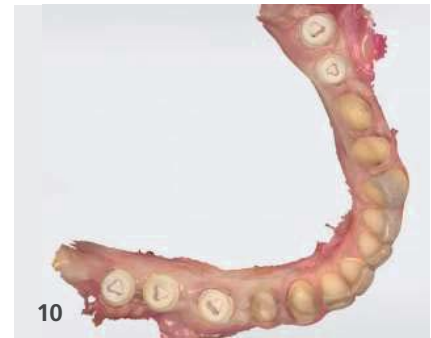**Fig. 6:** Radiograph of the right side five months after augmentation. Cross section showing the reconstructed ridge and well-vascularised and denser bone. **Fig. 7:** Radiograph of the left side five months after augmentation. Cross section showing the broadened jawbone. Titanium pin for membrane fixation visible. **Fig. 8:** Intra-op view before implant placement showing successful reconstruction of the jawbone. Vital and well-vascularised bone.





**Fig. 9:** Radiograph after implant placement (#47, 46, 45, 36 and 37). Due to a lack of space, an off-label use of a  $\varnothing$  4.1 mm implant was chosen for position #36, which is not in line with the instructions of the manufacturer. To compensate for the off-label placement and ensure long-term function, the crown in #36 was sized as a premolar (see Fig. 14). **Fig. 10:** Intra-oral scan of the entire arch, including the implant connections, after four months of healing. **Fig. 11:** Scan of the left side showing occlusion and prepared teeth #34 and 35 for crown placement. **Fig. 12:** Scan of the right side showing prepared teeth #43 and 44 for crown placement and interocclusal distance of the implant connections to the opposing teeth.



cate glass-ceramic (IPS e.max, Ivoclar) were finalised (Figs. 13 & 14). During the next treatment session, the 3C connections of the integrated implants were cleaned, and a dual-polymerising cement (RelyX Unicem, 3M) was applied to the tips of the prepared glass fiber posts before inserting them into the connections (only a small amount of cement was used to ensure that the posts reached the bottom of the connections properly; Figs. 15 & 16). The cement was then light-polymerised under axial pressure. Subsequently, the final single crowns were cemented (Figs. 17–21).

## Discussion

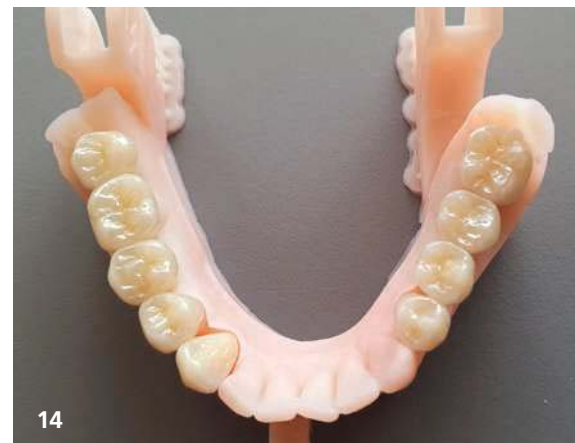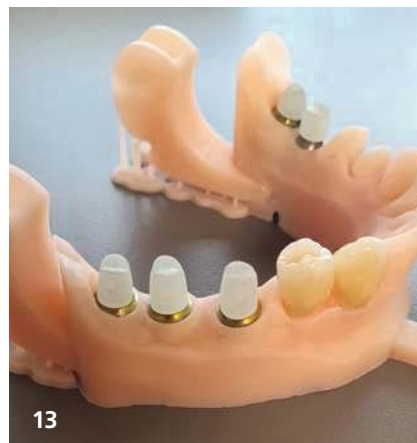In order to avoid stressing the bone in the area of the implant bed, an implant insertion torque of 25 Ncm was not exceeded in this case. If implants are not immediately loaded, there is no need for a higher torque. To ensure that the implants osseointegrate properly, patients must be instructed not to interfere with the area with their tongues, thereby inducing micromovements, and to consume predominantly soft foods for a duration of six weeks after surgery. Osseointegration, that is, implant stability, is measured by means of the Periotest (Medizintechnik

Gulden) after four to five months of healing in the case of augmented bone. If values of  $-3$  or lower are achieved at this time point for the implants, they can be safely restored and loaded.

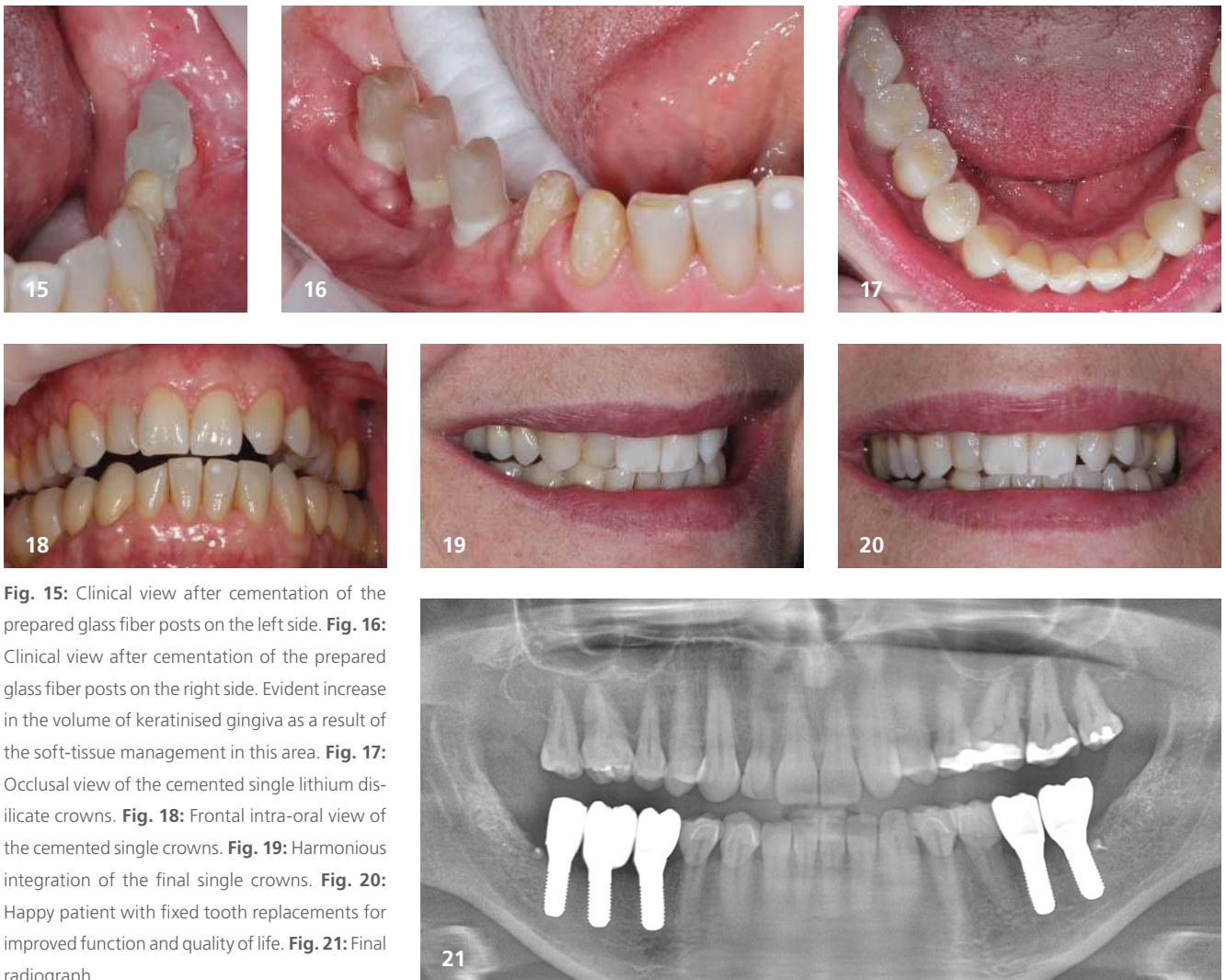In addition, it is vital to insert Patent™ Implants at the equigingival level to avoid compression of the cortical bone and consequently minimise bone resorption or remodeling that would result from placement at a deeper level.<sup>4</sup> Thanks to the very rough endosseous surface of this zirconia implant system, predictable osseointegration can be achieved.<sup>5</sup>

In this case, single crowns instead of splinted crowns were cemented to facili-

tate effective oral hygiene for the patient, particularly with the use of dental floss. However, in some cases, long-term provisional restorations made of acrylic that are splinted and then progressively loaded are recommended as a strategically safe procedure. Furthermore, when prosthetically restoring zirconia implants, strict attention must be paid to reducing occlusal contact points compared with natural teeth (secure canine guidance). An im-



**Fig. 13:** Glass fiber posts prepared on the 3D model using model analogs. **Fig. 14:** Individual crowns finalised on the 3D model using model analogs.



**Fig. 15:** Clinical view after cementation of the prepared glass fiber posts on the left side. **Fig. 16:** Clinical view after cementation of the prepared glass fiber posts on the right side. Evident increase in the volume of keratinised gingiva as a result of the soft-tissue management in this area. **Fig. 17:** Occlusal view of the cemented single lithium disilicate crowns. **Fig. 18:** Frontal intra-oral view of the cemented single crowns. **Fig. 19:** Harmonious integration of the final single crowns. **Fig. 20:** Happy patient with fixed tooth replacements for improved function and quality of life. **Fig. 21:** Final radiograph.

plant–crown ratio of 2:3 to 1:3 should be aimed for.

Moreover, particularly in bruxism and difficult occlusal conditions, a restorative material with physical properties that largely correspond to those of natural teeth should be chosen for the superstructure in order to minimise the risk of chipping. The use of lithium disilicate crowns is recommended, since they offer favourable material properties compared with monolithic zirconia crowns and the material is almost comparable to tooth enamel regarding hardness.<sup>6–12</sup>

## Conclusion

Studies suggest that using porcine bone grafting material can enable reconstruction in a predictable and patient-friendly

way.<sup>13–19</sup> This is corroborated by the results of this case, in which the resulting bone was well structured and vascularised and ideally suited for implant placement. Furthermore, the two-piece implant system used represents a scientifically sound and valid treatment option for fixed dental restorations.<sup>1–5</sup> In an independent long-term study, it was found to maintain the stability and health of the hard and soft tissue in the posterior region.<sup>3</sup> It was therefore ideally suited for the indication described.



## Contact address

**Prof. Marcel Wainwright**  
 INTEGRA Medical Group S.A.  
 2–2A Joseph Leydenbach  
 1947 Luxembourg  
 +352 20 211070  
 marcel.wainwright@web.de

Literature



Author details



# Implant and alloplast synergy in a complex anterior maxillary case

Mark Worthing BDS (Wales), FDS RCS (Eng.), UK

The labial portion of the anterior maxilla provides unique challenges for intra-oral host bone regeneration. The aesthetic zone presents minimal margin for error. This case study demonstrates the use of novel implant design together with  $\beta$ -tricalcium phosphate ( $\beta$ -TCP) particulate alloplast graft material in the anterior maxilla for immediate tooth replacement therapy.

## Introduction

A 27-year-old female patient, non-smoker, with a non-contributory medical history presented with a painful upper left lateral incisor-tooth 22. The symptomatic tooth had been orthograde root treated twice with a subsequent apicectomy with no apparent retrograde filling material. At presentation (Figs. 1–4), the tooth was tender to vertical percussion, with no excess mobility. No increased probing depth or suppuration was noted, either on the affected tooth or elsewhere in the mouth. Marginal gingivitis was noted, localised to tooth 22. A diagnosis of chronic apical periodontitis secondary to suboptimal orthograde root treatment was made for tooth 22 and the tooth was given a hopeless prognosis.

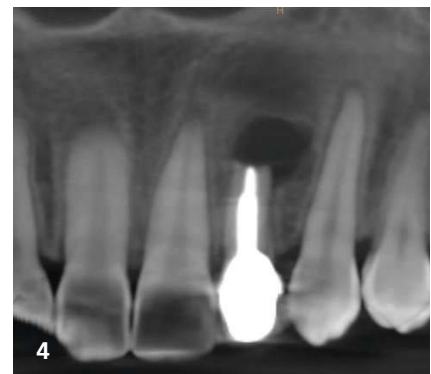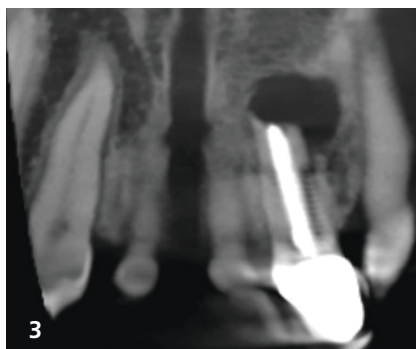
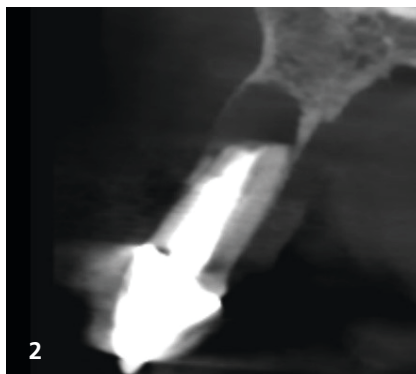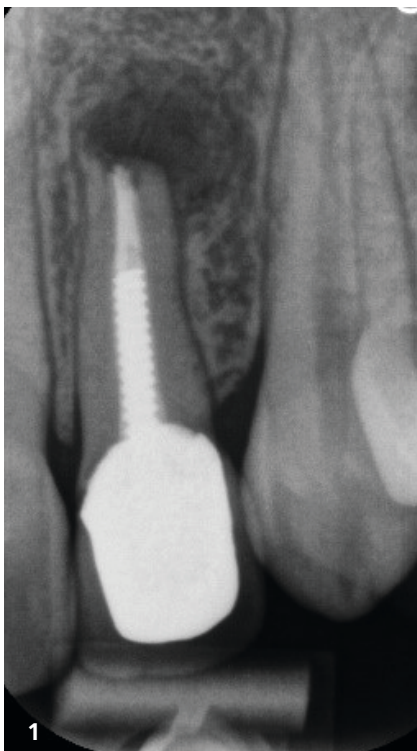
tomy with no apparent retrograde filling material. At presentation (Figs. 1–4), the tooth was tender to vertical percussion, with no excess mobility. No increased probing depth or suppuration was noted, either on the affected tooth or elsewhere in the mouth. Marginal gingivitis was noted, localised to tooth 22. A diagnosis of chronic apical periodontitis secondary to suboptimal orthograde root treatment was made for tooth 22 and the tooth was given a hopeless prognosis.

## Surgical procedure

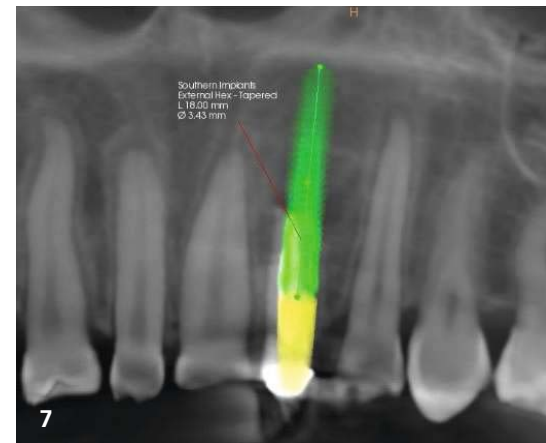
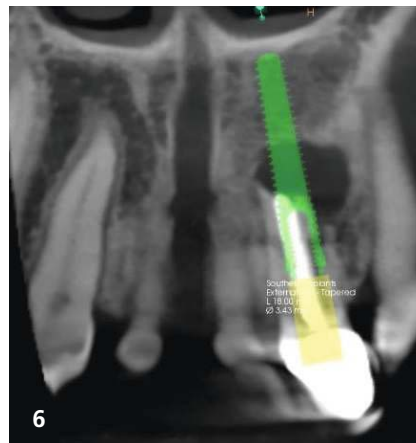
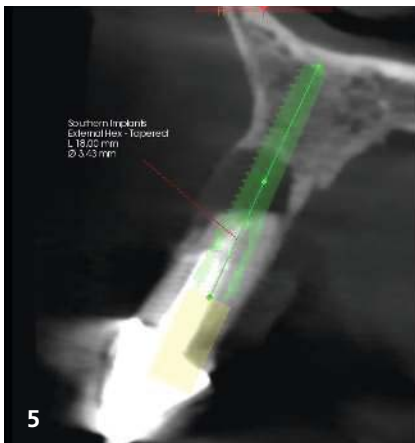
An immediate tooth replacement therapy implant treatment plan was proposed (Figs. 5–7). The initial treatment plan involved the fabrication of a com-

posite shell provisional crown, designed based on the preoperative diagnostic wax up optimised for immediate loading; a pre-extraction, small field, sectional CBCT scan on the anterior maxilla; a minimally traumatic extraction of tooth 22 with meticulous degranulation and sharp curettage; and an immediate implant placement using a novel implant with internal angle correction and a machined coronal surface texture.

A simultaneous bone grafting with an *in situ* hardening synthetic resorbable bone substitute was then used, composed of  $\beta$ -TCP and calcium sulphate (CS), according to Fairbairn and Leventis<sup>1-4</sup> and simultaneous loading of the implant with a composite provisional crown which is modified at chairside.



**Fig. 1:** Periapical radiograph showing failed orthograde root canal treatment with apical radiolucency. **Fig. 2:** CBCT section showing the extent of the radiolucency and the residual bone ridge volume. **Fig. 3:** CBCT showing incisive foramen and its association with affected tooth. **Fig. 4:** Further CBCT view showing adjacent root positions.



**Fig. 5:** Implant planning showing engagement of apical bone. **Fig. 6:** Implant apical portion in bone without engagement of nasal floor. **Fig. 7:** Significant bone volume between implant and adjacent roots.

Presurgical antibiotic prophylaxis with a five-day course of amoxicillin 250mg given three times daily was prescribed. Under local anaesthesia, minimally traumatic flapless tooth extraction was performed (Fig. 8) using a 15c scalpel blade (Swann Morton), periostomes (Hu Friedy Group) and extraction forceps (Hu Friedy Group), ensuring minimal plastic flexing of the intact labial and lingual plates of intact bone. Immediately post extraction the socket and apical defect were debrided of granulation tissue using both Lucus

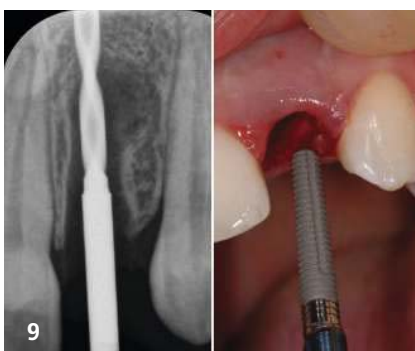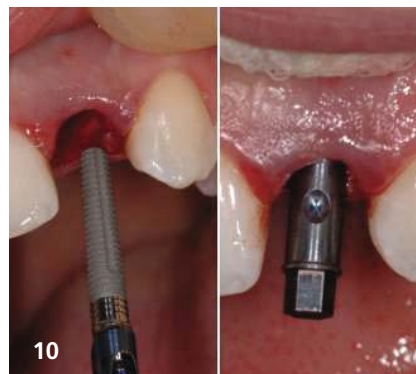
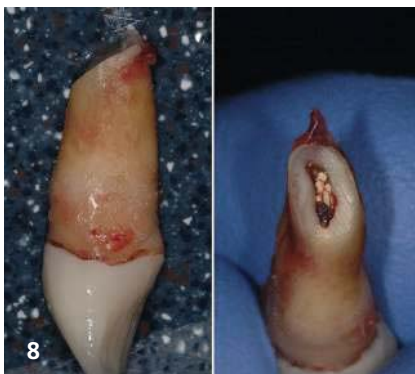curettes (Hu-Friedy Group), degranulation burs (EthOss EK Strauss Degranulation Bur Kit, EthOss), and copious 0.9% sterile saline irrigation.

After completion of degranulation, the socket and apical bony defect were evaluated and both the labial and palatal bony plates were found to be intact.

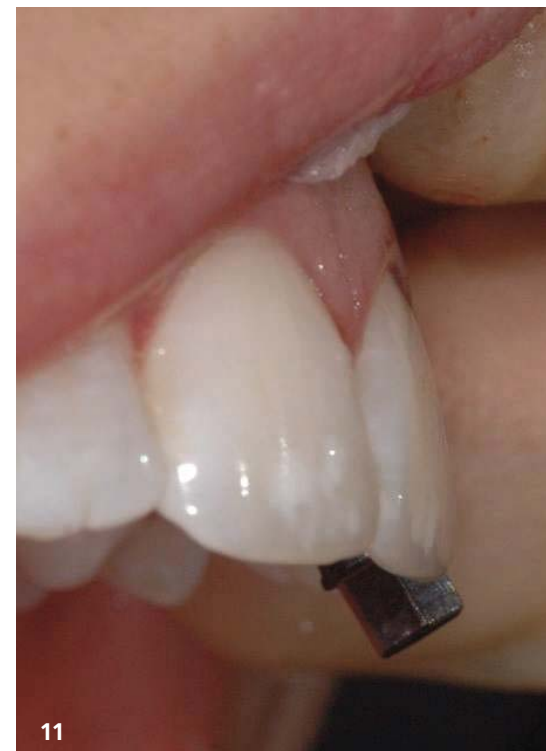An osteotomy was created using a sharp lance drill followed by a 2 mm twist drill, and then tapered twist drills to 19 mm depth (Southern Implants; Fig. 9), leading to an undersized osteotomy within the

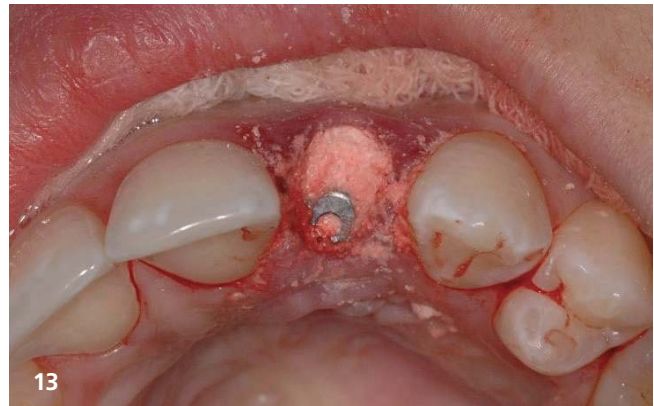
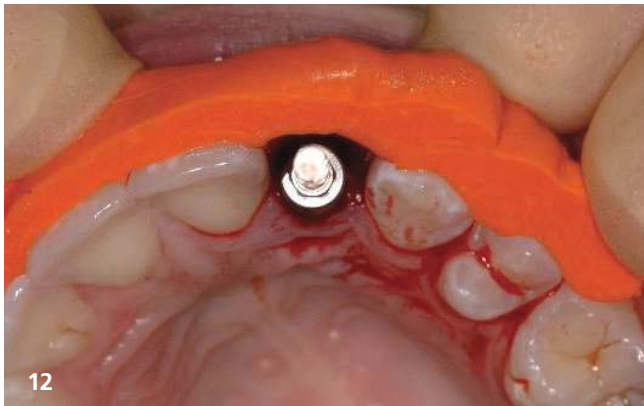original bony envelope for a Southern Tapered MSC External Hex 18mmx4mm implant (Southern Implants), a novel implant design with a machined coronal portion and an internal angle correction (Figs. 10 & 11). This implant combines a relatively narrow profile with length suitable to help achieve high primary stability for immediate tooth replacement therapy in the maxilla and was chosen due to the tall, narrow ridge form.

The implant was placed into the ideal position at 60Ncm, with the aid of a sur-



**Fig. 8:** Extracted UL2. The socket was then thoroughly degranulated and cleansed of all soft tissue remains using EthOss degranulation burs (Swallow Dental), curettes and copious irrigation with saline. **Fig. 9:** Osteotomy created using a sharp drill followed by a 2mm twist drill. **Fig. 10:** The MSC portion of the implant and the correct rotational axis after placement. **Fig. 11:** Southern Tapered MSC External Hex 18 mm x 4 mm implant placed to correct 3D position.





**Fig. 12:** Implant placed at 60Ncm, with the aid of a surgical guide. **Fig. 13:** EthOss Bone Grafting material placed into the site around a 4 mm healing abutment.

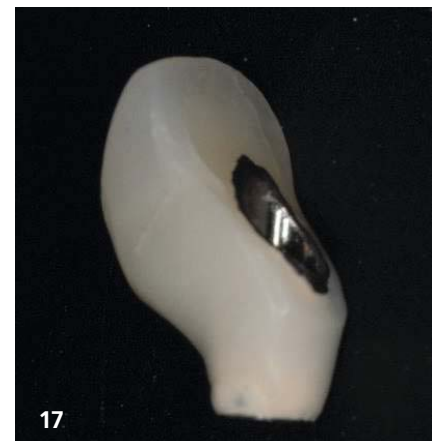
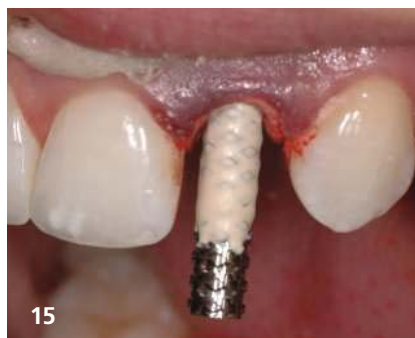gical guide manufactured from O-Bite silicone bite registration material, (AHP Medicals; Fig. 12). A healing abutment was placed prior to site augmentation with a resorbable synthetic bone grafting material (EthOss; EthOss), a novel biphasic bone substitute consisting of  $\beta$ -TCP (65 %) and calcium sulphate (CS, 35 %). 0.5 cc of the material was hydrated with 0.9 % sterile saline, mixed and partially dried, according to manufacturer's instructions and placed directly over the exposed implant threads within the circumferential jumping gap (Fig. 13). Gentle pressure for 3–5 minutes with a piece of sterile low-lint gauze al-

lowed time for the material to 'set'. The healing abutment was then removed and replaced with a titanium temporary engaging cylinder to 20Ncm (Southern Implants; Fig. 14), cosmetically masked with composite opaquer (BISCO; Fig. 15). The composite shell provisional crown (Fig. 16) was positioned and attached to the titanium cylinder using flowable, light curing composite resin (G-aenial Anterior, GC Europe), followed by its removal (Fig. 17), modification and finishing at chairside using polishing burs (Kenda C.G.I. One, Coltène/Whaledent) and disks (Super Snap, SHOFU Dental). Meticulous occlusal anal-

ysis ensured the crown was not in occlusion in either centric or excursive occlusal positions (Figs. 18–20).

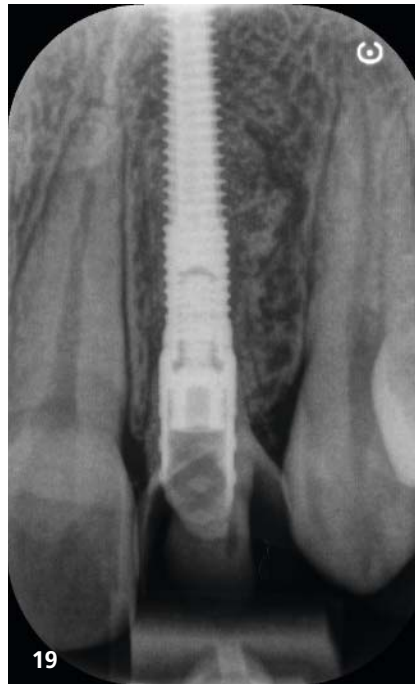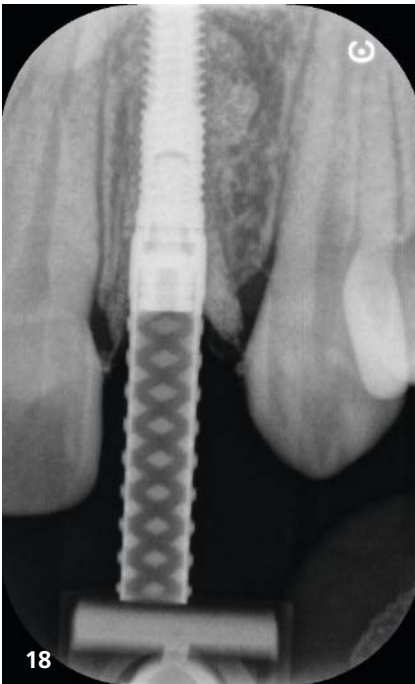
At review 14 days postsurgery, the restoration was assessed for mobility, the occlusion reassessed, and the oral hygiene status assessed and modified. Excellent initial healing was observed (Figs. 21 & 22).

At three-month review, the provisional crown had assimilated well into the oral scheme and the patient was masticating her normal diet with normal function. The patient was thus scheduled for the impression stage.



**Fig. 14:** Healing abutment removed and replaced with a titanium temporary engaging cylinder to 20Ncm. **Fig. 15:** Titanium temporary engaging cylinder to 20Ncm cosmetically masked with composite opaquer. **Fig. 16:** The composite shell provisional crown. **Fig. 17:** Composite shell provisional crown positioned and attached to the titanium cylinder using flowable, light cured composite resin.





**Fig. 18:** Immediate post-placement radiograph showing EthOss in both apical defect and jump gap.

**Fig. 19:** Radiograph after provisional crown fitting showing accurate fit.

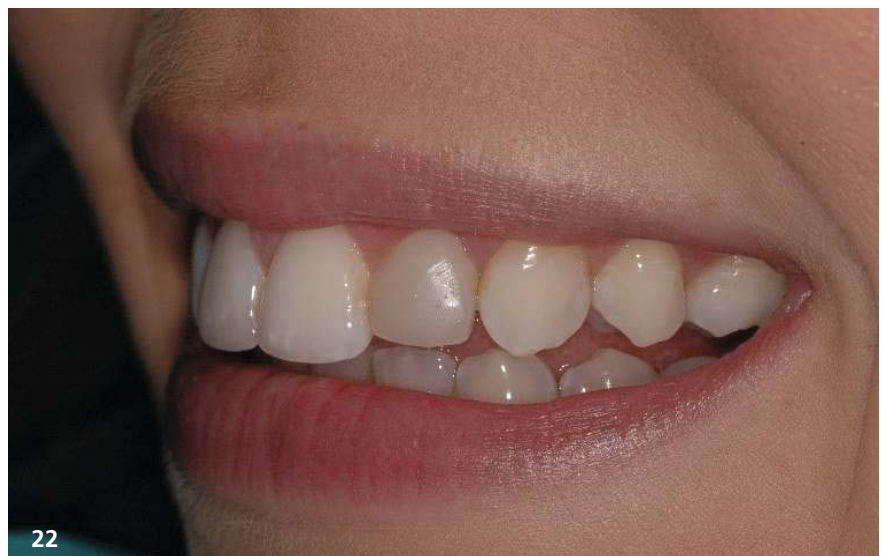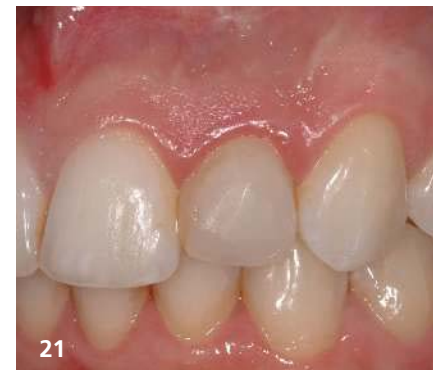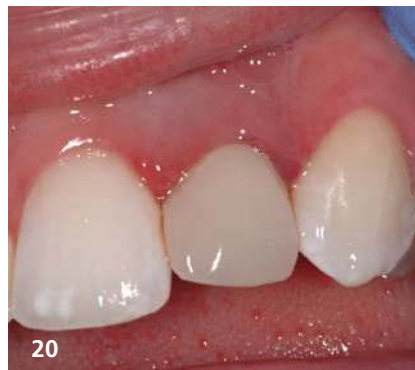ination compared to a moderately rough implant surface.

The bioactive  $\beta$ -TCP and CS combination produces a grafting substrate that self-hardens, with the CS having a barrier function, preventing soft-tissue ingress during the early phases of bone-regeneration. The CS resorbs in a three-to-six-week window dependent of individual patient physiology, and as it resorbs, it creates interlinked porosities within the  $\beta$ -TCP scaffold for angiogenesis.

The  $\beta$ -TCP scaffold resorbs over a 6–12-month period due to a combination of phagocytosis, hydrolysis and bony enzymic action. As both the CS and  $\beta$ -TCP are fully resorbable bone augmentation materials, host bone is regenerated without the continued presence of residual graft particles.

This case study shows amendments from the original published protocol<sup>2</sup>

A digital impression was taken using a Medentika scan body (Medentika) and a Trios intra-oral scanner (3shape). A custom screw-retained zirconia crown, with titanium lab-bonded abutment was delivered to the mouth and fitted to 35 Ncm. Silver plug (Silveraid), and G-aenial composite (GC Europe), were used to occlude the palatal screw channel. A post fit radiograph showed a well fitting restoration and complete socket healing with host bone (Figs. 23–27).

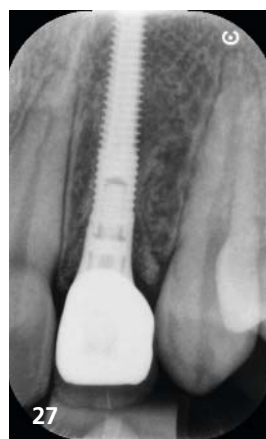
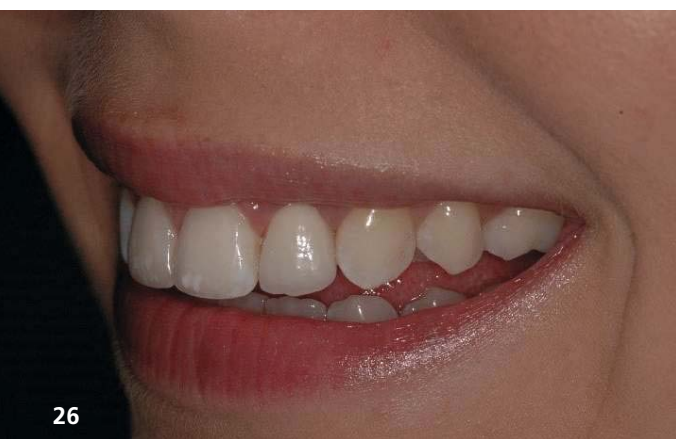
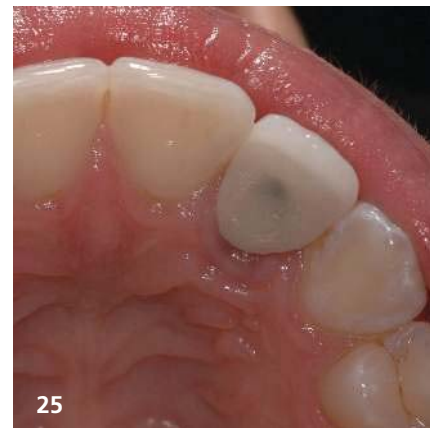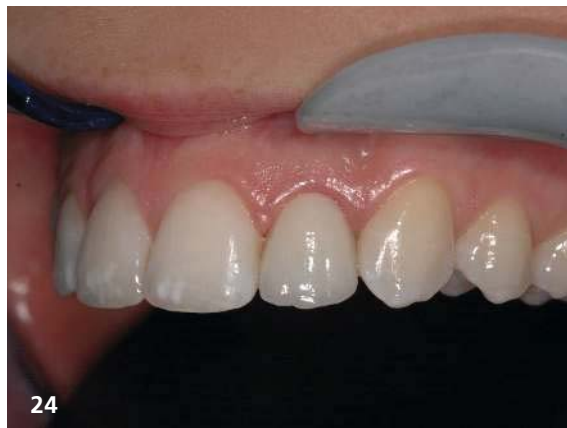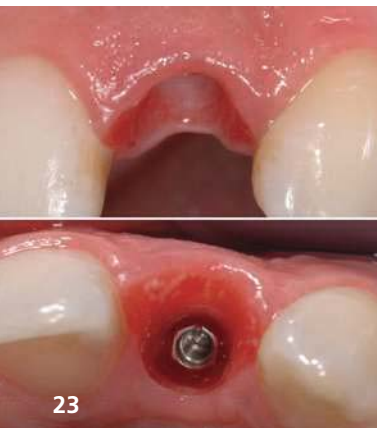## Discussion

This case provides an example of the use of a novel site-specific implant with a bioactive alloplastic  $\beta$ -TCP and CS material, in an immediate tooth replacement protocol.

The premise of the novel implant design features an internal angle correction of 12 degrees, allowing optimised screw channel position palatally, whilst engaging favourable mid-ridge bone. In addition, the machined coronal surface is purported to be more resistant to peri-implant disease, due to a reduced propensity to microbial and microbial product contam-

**Fig. 20:** Immediate postoperative image. **Figs. 21 & 22:** One-week postoperative situation.



**Fig. 23:** Three months postoperative image showing preservation of anatomical features (bleeding due to hemidesmosomal attachment).

**Fig. 24:** Final restoration—buccal view. **Fig. 25:** Final restoration—palatal view showing screw access channel. **Fig. 26:** Final restoration. **Fig. 27:** Final radiograph showing full bony healing and crown emergence.

where these materials are used in delayed immediate procedures. Here an immediate tooth replacement protocol is used with simultaneous grafting for enhanced preservation of host hard tissues, along with up-regulated host-regeneration.<sup>1</sup>

The  $\beta$ -TCP graft constituent shows both osteoconductive, but also, osteo-inductive potential, which enhances host bone regeneration during the postsurgical healing period. The self-hardening nature of the CS means graft stability during the crucial early contact with the host periosteum. The internal angle correction of the implant allowed mid-ridge positioning and thus, a circumferential jumping gap for increased graft volume within the original bony envelope, facilitating ideal palatal screw channel emergence, without the use of ASCs, with their potential pitfalls, or the use of a cement-retained solution with its well-documented issues.

For further reading regarding the science specific to bioactive calcium phosphates and their clinical applications, the

readers may refer to papers published in previous issues of the *EDI Journal* and other international journals.<sup>1–4, 12–16</sup>

### Conclusion

To conclude, the use of this novel site-specific implant design in conjunction with immediate tooth replacement therapy and the use of a fully resorbable bioactive alloplastic graft material may have resulted in a synergistic result for this case, with a very pleasing outcome for this patient. It is vitally important that clinicians are well versed in the surgical procedures they utilise, and fully understand the handling characteristics and other specific properties of the grafting protocols they elect to use, so that they can optimise the complex biological and osteo-immune mechanisms of host bone regeneration for each individual implant-based surgical procedure, and improve both predictability and long-term success of their implant dentistry practice.

Author details



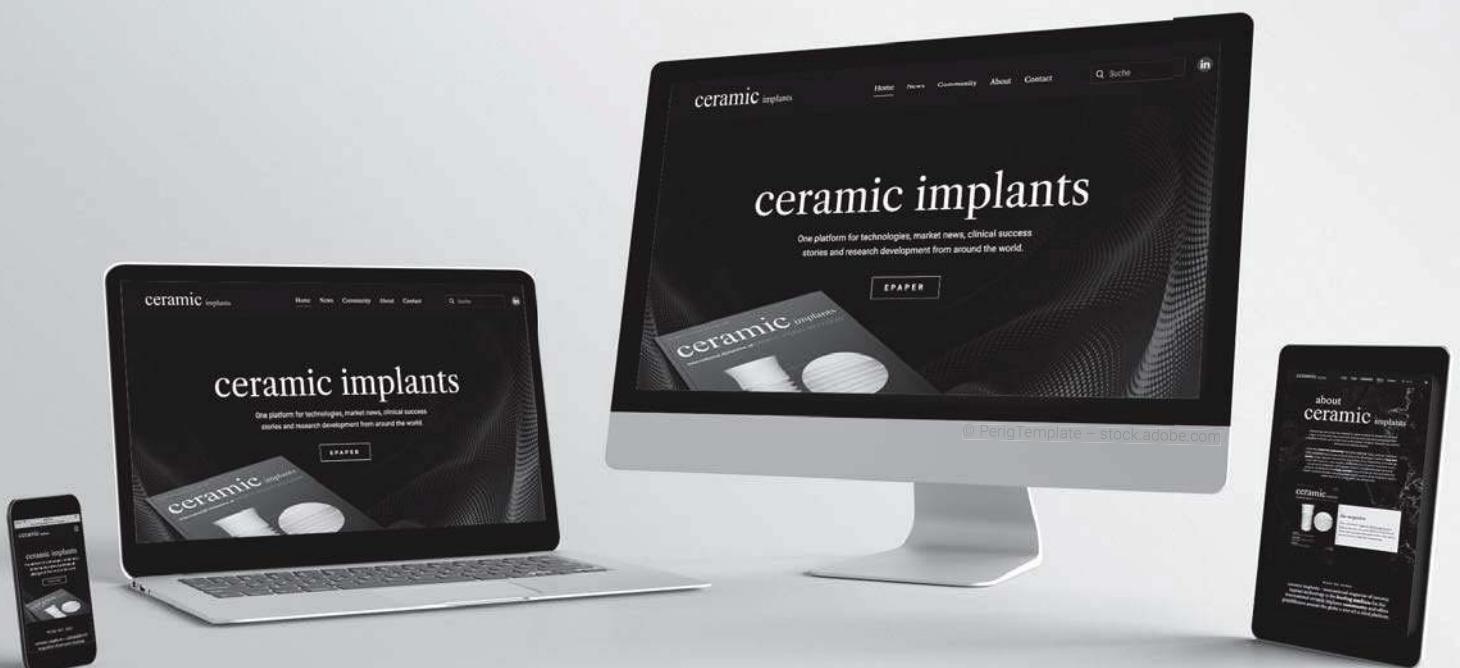### Contact address

**Dr Mark Worthing**  
Tupsley Dental Practice  
60 Aylestone Hill  
Hereford, HR1 1HX, UK  
[www.tupsleydentalpractice.co.uk](http://www.tupsleydentalpractice.co.uk)

# ceramic implants

is **ONLINE!**

e-paper · news · articles · community · newsletter



Check out the  
new website!

[ceramic-implants.info](http://ceramic-implants.info)



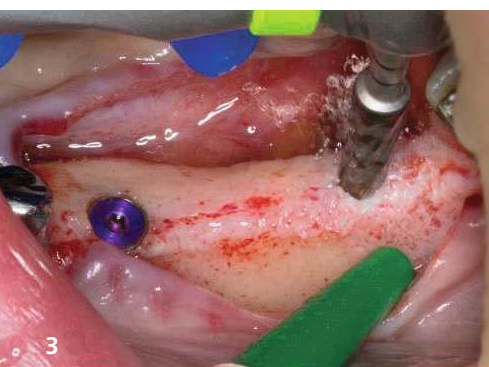
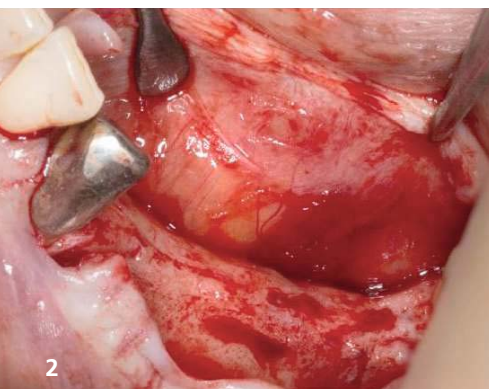
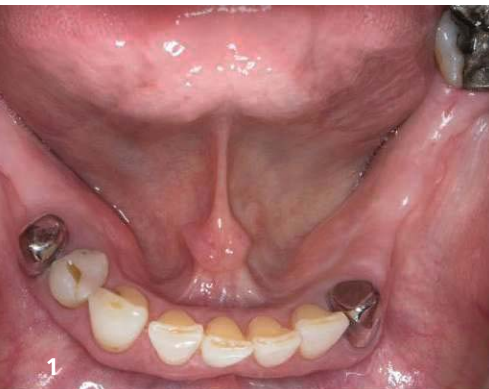Subscribe to  
the newsletter!

[ceramic-implants.info/subscribe](http://ceramic-implants.info/subscribe)

# Soft-tissue thickening—natural revascularisation with NovoMatrix<sup>®</sup>

Andreas van Orten, M.Sc., M.Sc., Germany

The presence or creation of an adequate peri-implant soft-tissue cuff appears to have a decisive influence on both the osseous and soft-tissue volume dimensions, as well as on the superstructure's ability to integrate inconspicuously into the peri-implant environment and establish inflammation-free conditions in the long term.<sup>67</sup> At the present time, there is no universal consensus regarding the need for the presence of keratinised mucosa around implants or the exact volume of soft tissue to prevent peri-implant diseases as effectively as possible. However, there is circumstantial evidence that soft-tissue augmentation has a long-term positive impact on peri-implant health.<sup>29</sup>



From a threshold value of just over 3 mm tissue thickness, it no longer seems possible for the human eye to detect discolorations caused by implants together with prosthetic components—a tissue thickness of 2 mm already appears to be sufficient for implants.<sup>68</sup>

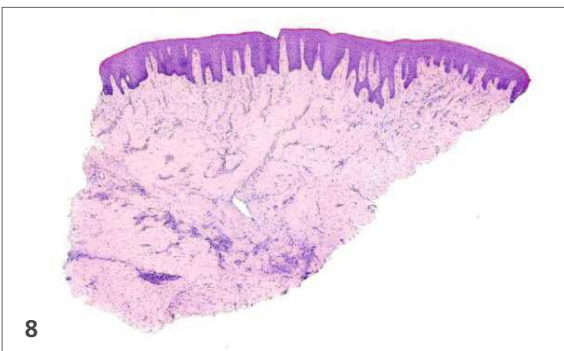
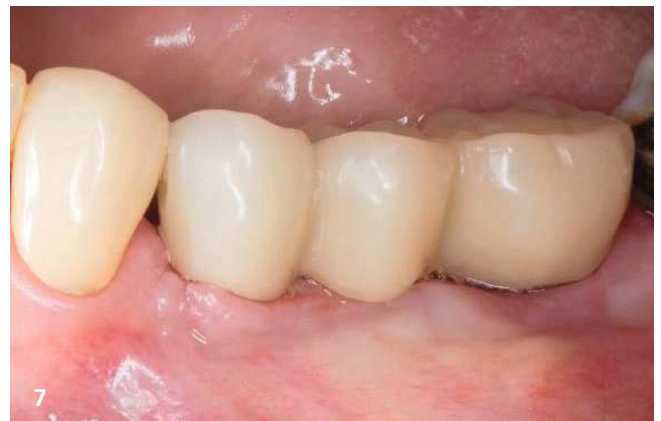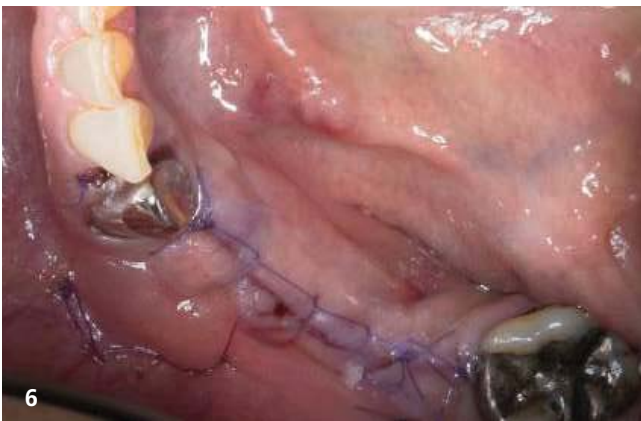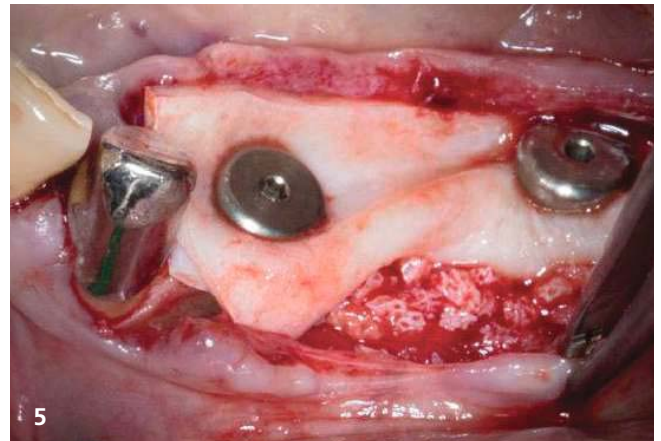
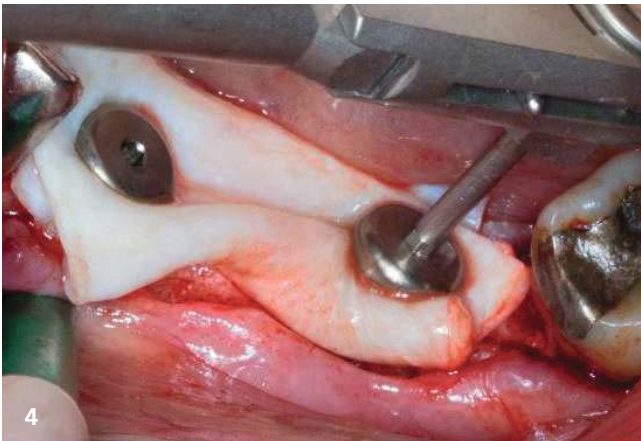
The threshold value above which the extent of postoperative remodelling around implants appears to decrease is >3 mm. This value appears to be the lower limit to ensure adequate biological width. However, there are also studies that favour a value that could be close to 4 mm.

Not every implant morphology is suitable for achieving an increase in biological width through subcrestal placement. If the problem of a thin mucosa at the insertion site is to be solved by subcrestal implant placement, other problems such as an unfavourable crown/implant length ratio or a limited safety distance to relevant structures, such as nerve canals, may result as a conse-

quence. If the option of subcrestal insertion is preferred, preference should be given to an implant with the option of so-called "Platform Switching", even though the absence of adequate soft-tissue thickness may possibly not be fully compensated.

At the present time, the consensus is that—if modification of soft-tissue volume and widening of the zone of keratinised mucosa around implants is the objective—autologous connective tissue grafting should be considered as the "gold standard".<sup>69</sup> The disadvantages of intra-oral harvesting of the grafts are not difficult to name: they are mainly postoperative pain, possible wound healing disturbances at the harvest site, the limited harvest volume, the prolonged surgery time and, in the case of retained epithelium, the highly probable colour deviation from the "donor" to the "recipient site" in both combined connective tissue and free mucosa grafts.<sup>70</sup>

**Fig. 1:** After completion of carcinoma therapy, the image showed a severely atrophied jawbone in regions 34 to 36, and 46 and 47, due to unphysiological loading, caused by a poorly fitting telescopic prosthesis. The patient wished for a fixed restoration in the lower jaw, which was to be realised on two implants in each quadrant. The treatment steps are described based on a quadrant. **Fig. 2:** After digital implant planning, the incision was made midcrestally to compromise subsequent blood supply as little as possible. To enable tension-free wound closure even without periosteal slitting, the superficial fibres of the mylohyoid muscle were detached. The concept was chosen to spare the patient multiple surgical interventions in view of her prior medical history. **Fig. 3:** With the aid of prosthetic orientation templates and the Cervico system, the exact implant position was determined, and the implant beds were prepared according to the surgical protocol using the PROGRESSIVE-LINE surgical instruments. Implantation was performed in regions 34 and 36. In the further procedure, the components for the Platform Switching (PS) option were used.



**Fig. 4:** To achieve a significant increase in soft tissue, the NovoMatrix was applied doubly. The matrix was perforated in the area of the implants and fixated with 6 mm high gingiva formers in each case. The gingiva formers acted in the context of the tentpole technique to reduce stress on the surgical site.

**Fig. 5:** The coarse MinerOss® XP

and autologous bone chips obtained from the drill tunnels were mixed with autologous blood to reconstruct the hard-tissue deficit. The augmentation was pushed from vestibular and lingual under the matrix. By keeping the gingiva away like a tent roof, the matrix is intended to initiate soft-tissue formation during the integration phase and regenerate the graft in a stable and calm manner. The bone substitute material was covered with additional PRF membranes. **Fig. 6:** Tension-free wound closure—in this case using a combination of deep horizontal mattress sutures and situation sutures in a second plane to close the alveolar ridge incision—allows undisturbed wound healing. The vertical increase in volume could already be observed at this time. The sutures were removed after twenty days, and regeneration was successful. **Fig. 7:** The soft tissue presented itself as adequate and stable. The aesthetic analysis showed no dyschromia when compared with the surrounding tissue. A firm soft-tissue cuff will establish itself peri-implant in the long term. The attached soft-tissue growth around the implants is clearly visible on the natural teeth—when compared with the keratinised gingiva. **Fig. 8:** An image of the biopsy of a section of tissue transplanted with the NovoMatrix from a female patient not presented in this case report. Here, too, a regular para-keratinised epithelium with moderate retention formation is impressive. Histology was performed in an independent institute by Prof. Dr Werner Götz, Bonn, Germany.

Author details



#### Contact address

**Andreas van Orten**  
Gemeinschaftspraxis für Zahn-  
heilkunde Andreas van Orten  
und Dr Dirk Krischik  
Dortmunder Straße 24–28  
45731 Waltrup, Germany

+49 2309 786161  
mail@zahnaerzte-do24.de  
www.zahnaerzte-do24.de

## Report on the 18<sup>th</sup> Expert Symposium of BDIZ EDI

# Compact know-how

Short, angulated and reduced-diameter implants. The 18<sup>th</sup> Expert Symposium in Cologne offered an exciting and high-quality one-day congress programme.



The symposium was chaired by Prof. Nickenig (left) and Christian Berger (3<sup>rd</sup> from left). Participant and guest Prof. Christoph Benz (3<sup>rd</sup> from right), President of the German Dental Association, next to speakers Dr Markus Tröltzsch, Dr Alexandros Manolakis and Prof. Friedhelm Heinemann.

Dr Markus Tröltzsch (Ansbach, Germany), member of the BDIZ EDI board, began by asking whether there are alternatives to those implants that were the focus of the symposium. Tröltzsch is the author of the DGI and AWMF guideline on bone augmentation. "One thing we always have to point out is that stand-alone augmentation procedures are associated with their very own set of complications and possibilities for failure." In the first part of his presentation, Tröltzsch asked why we place which implant. Avoiding augmentation altogether—even if the patient in particular would like to avoid it—is not

always the most effective way. It was important that patients are fully informed about the treatment options and risks.

Using a diagram from the aforementioned guideline, Tröltzsch emphasized the importance of the soft tissue surrounding the defect ("skeletal envelope"). Recognising and defining this was one of the key factors in the success of augmentation. Clinical practise had shown that any displacement of the soft tissue beyond its original position (before the defect occurred) constituted a different type of augmentation than augmentation within the skeletal envelope. Tröltzsch said that

it was important how far the soft tissue had to be displaced beyond its original position, as this was "high-risk territory".

Tröltzsch referred to the minimum distance between implants according to Tarnow et al., which also applied to short, angulated or reduced-diameter implants. Not only the lateral dimension but also the width of the bone is important, he said: "If we don't leave two millimetres of space around the implant, failure is inevitable." When it comes to planning, implant dentistry is currently in the post-backward planning phase, said Tröltzsch. Planning is based on the likelihood of complications after prosthetic planning. Implant dimensions could be a factor in why implants around 6 mm in length are harder to salvage if complications arise "because we simply do not have any reserves to fall back on. Of course, if we go wide, vertical loss is much more likely than if we just have a funnel around the implant."



Dr Markus Tröltzsch

Implant dimensions could indeed play a role in a potential rescue mission. At the end of his presentation, Tröltzsch pointed out that the choice is not between augmentation and alternative techniques. “We have to ask ourselves: How can we achieve the best possible outcome for the patient with the least amount of risk? How do our techniques complement each other to achieve this goal for the patient?”

### The “short ones” in focus

The dean of short implants, Dr Eduardo Anitua (Vitoria, Spain), examined the extent to which short implants can be a reliable alternative to conventional implants. In his opinion, extra-short implants—now available in lengths of less than 5 mm—offer added value by reducing the bone volume required. However, they require the use of the right instruments and a high level of surgical skill, as it is not uncommon for the surgeon to work very close to critical anatomical structures.

Anitua recalled the early days 35 years ago, when implants were 13 or 15 mm long, whereas today his implants have an average length of only 6.5 mm. He said that he had carried out various biomechanical analyses to test the load-bearing capacity of the implants and the bone and had written books on the subject. His conclusion was that the larger the diameter of the implant, the less stress on the bone. Anitua then looked at studies



Eduardo Anitua, MD, DDS, PhD

of implant lengths in the maxilla, concluding that short (6.5 or 5.5 mm) implants gave the same results as “long” ones. He said that one day he had asked himself why he, like so many others, had performed so many lateral sinus lifts in his career just to place 13 mm implants when he could have achieved the same results with 5.5 or 6.5 mm implants with less pain and better predictability. Other studies had shown him that even 4.5 and 5.0 mm implants had the same results in terms of force exerted on the area of maximum total load compared with 10, 11 or 13 mm implants. His conclusion: “When inserting implants vertically, length does not matter.” His view on angulated implants was a much less favourable one. Angulated implants, he said, increased stress levels “exponentially”. Biomechanical issues and serious complications during explantation were further arguments against angulated implants. Anitua called them “one of the biggest mistakes of the last 20 years in implant dentistry” from a scientific point of view. For All-on-4 and All-on-6 restorations, he advocated avoiding cantilever situations to prevent stress to the bone and increase treatment predictability.

### The case for angulated implants

Contradicting Dr Eduardo Anitua, Dr Alexandros Manolakis (Thessaloniki, Greece) argued for the use of angulated implants and demonstrated how they allowed faster rehabilitation of patients with atrophic jaws—often with immediate restoration. The exact positioning of the implants, the amount of bone around the implants and, above all, the design of the restoration are important, he said. Why (and when) should angulated implants be used? Because there is often too little bone available, especially in the posterior region of the jaw, even for short implants. In addition, the aim is to provide the patient with a fixed restoration, preferably without bone augmentation, while achieving high primary stability. “Moreover, these implants allow us to provide an immediate restoration.” For

Manolakis, the concept makes good biomechanical sense because the distal extensions of fixed bridges should be as short as possible. With the All-on-4 or Fast & Fixed concepts, the distal implant or the head of the distal implant can be placed in the region of the second premolar, so that the cantilever is only one tooth—one molar—wide.

“Clinically, the angulated implants do not differ in survival rates from straight implants.” Maxillary loss rate: 0–3.3%. Mandibular loss rate: up to 7.2% (De Bruyn et al.).

Opinions differed on marginal bone and bone loss over time, Manolakis said. Some meta-analyses had found identical bone behaviour, while others had found significantly more bone loss with angulated implants. Manolakis did not consider the difference (between 0.2 and 0.3 mm, respectively) to be clinically significant.

So what would happen in the worst-case scenario of peri-implantitis? Manolakis considered the longer (angulated) implants to offer a clear advantage in these cases. The short 5 mm implants would probably have to be removed, he said, while 10 or 12 mm implants would still offer room for retreatment.

### Lack of studies on reduced-diameter implants

Reduced-size implants were the subject of Dr Keyvan Sagheb (Mainz, Germany),



Alexandros Manolakis, DDS

who discussed important criteria for success based on clinical cases and current literature. From the practitioner's point of view, he said, the question is whether costly treatment concepts are necessary or whether other, less surgically demanding treatment alternatives are available. One question was paramount: "Should I do socket management or immediate implant placement?" He considered reduced-diameter implants and short implants (defined at the University Hospital in Mainz as shorter than 8 mm) an interesting option. Of course, the question of angulated implants with All-on-4 or All-on-6 also played a role.

In the case of reduced-diameter implants, he was interested in whether they were as good as, better than or worse than an implant in the atrophied jaw that required augmentation. According to the literature, reduced-diameter implants (intraosseous diameter less than 3.5 mm) had about the same survival rate as standard implants (98%). Unfortunately, the findings by Nicola Alberto Valente et al. had not been challenged until now. According to Sagheb, there are no relevant prospective randomised trials because such a study is difficult to design and implement.

For the three groups of reduced-diameter implants, Sagheb found that mini-implants ( $\varnothing \leq 2.5$  mm) worked to support definitive maxillary and mandibular complete dentures. For temporary dentures,

the Mainz team placed six implants in the maxilla and at least four implants in the mandible, preferring delayed placement in the maxilla and also preferring to wait four to six weeks in the mandible, which works well with the new hydrophilic surfaces. In the category of narrow implants ( $\varnothing 2.5$  to  $< 3.3$  mm), Sagheb cited advantages in the anterior region where interdental width is reduced (lateral maxillary incisors and mandibular anteriors). The most exciting group for him were implants with diameters between 3.3 and 3.5 mm supporting definitive maxillary and mandibular complete dentures. This seemed to be an alternative in the posterior region, but also for single-tooth restorations. In summary, Sagheb considered "the narrow ones" as an alternative in situations with reduced mesiodistal width to avoid augmentation and especially the complexity of lateral augmentation, thus reducing morbidity, and to be able to perform one-stage instead of two-stage procedures.

### **"Minis" as an additional option, not a replacement**

Prof Friedhelm Heinemann (Greifswald, Germany) spoke about the practical aspects of prosthetic fixation with mini-implants. He highlighted serious alternatives for patients for whom extensive and time-consuming augmentation procedures were not an option because of their medical history or their preference. Shorter or narrower implants could help avoid augmentation in certain indications. However, the use of implants with reduced length and/or diameter would need to be based on scientific principles.

There was a consensus definition of mini-implants at the 18<sup>th</sup> European Consensus Conference, which Heinemann recapitulated: Implants with a diameter of less than 2.7 mm are called mini-implants (almost exclusively single-phase). They are always transgingival, which means that primary loading cannot be completely excluded. Heinemann presented 10- to 15-year-old cases with mini-implants as extra abutments for partial dentures, as

replacements for lost teeth or as additional support, including for an existing tooth (Greifswald concept).

He recalled a retrospective study by Prof Torsten Mundt (Greifswald, Germany), who had followed the clinical performance of 738 mini-implants placed about 15 years ago to stabilise complete dentures, looking at risk factors for failure, peri-implant health, marginal bone resorption, and the maintenance effort in terms of oral health-related quality of life.

Results: Over the five-year period, the success rates were 95.7% in the maxilla and 94.3% in the mandible—corresponding to 15 and 11 failures, respectively, but also 5 and 9 reimplantations. An important point, he said, was that the restoration could continue to be used. "This is basically a very simple and not very high-end restorative procedure." There was a lot to learn with this procedure, Heinemann warned, and it was different from the approach with standard implants. He therefore considered it an addition to his implant treatment armamentarium, but not a replacement for anything.

Overall, Heinemann concluded, reduced-diameter implants represent an expansion of the range of implant indications—especially in view of an increasingly ageing population and the associated multimorbidity. Reduced-diameter implants would become increasingly important for supporting partial and complete dentures. On the other hand, these



Priv.-Doz. Dr Dr Keyvan Sagheb



Prof. Dr Friedhelm Heinemann





Lively discussions with the audience after each presentation.

implants are not suitable for use by beginners. They should be reserved for experienced implantologists, particularly in transgingival placement and in cases of extremely reduced bone volume.

### Fixed teeth in one day— a clinical report

Dr Ingo Frank (Landsberg, Germany) spoke on “Fixed teeth in one day—a reliable treatment option?” He presented treatment approaches for patients with periodontally compromised dentition. For



Dr Ingo Frank

many patients, he said, immediate restoration of chewing function is often the key to starting treatment. His presentation used clinical cases to illustrate the decision-making process for or against immediate loading to provide optimal prosthetic anchorage for aesthetic, functional and economical restorations. Frank introduced the system used at his practice in Landsberg. Most patients were interested in getting fixed teeth in one day, he said. At the Landsberg clinic, he reported, patients were treated under general anaesthesia three to four times a week.

Typical patients were over 50 years old, had worked a lot in their lives and now realized they needed to do something—often with a lot of anxiety as they had often not taken very good care of their teeth. The clinic used digital impressions. A total of 16 implant systems are available, four of which have immediate-restoration concepts. Frank showed a case that had worked completely on his own, fully guided, without an in-office lab, although he admitted that this was not at all his preferred setting because of the potential of problems.

The Landsberg clinic usually works with templates. Frank showed curious clinical cases to illustrate his clinic’s method:

careful patient selection, a prosthetically driven approach especially for the “fixed teeth in one day” treatment, never without a 3D scan, always with a digital workflow, and with frequent recalls.

### Conclusion

At the end of the Expert Symposium, Prof Jörg Neugebauer presented the 2023 Guideline on “Short, angulated and reduced-diameter implants”, updated for the second time since the beginning of the European Consensus Conferences. We had already presented this Guideline in detail in the 1/2023 issue of the *EDI Journal*. This is the consensus recommendation: “The use of short, angulated or reduced-diameter implants in sites with reduced bone volume can be a reliable, faster and less risky therapeutic option in terms of specific treatment parameters, compared with the risks associated with the use of standard-dimension implants in combination with augmentation procedures. The implant surgeon and the restorative dentist must have appropriate training to select the best possible therapy choice for each patient.”

AWU



The Inspiration Hub exhibition area spread across two floors.

## Dentsply Sirona Implant Solutions World Summit 2023

# Cutting edge science and innovation

From 8 to 10 June, the Dentsply Sirona Implant Solutions World Summit 2023 took place in Athens, Greece where science has its origins. Inspired by connection and future innovation, the event delivered immersive experiences to inspire and feed attendees' passion for implant solutions. Implant professionals from around the world who are passionate about elevating the dental industry and improving the quality of implant treatments and care for patients convened for three days of knowledge exchange, inspiration, and networking. They have been able to discover the latest innovations in implant solutions, including the EV Im-

plant Family, digital dentistry, and bone regeneration. The summit's state-of-the-art educational programme was developed together with the Scientific Chairs—Dr Tara Aghaloo (USA), and Dr Michael Norton (UK)—and the Programme Chairs—Steve Campbell (UK), Dr Malene Hallund (Denmark), Dr Mark Ludlow (USA), Dr Stijn Vervaeke (Belgium), and Dr Martin Wanendeya (UK) and featured 50 world-renowned speakers from 12 countries with inspiring main stage presentations, hands-on workshops, and break-out tracks on topics such as aesthetics and the digital dentistry ecosystem, half of them being new presenters at a Dentsply Sirona event.

The CLOUD session explored the new digital universe and its power to transform patient journeys from diagnosis to final treatment, with perspectives from two clinicians—Dr Martin Wanendeya (UK), and Dr Stefan Vandeweghe (Belgium)—and one lab technician Steve Campbell (UK)—a live demo, and a look at the advantages for clinicians and labs.

Meanwhile, the BATTLE session featured debates from two clinicians on a hot clinical topic, moderated by Dr Mark Ludlow (USA) with the winner decided by the audience. In the first battle, Dr David Barack (USA) and Dr Rodrigo Neiva (USA) debated about biomaterials vs implant



Inspiration TALKS.



Tony Susino, Group Vice President, Global Implant Solutions at Dentsply Sirona.

selection. Battle two considered full arch digital vs full arch analog, with Dr Mischa Krebs (Germany) going head-to-head with Dr Gary Jones (USA).

“The Implant Solutions World Summit attracts some of the brightest and most passionate minds in implant dentistry,” said Dr Malene Hallund, oral and maxillofacial surgeon and Dentsply Sirona Key Opinion Leader. “The programme dives deep into all the latest developments in our field while challenging pre-existing ideas and assumptions. I know that attendees will walk away feeling excited and inspired for what the future holds.”

Attendees could visit the Inspiration Hub exhibition area spread across two floors. Participants gain hands-on experience with Dentsply Sirona’s comprehensive implant portfolio and digital workflow. Dentsply Sirona’s premium EV Implant Family—DS PrimeTaper Implant System, DS OmniTaper Implant System, and Astra Tech Implant System—were on display, as well as OSSIX regenerative solutions, DS Signature Workflows, and the cloud-based DS Core platform.

Moreover, the Implant Solutions World Summit featured two social evenings for attendees to network with peers and enjoy the best Athens has to offer.

“Peer to peer education is vitally important for our Implant Solutions community and we are thrilled to bring implant professionals together from around the world to explore the latest innovations and science transforming implant dentistry,” said Tony Susino, Group Vice President, Global Implant Solutions at Dentsply Sirona.

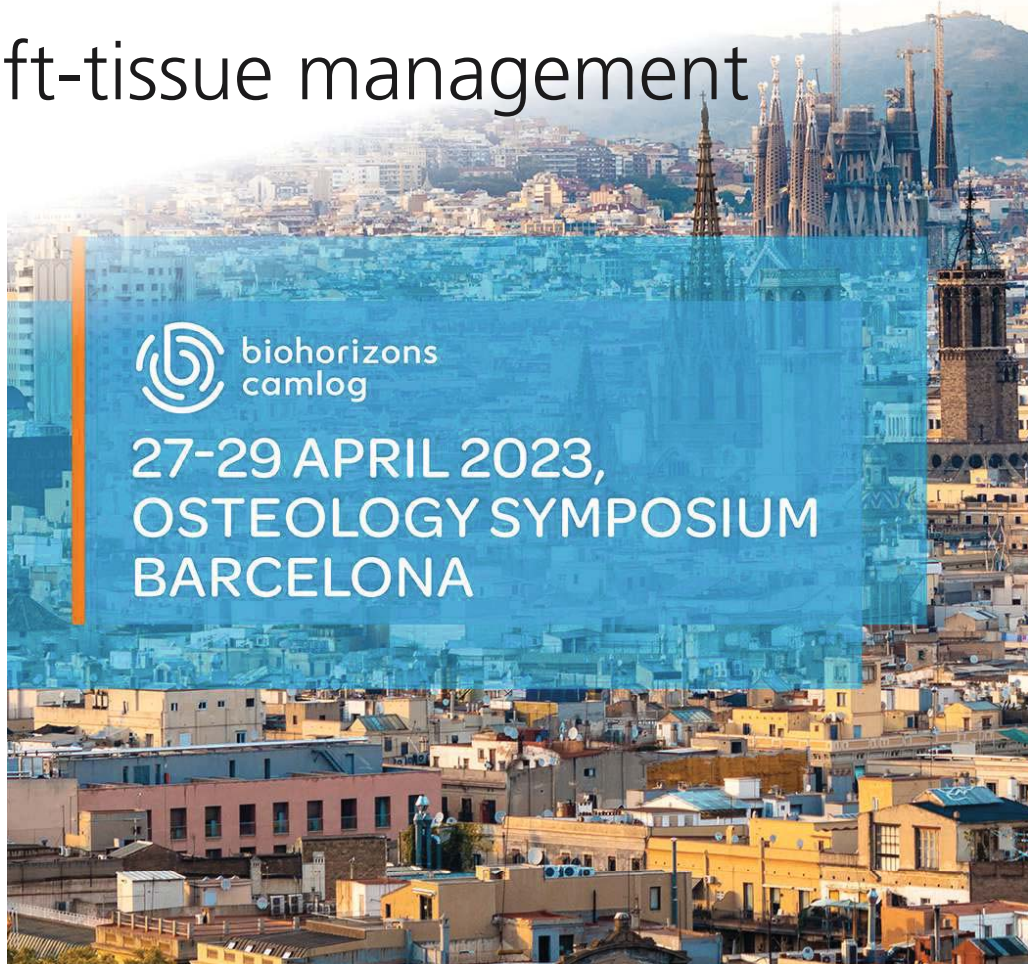

**Dentsply Sirona**  
www.dentsplysirona.com/worldsummit

## Osteology Symposium 2023

# New approaches to immediate restoration and soft-tissue management

The International Osteology Symposium (Barcelona, 27–29 April 2023) brought together leading experts from all areas of regeneration to offer an exciting programme of 80 lectures and 14 workshops under the scientific direction of Dr Pamela K. McClain and Dr Istvan Urban. As a Gold Partner, BioHorizons Camlog offered two educational sessions—an informative corporate forum on immediate restoration with CONELOG® Progressive-Line and a workshop on soft-tissue management with NovoMatrix™, the next-generation soft-tissue augmentation material.



On Thursday, 27 April 2023, Dr Ramón Gómez Meda (León, Spain) provided insights into a new approach to soft-tissue augmentation around implants using the NovoMatrix™ dermal matrix, providing in-depth coverage of indications, techniques and clinical cases in detail with a focus on soft-tissue augmentation. Participants benefited from hands-on training on porcine jaws to learn VISTA, tunnel, and crestal incision techniques for soft-tissue augmentation.

Later in the day, Dr Tomas Linkevičius (Vilnius, Lithuania) presented a nuanced approach to immediate implant concepts in a corporate forum entitled “Turning contraindication for immediacy into indication”. He asked why immediate implant treatment is often the best solution and discussed how the indications for immediate implants can be expanded.

At the BioHorizons Camlog booth, visitors were able to discover the company’s broad portfolio of innovative and holistic regenerative solutions through its comprehensive range of bio-

materials, including bone-graft substitutes (allogeneic, porcine, bovine and synthetic), membranes (porcine, bovine and synthetic), reconstructive tissue matrices (porcine) and wound dressings (bovine). BioHorizons Camlog has developed a comprehensive portfolio of biomaterials that enable dentists to provide the best possible care for their patients.

For more information, please visit [www.biohorizonscamlog.com](http://www.biohorizonscamlog.com).

### Contact address

**CAMLOG Biotechnologies GmbH**


Margarethenstrasse. 38

4053 Basel, Switzerland

+41 61 5654100

[contact@biohorizonscamlog.com](mailto:contact@biohorizonscamlog.com)





OSSTEM World Meeting 2023

# A global academic symposium uniting dental professionals

OSSTEM IMPLANT, a leading global dental implant manufacturer, recently concluded its highly anticipated OSSTEM World Meeting 2023. As a flagship global academic symposium, the event brought together renowned dental professionals from around the world for two days of knowledge exchange and hands-on learning. Held in Istanbul, Turkey after a three-year postponement due to the pandemic, the symposium proved to be a remarkable success. With a diverse range of sessions, expert speakers, and cutting-edge technologies, the OSSTEM World Meeting 2023 set new standards for dental education and collaboration.

The OSSTEM World Meeting, known for its global prominence, has been held annually since 2008, rotating between major cities worldwide. This year, the bustling city of Istanbul served as the vibrant host for the symposium on 12 and 13 May. The prestigious Hilton Istanbul Bomonti Hotel & Conference Center provided the perfect backdrop for this gathering of dental professionals.

Despite the unforeseen challenges brought about by the pandemic, the OSSTEM World Meeting 2023 saw an impressive turnout, with 1,200 dentists from 32 countries attending the event. The symposium aimed to foster knowledge sharing, hands-on experience, and networking opportunities among participants.

The first day of the event was dedicated to practical hands-on sessions, led by top-level course directors from Korea, the USA, and Turkey. These sessions covered various topics, including Guided Bone Regeneration (GBR), Sinus Surgery, and Digital Guided Surgery. The limited seats for each hands-on course were fully booked with pre-registered attendees, highlighting the eagerness for practical learning opportunities.

The second day, known as Symposium Day, featured five sessions, each with two distinguished speakers. Each session had its own moderator, resulting in a total of nine speakers and five moderators from countries such as the USA, Hungary, Croatia, Italy, Mexico, Turkey, and South Korea. The audiences benefited from an impressive 33-meter-wide screen, ensuring an immersive and engaging learning experience.

One of the highlights of the symposium was the live-surgery session during the third session, where Dr Yong-Jin Kim performed a surgery in Korea, which was live-streamed to the symposium hall in Istanbul. Utilising OSSTEM's innovative digital guided system, OneGuide, Dr Kim successfully placed six implants on the upper jaw within an astonishing 45 minutes. Professor Marco Tallarico from Italy, the moderator for the session onsite in Istanbul, provided valuable commentary to enhance the understanding of the process for the audiences.

To further extend the reach of the symposium, the entire event was globally live-streamed through OSSTEM's own broadcasting system, DenAll, with simultaneous

translation in several languages. This allowed dental professionals from around the world who were unable to attend physically to access the valuable content and insights shared by the speakers.

Complementing the intellectual endeavors, a memorable gala dinner was held on the eve of the symposium day, offering participants a chance to network and forge connections with fellow dentists from diverse backgrounds. The evening featured delightful four-course cuisine and captivating performances, creating an atmosphere of camaraderie and celebration.

Looking ahead, the OSSTEM World Meeting 2024 is already generating excitement as it prepares to take place in Seoul, South Korea, on 27 and 28 April. With its legacy of educational excellence and industry-leading advancements, the OSSTEM World Meeting continues to shape the future of dentistry by providing a platform for knowledge sharing, innovation, and global collaboration.

# Digital dentistry—the sky is the limit

Dr Shivi Gupta (Fig. 1) graduated in dentistry from the University of Manitoba, Canada in 2002. She completed a one-year advanced education in general dentistry residency at the University of Texas Health Science Center in San Antonio before moving to San Diego in 2004. After joining her current practice partner as an associate in 2010 in a newly founded practice, she became a partner in 2015. Dr Gupta conducted team trainings, attended continuing education courses and brought new services to the practice. She has always been interested in teaching others and sharing her knowledge on digital dentistry.

During the first DS World in Dubai from 5 to 6 February 2023 our editorial team had the chance to interview Dr Shivi Gupta on the topic of digital dentistry regarding her experiences in daily practice, patient reactions as well as its challenges and opportunities. As a mother of two, Dr Gupta also advocates for more females in dentistry and the beneficial balance between a professional career and family.



Fig. 1: San Diego dentist and digital dentistry specialist Dr Shivi Gupta.

***Dr Gupta, you are an expert in digital dentistry and CAD/CAM technology, what kind of difficulties did you encounter introducing digital dentistry in your practice?***

I decided to dive right in after adopting the technology. I was having good success but wanted to expand from doing single crowns into larger comprehensive cases with a digital workflow. I was able to make the leap by attending education courses as well as online learning. I found the more I immersed myself into learning about the technology, the more I could offer expanded treatment modalities.

***How do you see digital dentistry impacting the workflow between the dentist and the dental technician?***

The processes between practice and laboratory benefit extremely from digital technology. Just think of the intra-oral scan. There is no need for a cast model that has to be manually sent. By using DS Core the scans are automatically uploaded to the cloud and can be sent to any partner together with annotations. Everything is much more direct and faster. We can communicate better and quicker, allowing us to focus on what we do best. In addition, the same high-quality restorations can be repeated multiple times. This means that not only we in practices and labs benefit, but above all the patient.

***How do you convince your patients to accept for example an intra-oral scan instead of an analogue method? And how does, in your opinion, the use of digital technology in dentistry improve the patient experience?***

I honestly do not have to convince my patients because they come to me knowing exactly that they will be treated with state-of-the-art technology. Concerning the patient experience: You certainly do not go to the dentist to stay there for long. Everyone is happy when the needed things are done quickly and in a high quality. And I can achieve that with digital dentistry. My patients know and appreciate that. And just in case, I can show them the imagery easily on the digital cloud platform.

***How does computer-aided design and manufacturing technology play a role in guided dental implantology?***

CAD/CAM technology has played an important role in guided implant dentistry for a very long time, just think of CEREC Guide, which was introduced ten years ago. Let us not forget that with today's technology, one can also print surgical guides for a patient's implant placement.

***In your opinion, why are there still relatively few women in this field of dental surgery? Could it be that they are expected to balance family and work responsibilities?***

When we look at leadership positions and at training facilities, it is predominantly male leaders and mentors. But I believe a shift is coming. In the US, we have now more women graduating dental schools. I think it's the same in Europe, and perhaps in other parts of the world. Therefore, it's important to support this momentum and give female dentists a platform to show young dentists that living a balanced life is possible. When young women see that there are female dentists who are passionate about their profession and their families, and are successful in their dental careers, it does something to them. They should all have ambitious goals and be able to achieve them, but having

reliable role models is also equally important. The sky is the limit—that is what I believe and tell young professionals.

***How can mentorship and networking opportunities be made more accessible to women in surgical dentistry or can you discuss any current initiatives or programmes that promote gender diversity and inclusion within surgical dentistry?***

In my opinion, we women in dentistry can do a lot for each other. As mentors, as role models, as friends. I encourage my peers to proactively join local organisations or associations, and fiercely advocate for programmes and opportunities that inspire, uplift, and support young female dentists and students within their community. If you find yourself thinking sometimes, "Oh, it would be great if we have something like this or that"—then turn that thought into action.

On a similar note, I am a proud partner of Dentsply Sirona and have been working with the company for many years. One of the main advantages is I am able to collaborate with the company on certain programmes specifically for women. An example is "FirstTo50", Dentsply Sirona's Global Women Speaker Development Program. It was launched in 2022 with the aim to help develop female dentists' public speaking and presentation skills. The programme includes online sessions with a professional coach, and I believe it was truly valuable when I prepared for my mainstage presentation in the previous DS World in Las Vegas. We need more women on the podium and FirstTo50 is a fantastic boost to make that happen (Fig. 2).

***What development potential do you see in digitised dentistry, especially regarding CAD/CAM technology? What could become even better, simpler and more intelligent in the next years?***

I think we are kind of moving towards more printing—and that can open a lot of possibilities! It is not about making the lab redundant; it is about having a quicker turnaround for our patients. I am a big SureSmile provider, and while having a digital lab already enables me to have an efficient turnaround, perhaps in the future by being able to print the first two aligners, then I could imagine a patient could start immediately! Moreover, it would be really nice if all of the different platforms could work on a universal platform. I think we are already on the path to make that happen and that makes dentistry such an exciting passion!

***Thank you for the interview, Dr Gupta.***



**Fig. 2:** Dr Shivi Gupta at the Dentsply Sirona World in Dubai.



**Contact address**

**Dr Shivi Gupta**

Scripps & Rock Dental  
12112 Scripps Summit Dr, Suite C  
San Diego, CA 92131, USA



© Cleanimplant Foundation

SEM image INVERTA implant—Southern Implants.

### CleanImplant “Trusted Quality” seal

# More manufacturers prove the production quality of their implant systems

CleanImplant Foundation gives orientation for dentists and patients toward a “clean” medical product.

After the “Astra Tech EV” by Dentsply Sirona was awarded this March, the coveted seal for Trusted Quality has now been given to two other implant systems: The renowned implants, “SuperLine” by Dentium and “INVERTA” by Southern Implants are now welcomed into the family of certified clean implants. The scientifically based seal of quality, which underlines the first-class surface purity of dental implants, is only awarded by

the CleanImplant Foundation’s Scientific Advisory Board after a rigorous peer reviewed analysis and testing process.

“This award is an objectively transparent proof that colleagues are using a residuefree medical device for their patients by manufacturers who implemented the highest quality standards,” explains Dr Dirk U. Duddeck, Founder and Head of Research at CleanImplant. To obtain this valid, objective proof, a so-called “five step approach” was established in cooperation with the eight-member Scientific Advisory Board:

#### CleanImplant Trusted Quality seal—Five step approach

Step 1	<b>Neutral sampling of 5 implants</b>	3 implants are ordered ex-factory + 2 implants of the same type are provided via mystery shopping from practices.
Step 2	<b>Unpacking and scanning under clean room conditions</b>	All 5 collected samples are carefully unboxed, mounted, and scanned in a clean room environment according to Class 100 US Fed. 209, Class 5 DIN EN ISO 14644-1.
Step 3	<b>Externally audited process of analysis</b>	SEM imaging and elemental analysis (EDS) are performed according to DIN EN ISO/IEC 17025 accreditation process (competence of testing and calibration laboratories) with external audits and multi-annual re-assessments.
Step 4	<b>Full-size and high-resolution SEM images</b>	A special full-size, high-resolution SEM image—digitally composed of more than 360 single SEM images in a magnification of 500x—always shows the implant surface from shoulder to apex.
Step 5	<b>Peer-review process</b>	Two members of the Scientific Advisory Board independently review the comprehensive report of analysis and sufficient clinical documentation or multi-annual PMCF studies (Post-Marketing Clinical Follow-up) of the analysed implant type showing survival rates of more than 95% for the device or device family.





© CleanImplant Foundation

SEM image SuperLine implant—Dentium.

Every quality award is valid only for two years and has to be renewed after this period. Currently, the following implant systems also carry the “Trusted Quality Seal”: Kontakt S (Biotech Dental), whiteSKY (bredent group), UnicCa (BTI Biotechnology Institute), (R)evolution and Patent/BioWin! (Champions-Implants), In-Kone (Global D), ICX-Premium (medentis medical), AnyRidge and BLUEDIAMOND (MegaGen), T6 (NucleOSS), Prama (Sweden & Martina), SDS 1.2 and SDS 2.2 (Swiss Dental Solutions). Other testing and analysis results are pending.

Moreover, CleanImplant “Certified Production Quality” awards were received by the CeramTec Group and Komet Custom Made as contract manufacturers of ceramic implants.

More and more dentists are supporting the CleanImplant Foundation. Certified as “CleanImplant Certified Dentists”, they pass on the trust they gained in the products to their patients and referring dentists.



#### Contact address

**CleanImplant Foundation**  
+49 30 200030190  
info@cleanimplant.org  
www.cleanimplant.org

## More information

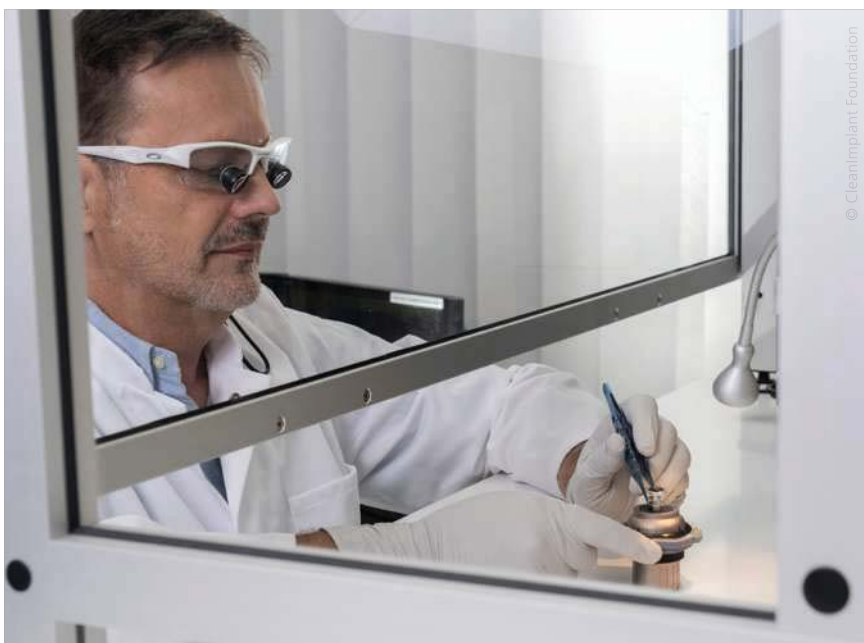[www.cleanimplant.org](http://www.cleanimplant.org)  
[www.facebook.com/cleanimplant](https://www.facebook.com/cleanimplant)  
[www.instagram.com/cleanimplant](https://www.instagram.com/cleanimplant)  
[www.linkedin.com/cleanimplant](https://www.linkedin.com/cleanimplant)

The independent **CleanImplant Foundation** was founded as a non-profit organisation in Berlin in 2016. In cooperation with renowned universities, the foundation regularly coordinates worldwide quality assessment studies of dental implants and awards the “Trusted Quality” seal to particularly clean implant types following a strict peer-review process to generate independent and meaningful data concerning the cleanliness/contamination of implant surfaces of sterile-packaged implants.

All samples are tested exclusively in specialised testing laboratories officially accredited according to DIN EN ISO/IEC 17025:2018.

CleanImplant also certifies implantologists as well as dental centers, thus increasing the confidence of referring clinicians, dentists and patients.

More information:  
[www.cleanimplant.org](http://www.cleanimplant.org)



Dr Dirk U. Duddeck placing an implant on the sample holder of the scanning electron microscope.

## New trends in oral implantology

# Whither ceramic implantology?

Over the past few decades, oral implantology has made more progress than almost any other dental discipline. Most questions regarding biological principles, treatment protocols, bone augmentation or implant materials and geometries have been scientifically investigated—and answered. The available systems have largely converged in terms of design and protocols, as Dr Jens Tartsch, President of the European Society for Ceramic Implantology (ESCI), confirms in this interview.

### ***Dr Tartsch, what are the current trends in oral implantology?***

It comes as no surprise that current trends tend to focus on specialisation, such as the digitalisation of workflows or the development of special implant geometries. These include innovations such as extensive screw threads for greater primary stability of immediately placed implants or trioval implant bodies, which are expected to provide additional benefits.

However, implantology congresses and specialist journals have focused much of their attention on another topic: ceramic implantology. Ceramic implants are currently the most important innovation in oral implantology, but unfortunately also still the most controversial one.

### ***How do you think ceramic implants and their success rates are currently viewed in the scientific and clinical community?***

In the past, ceramic implants were the domain of “holistic dentistry” and tended to be regarded as niche products. But this may no longer be the case today.

The survival rates of most modern zirconia implant systems are already on a par with those of titanium implants for the evidence-based indications of single-tooth restorations and three-unit bridges. Ceramic implants have thus become a serious factor in oral implantology. For one-piece ceramic implants, this has been confirmed by the S3 Guideline Conference of the DGI (2022): “[...] are valid and ready-to-use therapeutic procedures and can be used as an alternative treatment option.”



© Oleg - stock.adobe.com

For two-piece ceramic implants, the Scientific Advisory Board of the ESCI confirmed in its official statement (2021) that “the two-piece zirconia implant concept is appropriate for clinical application.” It also pointed out that “for clinical successes, each manufacturer’s guidelines regarding the strict application for the specified clinical indications should be followed for the respective two-piece zirconia implant.”

Ceramic implants are attracting growing interest and are increasingly finding their way into general implantological practice. Technological innovations and developments in materials, surface designs and treatment protocols now make it possible to successfully exploit the clinical advantages (such as improved aesthetics or reduced tendency to inflammation) in daily practice on a long-term basis.

***What are the current developments in ceramic implantology, and how do you assess its potential? And what challenges do you see for its successful application in the future?***

Unlike titanium-based implantology, the field of ceramic implantology still leaves much room for research, new innovations and trends. New materials, new computer-aided design and manufacturing (CAD/CAM) techniques, and special 3D printing processes are currently being developed to enable new implant geometries and implant-abutment connections. In addition, the use of new surgical instruments and guides as well as the use of advanced imaging techniques are targets of current research. The much-vaunted evidence base is also being strengthened, with early studies showing good ten-year results.

“

**Building on experience sound evidence, a lot is happening in ceramic implantology!**

”

A scientifically sound and evidence-based approach, together with in-depth knowledge of materials and procedures, is particularly important for successful application—and thus for the validation of this trend towards ceramic implants.

It should be noted that part of the available product range is still very heterogeneous and that the treatment protocols sometimes diverge from those for titanium implants.

To evaluate such background information, to generate and verify scientific facts, and to provide the appropriate training is the task of a scientific professional society, as represented by the ESCI as a Europe-wide network.




For the ESCI, the trend in implantology is absolutely clear: Modern ceramic implants, used correctly and for the proper indications, represent a highly innovative addition to the treatment armamentarium in oral implantology. Their importance will continue to grow in the future.

***Thank you very much, Dr Tartsch.***



Dr Jens Tartsch



**Contact address**

**Dr Jens Tartsch**

President, European Society for  
Ceramic Implantology (ESCI)

[www.esci-online.com](http://www.esci-online.com)

## OSSTEM IMPLANT Scientific Community

# Empowering dentists: comprehensive educational programmes in Europe

OSSTEM IMPLANT Scientific Community (OIC), the scientific community of OSSTEM IMPLANT, is committed to empowering dentists through its comprehensive educational programmes. With a wide range of offerings, including both offline and online courses, and academic symposiums, the OIC aims to strengthen the scientific community and facilitate dentists' access to advanced implant surgery techniques. The organisation's European body, the OIC Europe, provides dentists with the knowledge and skills necessary to excel in the field of dental implantology through its annual average of over 150 courses across Europe.

### Offline programme (OSSTEM OnSite):

One of the flagship programmes offered by the OIC Europe is OSSTEM OnSite, an offline course programme that operates throughout Europe. With an annual goal of 150 courses in 20 European countries this year, OSSTEM OnSite brings together experienced instructors and dental professionals to deliver hands-on training. Through these immersive courses, dentists gain practical experience in implant surgery, enhancing their clinical expertise and improving patient outcomes. Monthly course schedule is uploaded to the OIC Europe website, [www.oic-europe.eu](http://www.oic-europe.eu).

### Online programme (OSSTEM OnDemand):

Complementing its offline programme, the OIC Europe also provides OSSTEM OnDemand, which counts up to 49 on-demand webinars since May 2020. This platform covers a wide range of topics, from basic implant theory to advanced clinical methodology. With the flexibility of online learning, dentists can access these courses at their convenience, allowing for continuous professional development and expanding their knowledge base. OnDemand is uploaded to the OIC Europe website every third Tuesday of the month.

### Academic Symposiums:

With generous support from OSSTEM IMPLANT, the OIC Europe organises academic symposiums for knowledge sharing and networking annually. The highly anticipated Osstem-Hiossen Meeting in Europe (OHME) and the National OSSTEM Meeting are held in a yearly rotating basis. OHME serves as a platform for prominent European speakers to share their expertise and insights with the dental community. It not only provides a valuable learning experience but also fosters networking opportunities among dentists by bringing together experts and professionals, the OHME promotes the exchange of clinical knowledge and strengthens the scientific

community. The previous symposium took place in Rome, Italy from 28 to 29 October 2022 with 26 renowned speakers and over 700 dentists from 30 countries from Europe and the globe. The upcoming symposium will be in London, the United Kingdom from 22 to 23 November 2024.

In addition to the continental event, the OIC Europe also hosts the National OSSTEM Meeting catered specifically to the dental professionals within the region, providing them with localised educational content and networking opportunities. Through these national events, the OIC Europe ensures that dentists have access to tailored educational programmes that meet their specific needs and challenges.

## About ...

OSSTEM IMPLANT Scientific Community (OIC) is dedicated to providing optimised educational programmes to European dentists, allowing them to stay at the forefront of dental implantology. By offering a comprehensive range of courses, including offline and online programmes, the OIC Europe ensures that dentists can enhance their skills and knowledge. OHME and National OSSTEM Meeting provide invaluable opportunities for dentists to learn from experts, share clinical knowledge, and expand their professional networks. Through these initiatives, OSSTEM Implant and the OIC contributes to the growth and development of the dental community while easing dentists' access to advanced implant surgery techniques.

# INTERNATIONAL BLOOD CONCENTRATE DAY

**BIOLOGISATION IN  
REGENERATIVE DENTISTRY**

**14-15 SEPTEMBER 2023**

**RADISSON BLU HOTEL FRANKFURT AM MAIN**

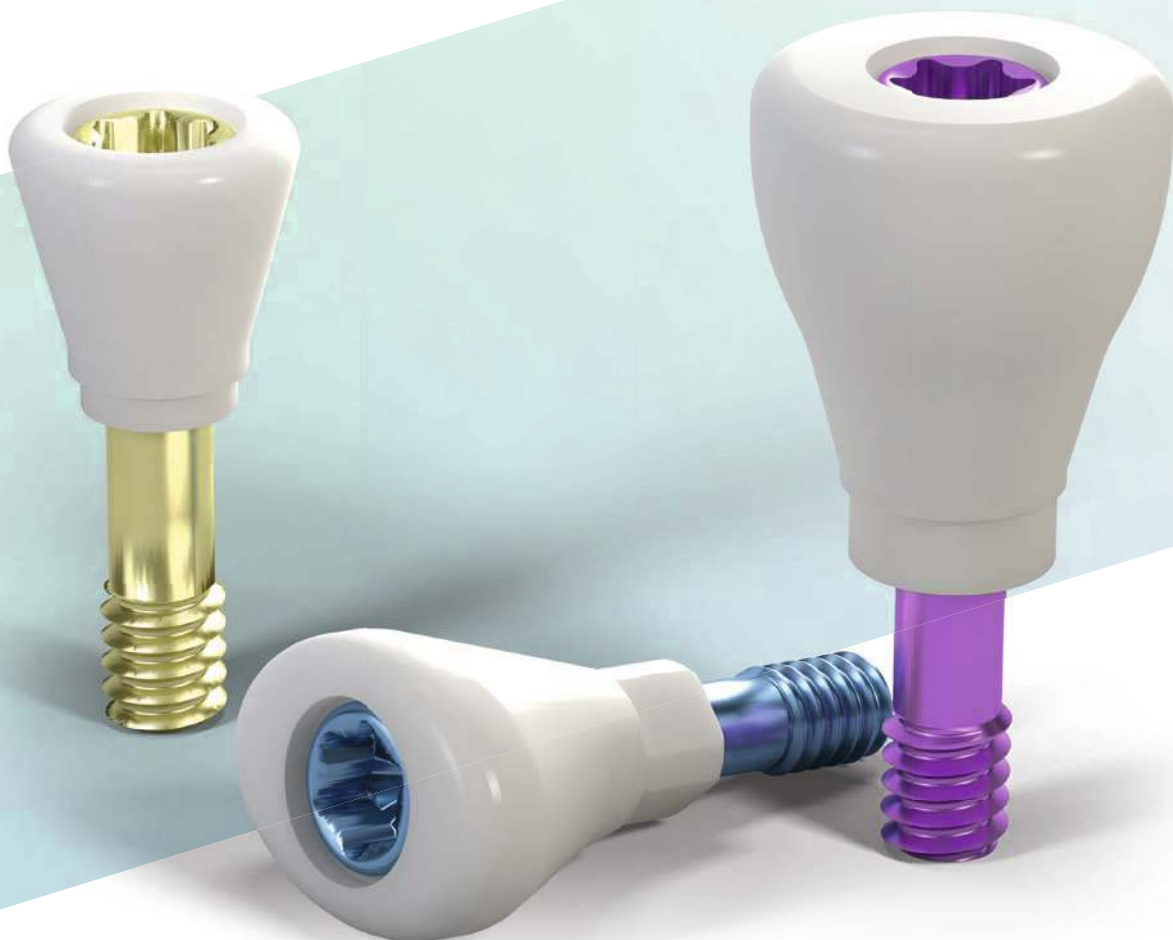**REGISTER  
NOW!**

[www.bc-day.info](http://www.bc-day.info)



Straumann

# Ceramic Healing Abutments: the first step to harmonious soft-tissue healing



These healing abutments for Straumann bone level implants enable aesthetics from the day of surgery and offer favourable conditions for soft-tissue attachment, thereby supporting a healthy peri-implant environment. Their well-proven zirconia material helps surgeons and prosthodontists who are looking for less plaque attachment (smoother surface compared to titanium) and they support soft-tissue healing from

the day of surgery. In general, more favourable soft-tissue attachment around zirconia than around titanium can be observed, with blood circulation similar to that around a natural tooth, as well as a more mature and pronounced soft-tissue integration. This comes with an ease of use entailing aspiration security thanks to the integrated screw and a colour-coding to clearly identify the corresponding prosthetic platform.



#### Contact address

Institut Straumann AG  
Switzerland  
[www.straumann.com](http://www.straumann.com)


Dentsply Sirona

# Introducing DS OmniTaper Implant System—the newest member of the EV Implant Family

The DS OmniTaper Implant System is an innovative solution that combines the proven technologies of Dentsply Sirona's EV Implant Family with new features that deliver efficiency and versatility. Unique to the implant system is an intuitive drilling protocol for reduced chair time and a pre-mounted TempBase for immediate restorations and efficient workflows.

The DS OmniTaper Implant System is the newest member of the EV Implant Family, alongside Astra Tech Implant System and DS PrimeTaper Implant System. The EV Implant Family offers surgical flexibility to cover virtually every indication. All three implant systems deliver biologically driven implant designs for natural aesthetics and lasting bone care, have one connection for restorative clarity, and are optimised for a seamless fit with digital dentistry workflows.

Like the rest of the EV Implant Family, the DS OmniTaper Implant System features the OsseoSpeed implant surface and the conical EV connection that provides access to the harmonised and comprehensive EV prosthetic portfolio for restorative flexibility and immediate chairside solutions.



#### Contact address

**Dentsply Sirona**  
Sweden  
+46 31 3763000  
[www.dentsplysirona.com](http://www.dentsplysirona.com)

AD

# Click & Meet

guaranteed COVID-free



**ZWP ONLINE**

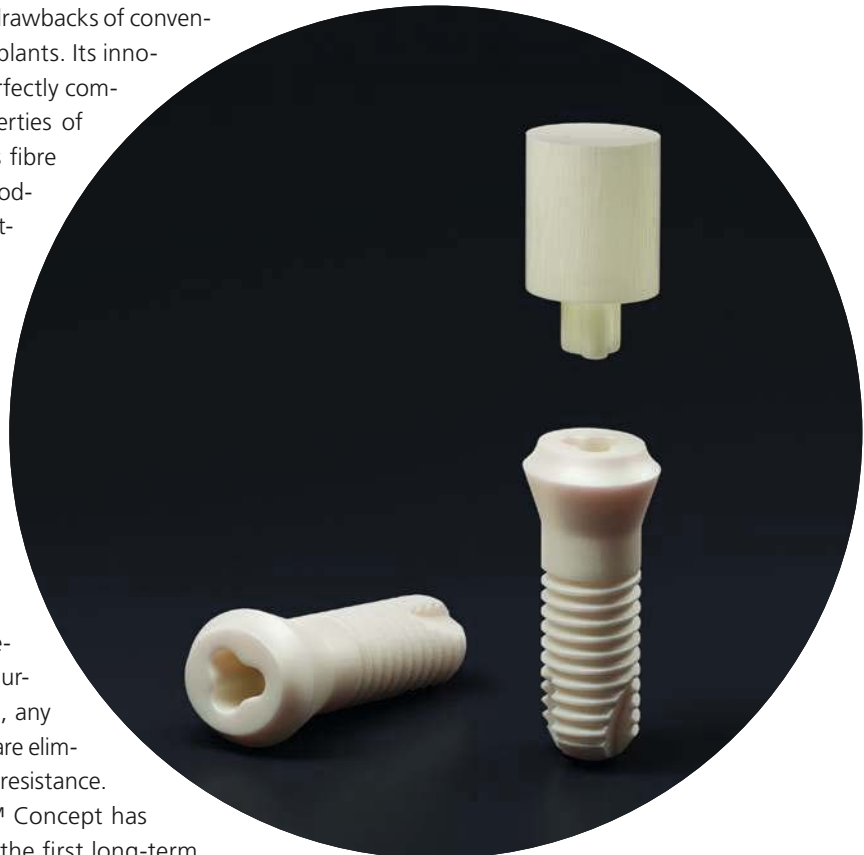[www.zwp-online.info](http://www.zwp-online.info)

© Oleksandra – stock.adobe.com

## Zircon Medical Management

# The two-piece zirconia implant with long-term studies

Patent™ has eliminated the drawbacks of conventional two-piece zirconia implants. Its innovative prosthetic concept perfectly complements the material properties of zirconia: the cemented glass fibre post, having a dentine-like modulus of elasticity, is able to attenuate masticatory forces and transfer them to the implant in favourable way, ensuring reliable long-term function. Additionally, the patented production process, in which all surface-machining steps are completed before sintering, creates a high endosteal surface roughness ( $R_a$  5,7  $\mu\text{m}$ ) that is essential for fast and predictable osseointegration. During the subsequent sintering, any process-induced microcracks are eliminated, maximising fracture resistance. The success of the Patent™ Concept has been proven by science: in the first long-term study on two-piece zirconia implants, integrated Patent™ Implants showed no fractures, healthy soft tissues, stable bone levels, and no signs of peri-implantitis after almost a decade.<sup>1</sup> In a preclinical study they demonstrated bone-to-implant contact (BIC) of over 70% after just four weeks of healing, outperforming all implants investigated in similar studies thus far in terms of osseointegration speed.<sup>2</sup>



### Contact address

Zircon Medical Management AG  
Switzerland  
[www.mypatent.com](http://www.mypatent.com)

#### Literature


- <sup>1</sup> Brunello G, Rauch N, Becker K, Hakimi AR, Schwarz F, Becker J. Two-piece zirconia implants in the posterior mandible and maxilla: A cohort study with a follow-up period of 9years. Clin Oral Implants Res. Dec 2022; 33(12):1233-1244. doi: 10.1111/clr.14005. Epub 31 Oct 2022. PMID: 36184914.
- <sup>2</sup> Glauser R, Schubach P. Early bone formation around immediately placed two-piece tissue-level zirconia implants with a modified surface: an experimental study in the miniature pig mandible. Int J Implant Dent. 14 Sep 2022; 8(1):37. doi: 10.1186/s40729-022-00437-z. PMID: 36103094; PMCID: PMC9474793.





# ZWP ONLINE

[www.zwp-online.info](http://www.zwp-online.info)



© kelly-sikkema - unsplash.com

**show some**   
leave a like.



[facebook.com/  
zwponline](https://facebook.com/zwponline)



[instagram.com/  
zwponline](https://instagram.com/zwponline)



[twitter.com/  
zwponline](https://twitter.com/zwponline)



	Event	Location	Date	Details/Registration
09/2023	Leipziger Forum für Innovative Zahnmedizin	Leipzig Germany	15–16 September 2023	<a href="https://oemus.com/events/bydomain/leipziger-forum.info">https://oemus.com/events/bydomain/leipziger-forum.info</a>
	37 <sup>th</sup> DGI-Kongress/30 <sup>th</sup> EAO Annual Scientific Meeting	Berlin Germany	28–30 September 2023	<a href="https://www.dgi-kongress.de/DGI/EAO">https://www.dgi-kongress.de/DGI/EAO</a>
10/2023	3 <sup>rd</sup> Joint Congress for Ceramic Implantology	Kreuzlingen Switzerland	13–14 October 2023	<a href="https://joint-congress.com/Swiss Biohealth Education">https://joint-congress.com/Swiss Biohealth Education</a>
	Fachdental Südwest	Stuttgart Germany	13–14 October 2023	<a href="https://www.messe-stuttgart.de/fachdental/Landesmesse Stuttgart GmbH">https://www.messe-stuttgart.de/fachdental/Landesmesse Stuttgart GmbH</a>

## EDI Journal – Information for authors

**EDI Journal** – the interdisciplinary journal for prosthetic dental implantology is aimed at dentists and technicians interested in prosthetics implantology. All contributions submitted should be focused on this aspect in content and form. Suggested contributions may include:

- Original scientific research
- Case studies
- Product studies
- Overviews

### Manuscript submission

Submissions should be made in digital form. Original articles will be considered for publication only on the condition that they have not been published elsewhere in part or in whole and are not simultaneously under consideration elsewhere.

### Manuscripts

Pages should be numbered consecutively, starting with the cover page. The cover page should include the title of the manuscript and the name and degree for all authors. Also included should be the full postal address, telephone number, and e-mail address of the contact author.

Manuscripts can be organised in a manner that best fits the specific goals of the article, but should always include an introductory section, the body of the article and a conclusion.

### Illustrations and tables

Each article should contain a minimum of 20 and a maximum of 50 pictures, except in unusual circumstances. Our publishing house attaches great importance to high quality illustrations. All illustrations should be numbered, have a caption and be mentioned in the text.

The photos should have a size of 10x15 cm, the image or graphic files must have a resolution of 300dpi. TIFF, EPS and JPG file formats are suitable. Radiographs, charts, graphs, and drawn figures are also accepted.

Captions should be brief one or two-line descriptions of each illustration, typed on a separate page following the references. Captions must be numbered in the same numerical order as the illustrations. Tables should be typed on a separate page and numbered consecutively, according to citation in the text. The title of the table and its caption must be on the same page as the table itself.

### References

Each article should contain a minimum of 10 and a maximum of 30 references, except in unusual circumstances. Citations in the body of the text should be made in numerical order. The reference list should be typed on a separate sheet and should provide complete bibliographical information in the format exemplified below:

[1] Albrektsson, T.: A multicenter report on osseointegrated oral implants. *J Prosthet Dent* 1988; 60, 75–82.

[2] Hildebrand, H. F., Veron, Chr., Martin, P.: Nickel, chromium, cobalt dental alloys and allergic reactions: an overview. *Biomaterials* 10, 545–548 (1989).

### Review process

Manuscripts will be reviewed by three members of the editorial board. Authors are not informed of the identity of the reviewers and reviewers are not provided with the identity of the author. The review cycle will be completed within 60 days. Publication is expected within nine months.

### Copyright

With acceptance of a manuscript, the publisher has the right to publish and translate the text, permit its reproduction, electronically store it in databases, produce reprints, photocopies and microcopies, and publish the text online. Any further utilisation or publication of the article is subject to prior approval by OEMUS MEDIA AG.

### Page charges and reprints

There are no page charges. The publisher will cover all costs of production. The journal will provide the primary author with a PDF file of the article and a free copy of the journal issue in which the article appears.

### Editors office

OEMUS MEDIA AG  
Holbeinstraße 29 · 04229 Leipzig · Germany  
Phone: +49 341 48474-224 · Fax: +49 341 48474-290  
s.thieme@oemus-media.de  
www.oemus.com



## MEMBERSHIP REGISTRATION FORM

I hereby apply for a membership in the BDIZ EDI  
(European Association of Dental Implantologists)

Name: .....

First Name: .....

Country: .....

Zip Code/City: .....

Street: .....

Phone: .....

Fax: .....

E-Mail: .....

Homepage: .....

Date of Birth: .....

Practicing implantology since: .....

Member of other Societies:

ICOI  BDO  DGI  DGZI  DGMKG  EAO

Continuing education Courses: .....

.....

Fellowship status / diplomate status in implantology

Yes  No  Organisation .....

Entry in BDIZ EDI Directory:  Yes  No

(For information on BDIZ EDI Directory of Implant Dentists see overleaf)

The annual membership fee for:

### FULL MEMBERSHIP

Full member – clinical EUR345.00

Assistant dentist / young professional  
(up to 5 years after graduation) EUR172.50

Second membership / family member EUR172.50

### EXTRAORDINARY MEMBERSHIP

Co-operative Member EUR165.00  
(Professionals without practice  
and dental technicians)

Students non-contributory

Supporting Membership EUR530.00  
(Companies etc.)

### Payment

Membership cannot be confirmed until payment is processed. Method of payment is by bank transfer. Please use the following banking account

Commerzbank Bonn

Account Number: 310 144 100  
Bank Code: 380 400 07  
IBAN: DE96 3804 0007 0310 1441 00  
BIC: COBADEFFXXX

Membership cards will be sent upon receipt of the annual subscription fee.

City/Date: .....

Seal/Signature: .....

Please return the completed registration form to:

European Association of Dental Implantologists e.V.

Lipowskystr. 12 · 81373 Munich · Germany


Phone: + 49 89 7206-9888, Fax: + 49 89 7206-9889

E-Mail: office@bdizedi.org, Homepage: www.bdizedi.org

BDIZ EDI • Lipowskystr. 12 • 81373 Munich, Germany • Phone: +49 89 7206-9888 • Fax: +49 89 7206-9889  
office@bdizedi.org • www.bdizedi.org

The commercial processing of your personal data on this form is based on the EU General Data Protection Regulation (GDPR – Regulation (EU) 2016/679 of 27 April 2016), Article 6 f GDPR by the European Association of Dental Implantologists (BDIZ EDI), Lipowskystr. 12, 81373 Munich/Germany.

You have the right to obtain information about personal data concerning you (Article 15 of the GDPR). You can also request the correction (rectification) of incorrect data (Article 16 of the GDPR). More information: Privacy Statement on www.bdizedi.org.



## Go further with DS OmniTaper™ implant system

Take your greatness to new heights. DS OmniTaper™ implant system is an intuitive, dependable and scalable solution, allowing you to go further and do more for your patients.

- Pre-mounted TempBase for immediate restorations and efficient workflows
- OsseoSpeed® surface for more bone, more rapidly
- Conical EV connection and harmonized prosthetics for streamlined efficiency

To learn more about the newest member of the EV Implant Family  
- visit [dentsplysirona.com/ds-omnitaper](https://dentsplysirona.com/ds-omnitaper) or talk to your representative.



Follow Dentsply Sirona for  
the latest in implant dentistry



[dentsplysirona.com/implants](https://dentsplysirona.com/implants)